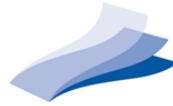

# EUROGUIDERM GUIDELINE LICHEN SCLEROSUS

Version [1], June 2023

**EUROPEAN  
CENTRE FOR  
GUIDELINES  
DEVELOPMENT**



**European  
Dermatology  
Forum**

**CHARITÉ  
d:EBM**

G Kirtschig<sup>1</sup>, M Kinberger<sup>2</sup>, A Kreuter<sup>3</sup>, R Simpson<sup>4</sup>, A Günthert<sup>5</sup>, C van Hees<sup>6</sup>, K Becker<sup>7</sup>, MJ Ramakers<sup>8</sup>, M Corazza<sup>9</sup>, S Müller<sup>10</sup>, S von Seitzberg<sup>11</sup>, MJ Boffa<sup>12</sup>, R Stein<sup>13</sup>, G Barbagli<sup>14</sup>, CC Chi<sup>15,16</sup>, JN Dauendorffer<sup>17</sup>, B Fischer<sup>18</sup>, M Gaskins<sup>2</sup>, E Hiltunen-Back<sup>19</sup>, A Höfner<sup>18</sup>, NH Köllmann<sup>18</sup>, H Kühn<sup>20</sup>, HK Larsen<sup>21</sup>, M Lazzeri<sup>22</sup>, W Mendling<sup>23</sup>, AF Nikkels<sup>24</sup>, M Promm<sup>25</sup>, KK Rall<sup>26</sup>, S Regauer<sup>27</sup>, M Sárdy<sup>28</sup>, N Sepp<sup>29</sup>, T Thune<sup>30</sup>, A Tsiogka<sup>31</sup>, S Vassileva<sup>32</sup>, L Voswinkel<sup>23</sup>, L Wölber<sup>33</sup>, RN Werner<sup>2</sup>

1 Medbase Health Centre, Frauenfeld, Switzerland.

2 Department of Dermatology, Venereology and Allergology, Division of Evidence- Based Medicine (dEBM), Charité - Universitätsmedizin Berlin, corporate member of Freie Universität Berlin and Humboldt-Universität zu Berlin, Berlin, Germany.

3 Department of Dermatology, Venereology, and Allergology, HELIOS St. Elisabeth Hospital Oberhausen, Oberhausen, Germany.

4 Centre of Evidence Based Dermatology, University of Nottingham, Nottingham, UK.

5 Department of Gynecology, Lucerne Cantonal Hospital, Lucerne, Switzerland.

6 Department of Dermatology, Erasmus University Medical Center, Rotterdam, the Netherlands.

7 Office for Paediatric surgery, Bonn, Germany.

8 CenSeRe (Centre for Psychological, Relational, Sexual Health), Voorschoten, the Netherlands

9 Section of Dermatology and Infectious Diseases, Department of Medical Sciences, University of Ferrara, Ferrara, Italy.

10 Department of Dermatology, University Hospital Basel, Basel, Switzerland.

11 The Danish Lichen Sclerosus Association, Denmark.

12 Department of Dermatology, Mater Dei Hospital, Msida, Malta.

13 Center for Pediatric, Adolescent and Reconstructive Urology, Medical Faculty Mannheim, University of Medical Center Mannheim, Heidelberg University, Mannheim, Germany.

14 Centro Chirurgico Toscano, Arezzo, Italy.

15 Department of Dermatology, Chang Gung Memorial Hospital, Linkou, Taoyuan, Taiwan.

- 16 College of Medicine, Chang Gung University, Taoyuan, Taiwan.
- 17 Department of Dermatology, Centre for genital and sexually transmitted diseases, University Hospital Saint Louis, Paris.
- 18 The Swiss Lichen Sclerosus Association, Switzerland / Verein Lichen Sclerosus e.V., Switzerland.
- 19 Department of Dermatovenereology, Helsinki University Hospital, Helsinki, Finland.
- 20 The German Lichen Sclerosus Association, Germany.
- 21 Department of Dermatology and Venereology, Copenhagen University Hospital, Bispebjerg Hospital, Copenhagen, Denmark.
- 22 Department of Urology, IRCCS Humanitas Research Hospital, Rozzano (MI), Italy.
- 23 German Center for Infections in Gynecology and Obstetrics, at Helios University Hospital Wuppertal–University Witten/Herdecke, Germany.
- 24 Department of Dermatology, University Medical Center of Liège, Liège, Belgium.
- 25 Department of Paediatric Urology and Clinic St. Hedwig, University Medical Centre of Regensburg, Regensburg, Germany.
- 26 Department of Women's Health, Women's University Hospital Tuebingen, Tuebingen, Germany.
- 27 Diagnostic and Research Institute of Pathology, Medical University Graz, Graz, Austria.
- 28 Department of Dermatology, Venereology and Dermatooncology, Semmelweis University, Budapest, Hungary.
- 29 Department of Dermatology and Venereology, Ordensklinikum Linz Elisabethinen, Linz, Austria.
- 30 Department of Dermatology, Haukeland University Hospital, Bergen, Norway.
- 31 National and Kapodistrian University of Athens, Faculty of Medicine, 1st Department of Dermatology-Venereology, Andreas Sygros Hospital, Athens, Greece.
- 32 Department of Dermatology and Venereology, University Hospital "Alexandrovska", Medical University - Sofia, Sofia, Bulgaria.
- 33 Department of Gynaecology, University Medical Centre Hamburg-Eppendorf and Centre for Colposcopy and Vulvovaginal disease Jersusalem Hospital Hamburg, Hamburg, Germany.

## Table of contents

I.	Notes on use/Disclaimer .....	5
II.	Accompanying documents: .....	5
III.	Funding .....	5
IV.	Scoping and defining the purpose of the guideline .....	5
V.	Population and health questions covered by the guideline .....	5
VI.	Targeted users of this guideline .....	6
VII.	Methods Section .....	6
VIII.	Main Recommendations .....	8
IX.	Guideline text and recommendations.....	11
1.	Introduction.....	11
1.1	Definition of disease.....	11
1.2	Histopathology .....	11
1.3	Genetic predisposition .....	14
1.4	Immunological findings .....	15
1.5	Associated diseases .....	16
2.	Epidemiology .....	18
2.1	Incidence / prevalence .....	18
2.2	Age at onset.....	18
2.3	Sex ratio.....	18
3.	Clinical presentation and sequelae of disease .....	19
4.	Trigger factors .....	24
5.	Diagnosis.....	27
6.	Differential diagnoses.....	28
7.	Introduction into treatment.....	29
7.1	Aims of treatment .....	29
7.2	Assessment of the treatment success.....	29
8.	Treatment.....	31
8.1	Skin care and basic therapy.....	31
8.2	Topical treatment.....	35
8.2.1	Emollients.....	35
8.2.2	Topical and intralesional corticosteroids .....	37
8.2.3	Topical calcineurin inhibitors .....	43

8.2.4	Topical retinoids .....	47
8.2.5	Topical hormone preparations .....	50
8.3	Platelet rich plasma .....	53
8.4	UV therapy.....	56
8.5	Photodynamic therapy .....	59
8.6	Laser therapy.....	61
8.7	Cryotherapy.....	65
8.8	Systemic treatment .....	66
8.9	Surgical interventions.....	70
9.	Features of extragenital lichen sclerosus .....	79
10.	Lichen sclerosus in pregnancy .....	80
11.	Pain in lichen sclerosus.....	83
12.	Follow-up.....	86
13.	Patient Education Programs .....	89
14.	Interdisciplinary management .....	94
15.	Improvement of care.....	96
16.	Future research .....	98
17.	Upcoming treatments .....	101
X.	Strengths and limitations .....	103
XI.	Acknowledgements .....	103
XI	References.....	104

## I. Notes on use/Disclaimer

The EuroGuiDerm *guideline on lichen sclerosus* was developed in accordance with the EuroGuiDerm Methods Manual v1.3, which can be found on the website of the European Dermatology Forum (EDF), subsection EuroGuiDerm/EDF Guidelines. <https://www.edf.one/de/home/Guidelines/EDF-EuroGuiDerm.html>.

This work is licensed under the [Creative Commons Attribution-NonCommercial-ShareAlike 4.0](https://creativecommons.org/licenses/by-nc-sa/4.0/). For further information on copyright in case of translation, adaptation, commercial use etcetera, see EDF website. Copyright © European Dermatology Forum.

## II. Accompanying documents:

The Methods report and the Evidence report are available alongside the guideline document on the EDF website: <https://www.edf.one/de/home/Guidelines/EDF-EuroGuiDerm.html>

## III. Funding

The development of this EuroGuiDerm guideline was funded through the EuroGuiDerm Centre for Guideline Development. The European Dermatology Forum (EDF) is responsible for fundraising and holds all raised funds in one account. The EuroGuiDerm Team is not involved in fundraising or in the decision making on which GL/CS development is funded. The decisions on which GL/CS is funded are made by the EuroGuiDerm Board of Directors independently. The EDF or any other body supporting guideline work is never involved in the development of this guideline and had no say on its content or focus.

## IV. Scoping and defining the purpose of the guideline

The aim of this guideline is to provide guidance on the diagnosis, management and treatment of patients with genital and extragenital lichen sclerosus (LS) of all age groups. According to the scoping document, the objectives of the guideline are:

- To provide guidance on the diagnostic of LS
- To highlight important aspects in the care of LS patients
- To generate recommendations and treatment algorithms on topical, interventional and surgical therapy , based on the latest evidence
- To provide guidance in the management of LS patients during pregnancy
- To provide guidance for the follow-up of patients with LS
- Inform about new developments and potential research aspects

## V. Population and health questions covered by the guideline

The target population are patients with genital or extra genital LS of all ages. Leading health questions (regardless of sex, ethnicity or gender) regarding LS are:

- What is the optimal diagnostic algorithm?
- What is the optimal treatment with regard to patients' needs, taking efficacy, safety/tolerability of different treatment options into consideration?

- How should the selected treatment option(s) best be managed and monitored?
- What should the follow-up of patients with LS be like and what should it include?

## VI. Targeted users of this guideline

This guideline has been prepared for physicians, especially dermatologists, gynaecologists, urologists, paediatricians, surgeons, proctologists, general practitioners and other specialists taking care of patients suffering from LS.

## VII. Methods Section

The EuroGuiDerm *guideline on lichen sclerosus* was developed in accordance with the EuroGuiDerm Methods Manual v1.3. For the detailed description of the guideline development process as well as an overview of the evidence referred to here, please see

*EUROGUIDERM GUIDELINE lichen sclerosus – METHODS REPORT*

This report is available alongside the guideline document on the EDF website:

<https://www.edf.one/de/home/Guidelines/EDF-EuroGuiDerm.html>

### **Nomination of experts, management of conflicts of interest**

The *guideline* development group is comprised of 34 experts from 17 countries, including 5 patient representatives nominated by EuroGuiDerm national partner societies or the guideline coordinator (GK). All nominations were reviewed and confirmed by the EuroGuiDerm Board of Directors. *None* of the experts declared personal-financial conflicts of interests.

### **Systematic review of the evidence**

A detailed description of the systematic literature review which was conducted to inform the evidence-based treatment recommendations is given in the methods report. The systematic review was a collaborative effort between EuroGuiDerm and the British Association of Dermatologists (BAD). We would like to gratefully acknowledge the BAD for sharing their systematic review including their detailed data extraction and analysis which served as base for our updated version of the systematic assessment of the evidence.

### **Development of the guideline and the consensus process**


The chapters of the guideline and the recommendations were developed by the group members, who formed a number of working groups. Each chapter and all recommendations were reviewed, discussed and amended where appropriate by the entire group. All texts and recommendations were voted on with a necessary minimal agreement of >50% during the consensus conferences. RNW facilitated all three consensus conferences using a structured consensus technique. Both internal and external reviews were conducted. Dissemination and implementation plans were developed. For more details, see Methods Report.

The wording of the recommendations was standardised (as suggested by the GRADE Working Group<sup>2</sup>).

*Wording of recommendations*

Strength	Wording	Symbols	Implications
<b>Strong</b> recommendation <b>for</b> the use of an intervention	'We recommend ...'	↑↑	We believe that all or almost all informed people would make that choice.
<b>Weak</b> recommendation <b>for</b> the use of an intervention	'We suggest ...'	↑	We believe that most informed people would make that choice, but a substantial number would not.
<b>No recommendation</b> with respect to an intervention	'We cannot make a recommendation with respect to ...'	0	At the moment, a recommendation in favour or against an intervention cannot be made due to certain reasons (e.g. no reliable evidence data available, conflicting data or conflicting outcomes, etc.)
<b>Weak</b> recommendation <b>against</b> the use of an intervention	'We suggest against . ..'	↓	We believe that most informed people would make a choice against that intervention, but a substantial number would not.
<b>Strong</b> recommendation <b>against</b> the use of an intervention	'We recommend against ...'	↓↓	We believe that all or almost all informed people would make a choice against that intervention.

The recommendations are presented throughout this guideline as displayed below: alongside the wording of the recommendations the arrow(s) and colours indicate the direction and the strength of each recommendation. The rate of agreement (consensus strength) is also displayed as the actual percentage and in form of a category-type pie-chart.

We <b>recommend</b> ultrapotent or potent topical corticosteroids in women with genital lichen sclerosus.	↑↑	 <p>&gt;75%</p> <p>(16/17)<sup>1</sup></p> <p>Evidence- and consensus-based</p>
We <b>recommend</b> ultrapotent or potent topical corticosteroids in girls with genital lichen sclerosus.	↑↑	
We <b>recommend</b> ultrapotent or potent topical corticosteroids in men with genital lichen sclerosus.	↑↑	
We <b>recommend</b> ultrapotent or potent topical corticosteroids in boys with genital lichen sclerosus.	↑↑	
We <b>suggest</b> ultrapotent or potent topical corticosteroids in patients with extra genital lichen sclerosus.	↑	

<sup>1</sup> Abstention

## VIII. Main Recommendations

For Lichen sclerosus of the vulva (ICD11 EB60.0), the penis (EB60.1) and extragenital (EB60.Y)

### Initiation and selection of a systemic treatment

National societies are invited to consult their own national treatment recommendations in line with local regulations and availability. The EuroGuiDerm *lichen sclerosus guideline* group suggests the following recommendations as a base for national adoption/adaption:

#### Women

We <b>recommend</b> co-treatment with emollients during standard therapy in women with genital lichen sclerosus.	↑↑
We <b>recommend</b> ultrapotent or potent topical corticosteroids in women with genital lichen sclerosus.	↑↑
We <b>suggest</b> intralesional corticosteroids to hyperkeratotic lesions in women with topical steroid-resistant genital lichen sclerosus (provided malignancy has been excluded).	↑
We <b>suggest</b> topical calcineurin inhibitors in women with genital lichen sclerosus as second choice or as an additional treatment if topical corticosteroids are contraindicated or insufficient. (off label)	↑
We <b>suggest</b> UVA-1 therapy in women with genital lichen sclerosus as a second choice treatment, taking into account carcinogenicity and practicality.	↑
We <b>suggest</b> acitretin, taking into account teratogenicity, if systemic therapy is needed in women with genital lichen sclerosus. (off label)	↑
We <b>suggest</b> de-adhesion / synechiolysis / perineoplasty in women with lichen sclerosus who have a persistent introital stenosis that causes mechanical problems in voiding or sexual intercourse, despite guideline-conform treatment with topical steroids.	↑

#### Girls

We <b>recommend</b> co-treatment with emollients in girls with genital lichen sclerosus.	↑↑
We <b>recommend</b> ultrapotent or potent topical corticosteroids in girls with genital lichen sclerosus.	↑↑



We **suggest** topical calcineurin inhibitors in girls with genital lichen sclerosus as second choice or as an additional treatment if topical corticosteroids are contraindicated or insufficient. (off label)

↑

**Men**

We **suggest** co-treatment with emollients in men with genital lichen sclerosus.

↑

We **recommend** ultrapotent or potent topical corticosteroids in men with genital lichen sclerosus.

↑↑

We **suggest** topical calcineurin inhibitors in men with genital lichen sclerosus as second choice or as an additional treatment if topical corticosteroids are contraindicated or insufficient. (off label)

↑

We **suggest** acitretin if systemic therapy is needed in men with genital lichen sclerosus. (off label)

↑

We **suggest** circumcision, preferably removing the complete foreskin, if guideline-conform treatment with e.g. steroids in men with phimosis caused by lichen sclerosus fails.

↑

We **suggest** frenuloplasty in combination with intralesional triamcinolone or alternatively, a complete circumcision if guideline-conform treatment with e.g. steroids in men with scarring or shortening of the frenulum caused by lichen sclerosus fails.

↑

We **suggest** urethroplasty using oral mucosa grafts in men with urethral stricture due to lichen sclerosus causing mechanical problems in voiding or sexual intercourse.

↑

**Boys**

We **suggest** co-treatment with emollients in boys with genital lichen sclerosus.

↑

We **recommend** ultrapotent or potent topical corticosteroids in boys with genital lichen sclerosus.

↑↑

We **suggest** topical calcineurin inhibitors in boys with genital lichen sclerosus as second choice or as an additional treatment if topical corticosteroids are contraindicated or insufficient. (off label)

↑

We **suggest** frenuloplasty in combination with intralesional triamcinolone, or alternatively, a complete circumcision if guideline-conform treatment with e.g. steroids fails in boys with scarring or shortening of the frenulum caused by lichen sclerosus.

↑

### Extragenital lichen sclerosus

We **suggest** co-treatment with emollients in patients with extragenital lichen sclerosus.

↑

We **suggest** ultrapotent or potent topical corticosteroids in patients with extragenital lichen sclerosus.

↑

We **recommend** UV therapy in patients with extragenital lichen sclerosus.

↑↑

We **suggest** methotrexate, taking into account teratogenicity if systemic treatment is needed in adult patients with genital and/or extragenital lichen sclerosus. (off label)

↑

## **IX. Guideline text and recommendations**

### **1. Introduction**

#### **1.1 Definition of disease**

Lichen sclerosus (LS) is an inflammatory skin disease that typically involves the anogenital site where it causes itching and soreness; it may lead to sexual and urinary dysfunction in women and men, however it may be asymptomatic. First signs of LS are usually a whitening of the genital skin, sometimes redness and oedema, fissuring, scarring, shrinkage, and fusion of structures may follow in its course; it is associated with an increased risk of genital cancer. Extragenital disease occurs in a minority of patients. The course of LS is usually chronic. Treatment remains unsatisfactory, particularly in women as disabling scar formation is common despite treatment.<sup>3-6</sup> There is some evidence that LS in males may go into remission after circumcision, however, good studies are lacking.

Synonyms like kraurosis vulvae, balanitis xerotica obliterans, and white spot disease are old terms and should no longer be used. The suffix 'et atrophicus' has been dropped because it is recognized that some cases of LS are associated with a hypertrophic, rather than atrophic, epithelium.

LS has a huge impact on the quality of life of affected patients and it is important to raise more awareness of this not uncommon disease in order to diagnose and treat it early.<sup>7,8,9</sup> This guideline aims to highlight potential triggers for LS, offer advice on current treatment options, and to suggest future research strategies.

#### **1.2 Histopathology**

A biopsy to confirm the clinical diagnosis is not considered necessary in all instances, particularly if the clinical picture is diagnostic, however, a biopsy at baseline may be helpful.

A biopsy is certainly indicated if there is doubt about the clinical diagnosis, if there is no response to treatment or if a malignancy or pre-malignancy is suspected. In children a vulval or penile biopsy is not usually performed, because it may be very traumatic for the child and there is no risk of dysplasia or cancer in prepubertal children. It should be reserved for cases with an uncertain diagnosis and for those who fail to respond to treatments.<sup>10</sup> Biopsies in the genital area in particular in children should be performed by a physician with expertise.

A biopsy should be taken from a typical lesion, this is usually an area of whitish appearance (hyperkeratosis, "pallor" or sclerosis). If this cannot be found, e.g. if fissures or erosions are the complaint, a biopsy may be taken at the end of a fissure, often appearing in the interlabial sulcus, or at the edge of an erosion (not from the middle of an erosive lesions), or e.g. at the posterior end of the labia minora if they appear shortened which indicates disease activity.

If no baseline biopsy was taken before treatment, a 3-week pause of treatment is requested for a reliable histological diagnosis. If this cannot be tolerated by the patient, it is essential to inform the pathologist about the type of treatment. Depending on the length and type of treatment, histological features may be altered.

**Typical histological features of an established LS lesion are (Figure 1)**

- compact orthohyperkeratosis,
- epidermal atrophy,
- basal cell degeneration,
- dermal hyalinisation, and
- an interphase dermatitis with a band-like lymphocytic infiltrate, typically underneath the hyalinised, oedematous dermis,<sup>11</sup>
- follicular plugging in hair bearing skin

**Corticosteroid treatment** may induce a remission of the hyperkeratosis and a previously existing mild subepithelial sclerosis. It will especially lead to a reduction of the lymphocytic infiltrate, and will therefore alter all features that result from inflammation such as an interphase dermatitis, basement membrane destruction and keratinocyte damage. **Anti-fungal treatment**, which is often administered in patients with LS because of a mistakenly diagnosed candida infection, may induce a hypersensitivity reaction leading to a psoriasiform reaction pattern of the skin. In such situations also **eczema / dermatitis (atopic or seborrheic)**, in particular if early LS is suspected, must be considered.

Genital LS is sometimes difficult to distinguish from **genital mucosal / erosive lichen planus (LP)**. However, LP has several pathognomonic clinical and histological features that usually allow a distinction from LS:

- involvement of glycogenated mucosal tissue (oral, oesophageal, vaginal, vestibular vulval mucosa),
- the histological correlate of Wickham striae, pathognomonic for LP, is a focal and circumscribed accentuation of the granular cell layer, often referred to as wedge shaped hypergranulosis and focal compact hyperkeratosis,
- keratinocyte apoptosis, not seen in LS,
- circumscribed, scarring alopecia in scalp involvement,
- typical nail changes (see text books).

25 years ago Fung & LeBoit already made an attempt to establish the histological differences between LS and LP, consensus is still not achieved-(Table 1).

Table 1: Summary of histological differences between LS and LP established by Fung & LeBoit in 1998<sup>12</sup>

	LS % with stated feature	LP % with stated feature
Psoriasiform lichenoid pattern	100	0
Basilar epidermotropism	78	0
Loss of papillary dermal elastic fibres	100	33
Basement membrane thickening	44	0
Epidermal atrophy	33	0
Many cytoid bodies	0	100
Wedge-shaped hypergranulosis	11	100
Basal squamatization	25	100
Pointed rete ridges	11	83

Day et al. suggest the following clinicopathologic diagnosis of genital mucosal / erosive LP incorporating 5 criteria: (a) a well-demarcated, glazed red macule or patch at labia minora, vestibule, and/or vagina, (b) disease affects hairless skin, mucocutaneous junction, and/or non-keratinized squamous epithelium, (c) evidence of basal layer damage, categorized as degenerative or regenerative, (d) a closely applied band-like lymphocytic infiltrate, and (e) absent subepithelial sclerosis.<sup>13</sup>

However, it has to be noticed that there is a spectrum of histological and clinical features in LS and in early disease some features seen in established disease are missing. In **early LS** (Figure 1a&b, Figure 3c), some classical features like the hyalinisation of the upper dermis may be lacking and a firm histological diagnosis cannot be made. Attili & Attili made an attempt to establish the various features of early and late LS (Table 2).<sup>14</sup> However, this needs to be confirmed and consented. In any case, histological and clinical features have to be correlated and sometimes only time will show how the disease will develop before a firm diagnosis can be made.

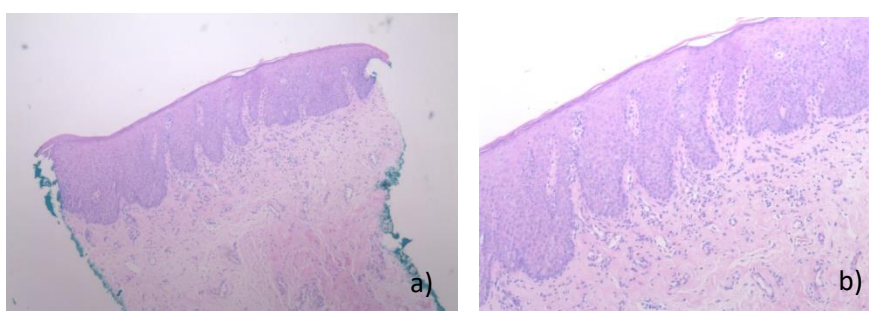
	Early pre-sclerotic phase		Sclerotic phase Conventional lichen sclerosus		Atrophic phase
	Stage 1a (17%)	Stage 1b (27%)	Stage 2a (44%)	Stage 2b (4%)	Stage 3 (8%)
Epidermis	Psoriasiform	Widening of papillae and loss of rete ridge pattern	Thin and flat epidermis	Pseudo-epithelial hyperplasia	Thin and atrophic
Basement zone	Vacuolar/lichenoid interface dermatitis with an indistinct basement membrane	Diffuse dermal lymphocytic infiltrate with thickened or multi stranded basement membrane	Thickened basement membrane merging with hyalinised papillary dermis. Focal basilar lymphocytic infiltration	Diffuse vacuolar change with basilar infiltration of lymphocytes	Thin basement membrane. No inflammatory cells
Papillary dermis	Normal	Patchy peri vascular lymphocytic infiltrates. New capillaries with thicker walls	Loss of normal structure with hyalinisation and sclerosis	Loss of normal structure with hyalinisation and sclerosis.	Normal structure replaced by loose matrix of fibrosis. Negligible inflammatory cells
Reticular dermis	Normal	Normal	Mid-dermal band of lymphocytic infiltrate along with thick walled and dilated blood vessels	Structural loss with hyalinisation and sclerosis.	Loose matrix of fibrosis. Negligible inflammatory cells

Table 2: Histological stages of genital lichen sclerosus (133 cases).<sup>14</sup>

Also, **hypertrophic forms of genital LS** and LP may show similar clinical and histological features making a distinction difficult in some cases. Of particular importance is to rule out precancerous or cancerous lesions. Squamous cell cancers (SCC) in LS develop independent of human papilloma virus (HPV) infection. While HPV induced SCC develop slowly over several years, HPV independent SCC can develop rapidly within several

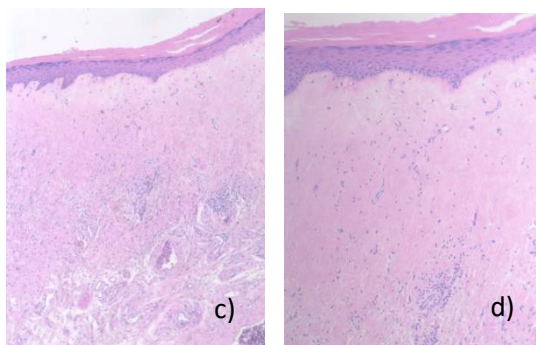
months.<sup>15</sup> Therefore, any new hyperkeratotic lesion or newly arising erosions and ulcerations are suspicious for a HPV-independent vulval intraepithelial neoplasia, also referred to as differentiated vulval intraepithelial neoplasia and should be biopsied

In conclusion, greater awareness of the clinicopathological spectrum of LS should enable early diagnosis and treatment. A biopsy read by an experienced (dermato)histopathologist is particularly helpful to rule out clinical differential diagnoses such as LP and eczema, atopic or seborrheic, in particular if early LS is suspected, and detect precancerous and cancerous lesions.



We thank Luis Mario Orantes-Aguirre, Unilabs Bern, Switzerland for the provision of the histological pictures.

**Figure 1:** Histopathology of early LS in **a) & b)** (see corresponding clinical Figure 3c), the biopsy was taken from the right interlabial sulcus):



Epidermal acanthosis with some hyperkeratosis, rete ridges are broadened. The upper dermis contains a lichenoid lymphocytic infiltrate and is a bit oedematous. Blood vessels are slightly dilated in the upper plexus.

Late LS in **c) & d)** shows an atrophic epidermis, with orthohyperkeratosis, rete ridges are partly elapsed, there is a broad subepidermal oedema and swollen and homogenised collagen fibres. Blood and lymphocytic vessels are dilated. The lichenoid lymphocytic infiltrate is pushed by the oedema to middermis.

### 1.3 Genetic predisposition

A genetic predisposition is implicated. A positive family history of LS is observed between 5.4% and 12% of patients with genital LS in British, Italian and Dutch studies.<sup>16-20</sup> Familial occurrence is probably higher than expected and may be as high as 39%.<sup>17,21</sup>

**HLA** Immunogenetic studies have demonstrated a significant association with particular HLA class II antigens in patients compared with controls.<sup>22-25</sup> The existence of a susceptibility gene for sclerosis in this region of the MHC is underlined by the finding that the same region is associated with an increased risk of autoimmune diseases in women.<sup>26</sup>

LS is described to occur in individuals with Turner syndrome (X0 chromosome) and with a Fitzpatrick phototype 1 and 2 in boys.<sup>27</sup> The association of Turner syndrome and LS leads to speculations of the influence of low oestrogen; Turner Syndrome is also associated with an increased risk of immune mediated inflammatory disease, such as autoimmune thyroiditis, coeliac disease, type 1 diabetes mellitus, inflammatory bowel disease,

alopecia areata, or vitiligo. The presence of isochromosome iXq and exposure to oestradiol may contribute to the development of the autoimmune process.<sup>28-30</sup>

**Gene expression** pattern of LS in males using DNA microarray functional analysis revealed increased expression in adults and children in the immune response/cellular defence gene ontology (GO) category and reduced expression in other categories including genes related to squamous cancer. No specific HPV, autoimmune or squamous carcinogenesis-associated gene expression patterns were found. ECM1 and CABLES1 expression were significantly reduced in paediatric and adult samples respectively; the meaning of this needs further evaluation.<sup>31</sup>

In contrast, the median mRNA as well as mean protein expression of ECM proteins (e.g. proteoglycans, ECM-1) and connective tissue growth factor (CTGF) was found to be higher in vulval LS in the study by Gambichler et al. TGF- $\beta$ /Smad-3 independent up-regulation of CTGF may induce accumulation of ECM proteins and maintain fibrosis in chronic vulval LS.<sup>32</sup>

**Epigenetics** refers to functionally relevant changes in the genome other than those of DNA sequence that can lead to changes in gene expression or cellular phenotype. Vulval LS is associated with altered expression of IDH enzymes and aberrant hydroxymethylation indicating an epigenetic background for the pathogenesis of vulval LS.<sup>33</sup> Hypermethylation of the promoters of genes like IRF6 and RAR  $\beta$ , with their subsequent down-expression, seems to play a role in VLS progression towards cancer.<sup>34,35</sup> The involvement of an aberrant methylation of the promoters of these and other genes in the pathogenesis of vulval LS is less evident.

## 1.4 Immunological findings

**T-cells** Terlou et al. describe an autoimmune phenotype in vulval LS, characterized by increased levels of Th1-specific cytokines, a dense T-cell infiltrate, and enhanced BIC/miR-155 expression, a microRNA involved in regulation of the immune response.<sup>36</sup>

Pilatz et al. investigated the cellular composition, inflammatory infiltrate and microenvironment in boys with congenital phimosis and lichen sclerosus. They found distinct expression patterns of tissue remodelling associated genes characterized by over expression of bone morphogenetic protein 2 and its corresponding receptor, matrix metalloproteinases 1 and 9 and tissue inhibitor of metalloproteinases 1, cytokine chemokine ligands 5 (RANTES) and interleukin 4, and TGF- $\beta$ 2 and its corresponding receptor.<sup>37</sup>

Kaya et al. described that CD44-targeted deficiency in mouse epidermis results in a LS-like histological picture.<sup>38</sup> In human genital and extragenital LS lesions, the epidermal expression of CD44 is decreased or absent, both at the protein and mRNA levels, which is correlated with an accumulation of hyaluronate in the superficial dermis. This suggests that LS might result from an epidermal damage of unknown origin, responsible for a progressive decrease in keratinocyte CD44, subsequently leading to dermal changes in which HA accumulation is a conspicuous feature.<sup>39</sup> However, increased epidermal and dermal staining in areas where there was a band of inflammatory cells but decreased in areas of sclerotic skin using a pan CD44 marker was observed by Farrell et al.<sup>40</sup>

Tchorzewski et al. describe that the involution of lichen sclerosus-affected tissues may be the suppressive effect



exerted by CD4+CD25+ suppressor T lymphocytes, the increase in IL-10 inhibitory cytokine production, and diminished granulocyte ROI production. Inflammatory infiltrates in the affected regions of the skin are characterized by a diminished number of CD3 lymphocytes bearing the CD26 molecule, which may be responsible for an autocrine defect in bioactive mediator degradation.<sup>41</sup>

The dysregulation of certain mediators, like Dkk-1, GDF-15 IGFBP-2, CHI3L1, involved in both inflammatory processes and collagen metabolism in keratinocytes and fibroblasts obtained from vulval LS samples have been identified by Corazza et al. Both keratinocytes and fibroblasts seem to actively participate in this process, with peculiar and in some way different profiles of mediators' release.<sup>42,43</sup>

### **Humoral autoimmunity**

An increased incidence of autoantibodies to the extracellular matrix protein 1 (ECM1) and autoantibodies to BP180 antigen in LS are reported. This may support the idea of LS being a (humoral) autoimmune disease<sup>44-47</sup>, however, it may be a secondary phenomenon.

Interestingly, the clinicopathological phenotype of lipoid proteinosis, which results from mutations in ECM1, resembles LS.<sup>44</sup> However, the pathogenic relevance of these findings needs further investigation.

A significant interferon-gamma production was observed in response to the NC16A peptides in 6 of the 14 vulval LS patients, but not in the control subjects. There was an associated autoantibody response to BP180 in 3 LS patients with T-cell responses. These data suggest that in some vulval LS patients, NC16A domain-specific T cells circulate at sufficiently high frequency to be detectable in vitro and show rapid effector function.<sup>48</sup>

However, no increased percentage of anti-BP180 autoantibodies in LS were detected in a cohort from Greece. Authors suggest that autoantibodies in patients with genital LS represent rather an epiphenomenon than a true component of LS pathogenesis.<sup>49</sup>

**Oxidative stress**, which is involved in the pathogenesis of several autoimmune and malignant disorders, may contribute to these processes in LS.<sup>50</sup> Increase of lipid peroxidation products was found within the basal cell layers of the epidermis of LS, thus co-localizing with ECM1. Oxidative DNA damage was detected throughout LS biopsies indicating that oxidative damage to lipids, DNA and proteins may contribute to sclerosis, autoimmunity and carcinogenesis in LS. The possible role of TP53 mutations in the development of vulval cancer in LS is postulated.

## **1.5 Associated diseases**

Immune mediated inflammatory diseases like thyroid disease (most common), vitiligo, alopecia areata, autoimmune bowel disease, rheumatoid arthritis, primary biliary cirrhosis, pernicious anaemia, localized scleroderma/morphoea, systemic lupus erythematosus, frontal fibrosing alopecia,<sup>51</sup> and multiple sclerosis are more frequently described in genital LS patients. These associations are more common in females (19% to 54%) than in males (3% to 5%).<sup>22,24,52-62</sup>



The prevalence of psoriasis (Th1 response) in vulval LS patients was found to be higher than in the general population and among non-LS patients.<sup>63,64</sup>

**Atopic dermatitis** (Th2 response) was found more commonly in boys with LS compared to circumcised boys without LS.<sup>65,66</sup> In male patients LS is associated with an increased body mass index and has been associated with coronary artery disease, diabetes mellitus and tobacco use.<sup>67,68</sup>

**Diabetes mellitus** and LS is more frequently reported than expected, some recommend DM screening in LS.<sup>19,69</sup>

Women with LS may have other bladder, bowel and pain comorbidities. In a series of 308 women with LS seen at a vulval clinic, self-reported conditions were overactive bladder (15.3%), stress urinary incontinence (27.9%), constipation (32.5%), irritable bowel syndrome (19.5%), thyroid dysfunction (33.1%) (2 to 3-fold increased risk)<sup>70</sup>, fibromyalgia (9.1%), temporomandibular joint disorder (13.0%) and vulval pain (83.1%).<sup>71</sup> A multicentre Italian study evidenced that metabolic factors (obesity, hypertension, hypothyroidism and a sedentary lifestyle) may play a role in genital LS pathogenesis in genetically predisposed patients, and that risk profile is similar in males and females.<sup>20,68</sup>

Hu et al. compared the demographics and self-reported medical comorbidities of patients with vulval LS (n= 865) with those of women with other vulval conditions (n= 1118). Increasing age, thyroid disease, and anorectal fissures were significantly associated with vulval LS. The association between anorectal fissures and vulval LS likely represents a sequela of the disease rather than a true comorbidity.<sup>60</sup>

The association of genital melanoma and LS is described in several case series, mainly in women.<sup>72</sup> Vulval melanoma is rare, with an incidence of 0.10–0.13 per 100,000 individuals, presenting typically in post-menopausal women. There seems to be an increased incidence of vulval melanoma among patients with LS, also in girls!<sup>73</sup> The increased risk of vulval melanoma and SCC should be noted in patients with LS.

## 2. Epidemiology

### 2.1 Incidence / prevalence

The exact prevalence of LS is unknown and is probably underestimated, possibly because LS is underdiagnosed.<sup>74,75</sup> It is a disease commonly seen in “vulval” and “penile” clinics. Together with spongiotic dermatitis and other lichenoid interface dermatoses, it counts for the majority of specimens in pathology departments investigating foreskins.<sup>76</sup>

The suspected prevalence varies between 0.1% and 3% for children and old women (>80 years) respectively.<sup>74,77-79</sup> Extrapolation from the Oxford clinic data suggests that approximately 150 to 200 women per million population present each year.<sup>80</sup> A recent study determined an incidence of LS in women by age 80 of 1.6%.<sup>81</sup> The incidence in males was estimated to be 0.07% according to retrospectively reviewed discharge records at an US Army Medical Centre.<sup>82</sup>

### 2.2 Age at onset

LS can occur at any age. The prevalence of vulval LS increases with age, women after the menopause are most commonly affected, which may not necessarily be linked to the postmenopausal status.<sup>19,79</sup> However, in about 20% of the women the onset of disease is premenopausal.<sup>83</sup> A second peak is thought to occur before puberty<sup>84</sup>; both peaks are in the non-reproductive years and are associated with low oestrogen levels. It could be that a low oestrogen level has an aetiological role which may be linked to the differences in immune responses (oestrogen favours T-cell mediated rather than antibody responses). Alternatively, the age distribution could be related to less lubrication allowing mechanical trauma (Koebner phenomenon). However, Wallace described a continuous increase in incidence from puberty to perimenopause peaking around the menopause with decrease thereafter. In men the incidence seems to increase after puberty, with possibly a prepubertal peak, and decreases again in older age (> 60 years).<sup>79,82,85,86,87</sup> The incidence almost doubled in the third decade in one study; this may, however, be attributed to the study setting being performed at a Military Medical Centre<sup>82</sup> but a peak around the third decade is also observed in a non-military setting.<sup>85</sup>

### 2.3 Sex ratio

Women seem more often affected than men, with a reported female : male ratio between 3:1 and 10:1; however, an equal gender distribution was observed in a Greek general hospital.<sup>58,78,79,87-92</sup>

### 3. Clinical presentation and sequelae of disease

LS is a chronic disease with waxing and waning symptoms. Itch or pain is the main initial complaint in genital LS in women and sexual and urinary dysfunction in men.<sup>93</sup>

#### Females

The characteristic sites involved in females are the interlabial sulci, labia minora, clitoral hood, the posterior fourchette, perineal body and perianal skin (often in girls). Labia majora and the urethral meatus may be affected in rare cases.

Figure 2: Graph of female external genitalia adopted from Gynecologic Dermatology<sup>94</sup>

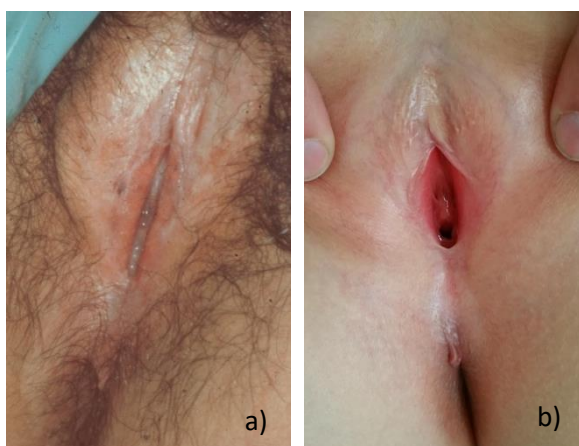
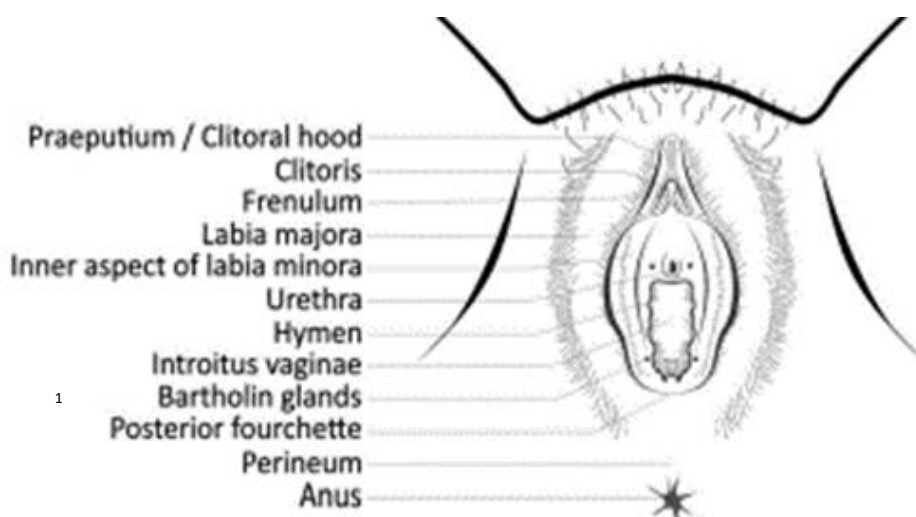
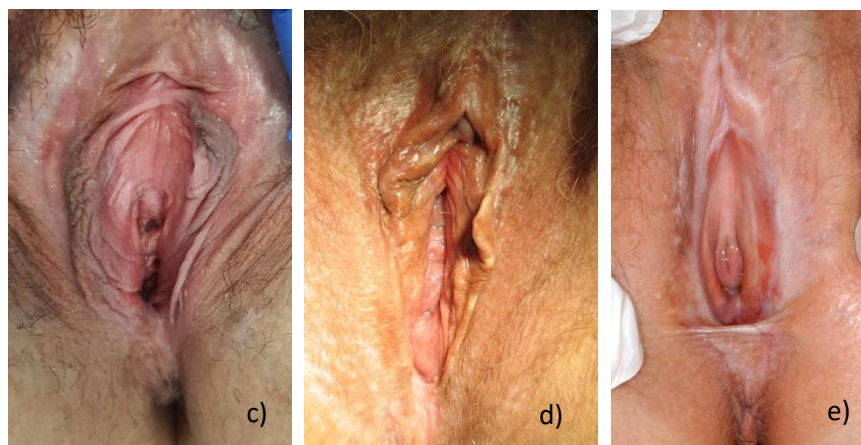


Figure 3 a) – e): Lichen sclerosus in two (pre-)pubertal girls showing severe hyperkeratosis around the clitoris and interlabial sulci in a)<sup>1</sup> and mild hyperkeratosis around the clitoris and posterior fourchette in b). Figure c) shows early LS without any sclerotic changes but complaint of itch, fissuring during intercourse and a short left labium minus (corresponding histology see figure 1a)&b), d) shows white lesions in around the clitoris and possibly posterior fourchette in a woman with LS; and severe hyperkeratosis, fusion above the clitoris resulting in a buried clitoris and regressed / absorbed labia minora resulting in severe architectural changes and an ecchymosis at the left interlabial sulcus, typically seen in LS in e).



### Males

Lichen sclerosus in men and boys usually occurs on the glans penis, coronary sulcus, urethral meatus, and/or foreskin, with a predilection for the perifrenular area, and may cause phimosis in a previously retractable foreskin or adhesions of the foreskin to the glans causing dysuria or painful erection. Acquired (secondary) phimosis in males is highly suspicious to be caused by LS. Rarely the penile shaft, perineal, scrotal and perianal skin are affected. Meatal stenosis may lead to problems passing urine and urinary obstruction; urethral disease can be a severe complication. LS in men is thought to more frequently affect uncircumcised or late circumcised men and occurs only rarely in those who were circumcised shortly after birth.<sup>85,95</sup>

Figure 4: Graph of penile structures

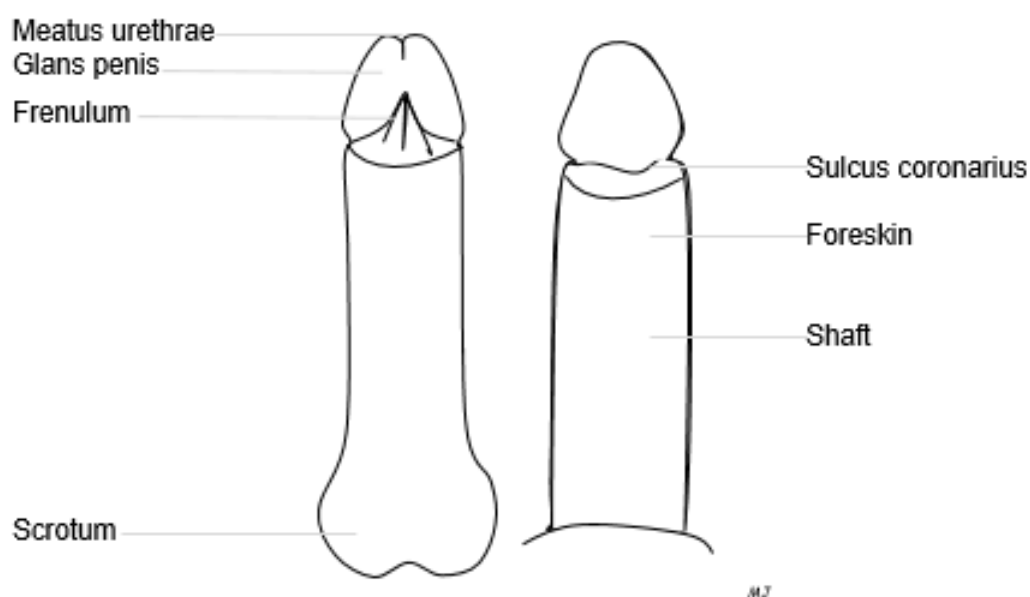
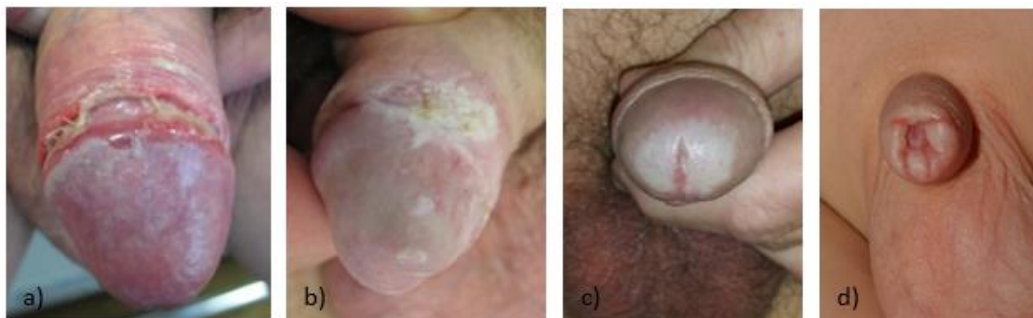

Figure 5: LS in males, a) erosive LS at the sulcus and white lesions at the glans, b) hyperkeratotic plaque at the sulcus, c) pallor or sclerosis at the glans with the meatus affected by LS, d) secondary phimosis in a boy.



Extragenital LS

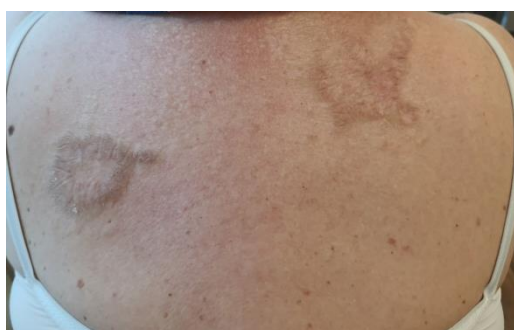

Figure 6: Porcelain like & hyperkeratotic LS at the back

Lichen sclerosus of the extragenital skin alone is rare and has been reported in about 6% of all affected women.<sup>79</sup> Involvement of the scalp, including bullous variants and scarring alopecia, is rare but reported.<sup>96-98</sup> It is generally taught that LS does not affect the oral mucosa, nails or vagina, however, the occurrence at these sites is reported.<sup>88,99-103</sup>

### Symptoms of LS

Women and girls commonly report itching, burning pain, and anal or genital bleeding due to fissuring of the affected tissue. Women also report painful, less pleasurable, or even impossible sexual intercourse due to stenosis and scarring. Painful defecation may be a problem (because of fissures), especially in girls, causing constipation. Soft stools after a fibre rich diet may help. Children may also present with gastrointestinal complaints, besides constipation, regulation of the nutrition and defecation may help.

### Signs of LS

The primary lesions on the skin are flat ivory-coloured spots (Figure 3c and 6), which may merge together into crinkly thin (skin atrophy) or hyperkeratotic patches (Figure 5b and 6). On the vulva or penis there may be oedema, an erythema adjacent to hypopigmented spots (either hyperkeratotic (Figure 5b) or sclerotic) and fissures. Purpura or ecchymoses are typical and harmless but for some patients distressing features of LS. Scarring is common and is observed in about 80% of women and 30% of girls with LS<sup>5</sup>. It may lead to loss and agglutination of the labia minora, possibly midline fusion with fusion of the clitoral hood burying the clitoris and narrowing and rarely obliteration of the vaginal introitus. Perianal involvement is typical in females, rarely seen in males, showing erythema, skin atrophy or sclerosis with erosions and fissures, or rarely scarring possibly leading to anal stenosis.

The Koebner phenomenon that describes the development of lesions in previously normal looking skin after scratching or other trauma is well recognized.<sup>79</sup>

### Symptoms

- Itch (mainly in genital LS in females)
- Pain / Soreness
- Burning
- Irritation
- Feeling of dryness
- Dysaesthesia
- Constipation, in perianal involvement, particularly in girls
- Dyspareunia or apareunia (disturbed sexual functioning)
- Dysuria (pain, disturbed urinary stream)
- Urinary bladder pain (abacterial cystitis)
- LS can be asymptomatic

### Signs

- Oedema (swelling of the skin)
- Slight erythema (redness)
- Hyperkeratosis (white thickened skin; hyperkeratosis on histology)
- Sclerosis (tight, yellowish white skin, e.g. resulting in phimosis; dermal hyalinisation on histology)
- Pallor (pale, whitish areas; the histological correlate is not described)
- Atrophic skin (crinkly skin; epidermal atrophy on histology)
- Fissuring (skin fragility, loss of elasticity leading to splitting of skin)
- Erosions
- Blistering is very rare
- Ecchymoses / purpura is common in genital LS (due to fragile, sclerotic and ectatic blood vessels)
- Changes may be localised to the vulva or include the perianal area, forming a 'figure-of-eight' distribution
- Scarring may lead to architectural changes (e.g. resorption of the labia minora, fusing in the midline with burying, but not loss of the clitoris in women and e.g. phimosis, a narrow meatus urethrae and a sclerotic frenulum breve in men)
- Follicular plugging (in extragenital LS)

**Physicians should be familiar with the various signs of LS. Some of the signs represent early, reversible signs others are permanent, non-reversible signs of LS**

- **Fissures/erosions** are longitudinal/patchy ruptures of the skin surface,
- **Ecchymoses** are bleedings within the skin
- **Hyperkeratoses** are patches/plaques of bright white skin with a 'powdery' appearance.

IMPORTANT: Hyperkeratoses must be distinguished from

- **Sclerosis** that are areas of yellowish/ivory white skin with a smooth/waxy/firm texture

- **Pallor** that are areas of pale whitish skin that differ from hyperkeratoses in that they are not “powdery”. Sclerosis and pallor are usually permanent signs of genital LS, histological correlates need to be defined.

### **Complications**

- Loss of self-esteem (e.g. concern about the genital appearance)
- Impaired quality of life
- Development of anogenital carcinoma (actual risk <5%)
- Development of clitoral pseudo-cyst
- Sexual dysfunction
- Urinary dysfunction
- Genital dysaesthesia

Mental health disorders are an underestimated complication of chronic genital diseases.<sup>104</sup> LS is shown to have a profound effect on mental health.<sup>104</sup> Parygina et al. report that mental health disorders were diagnosed in 22 (66.7%) patients with chronic vulval disease.<sup>105</sup> Mixed anxiety-depressive disorder and depressive episodes were diagnosed most frequently - in 36.4% and 22.7% of patients, respectively. The most significant risk factors for mental health disorders were duration of the disease and itching, followed by the severity of itching according to visual analogue scale (VAS) and itch severity scale (ISS). In addition, high scores of VAS regarding the effect of dermatoses on the quality of life is a risk factor for the formation of mental disorders. Sexual dysfunction, dysmorphology and affection of genital area were less important risk factors for mental health disorders. Patients with these predictors are recommended to consult a psychiatrist.



## 4. Trigger factors

There are hardly any high quality studies reporting potential triggering factors or risks for the development of LS, however, the following aspects are mentioned in the literature and require further investigation.

**An increased risk of developing LS is described under the following circumstances:**

**Trauma / Koebner phenomenon** (appearance of new skin lesions on previously unaffected skin secondary to trauma)

**Pelvic surgery, manoeuvres of the foreskin** “mechanical reduction of the foreskin” performed at least 5-10 times per month and **genital injury** are thought to be triggers in genetically predisposed individuals.<sup>6,19,27,56,106</sup> Baykal et al. describe development of lichen sclerosus on the sites of **striae distensae and a surgical scar** in a patient with coexistent morphea.<sup>106</sup> In a large series of paediatric LS, associations with trauma, autoimmunity, and infection were noted. LS may be associated with sexual abuse, possibly due to genital trauma.<sup>107,108</sup>

### **Parental status / Trauma**

Parous women were at higher risk compared to nulliparous women.<sup>109,110</sup> This finding was not significant when only married women were considered.<sup>111</sup>

### **Radiotherapy**

Radiation-induced lichen sclerosus of the vulval region is reported after radiation for vaginal cancer.<sup>112,113</sup>

### **Urine**

The relevance of urine in the pathogenesis of LS is supported by several observations and studies; the exact mechanism of how urine may act in individuals with a probably genetic predisposition to LS has to be further investigated.<sup>114-120</sup> Gupta et al. reported 6 patients (3 males and 3 females) with histologically-proven LS that showed relative sparing of the uncovered areas of the genitals, thereby suggesting that the occlusion of the genital skin may be playing a greater role in the causation of LS than is currently thought, in both sexes.<sup>11</sup>

A case series further strengthens the urinary occlusion hypothesis for the causation of male genital LS. It is important to recognize that urological interventions can create incompetence of the naviculomeatal valve post voiding. In uncircumcised men, this creates a risk factor for male genital LS that was not previously present. Occlusion, the phenomenon of Koebnerization and currently unelucidated epithelial susceptibility factors lead to inflammation, sclerosis and cancer. Patients and urologists should be aware of these possibilities and preventative measures instituted, e.g. adaptive voiding habits and barrier protection.<sup>120</sup>

Furthermore, a broken barrier function of the skin in atopic individuals may increase the risk factor “urine”.<sup>121,122</sup>

### **Infections**

Various genital infections are debated to be a trigger for LS. Vulvitis and urethritis were associated with LS in one study<sup>110</sup>, however this was not confirmed in another.<sup>19</sup>

### **Borrelia burgdorferi**



The hints towards *Borrelia burgdorferi* as a trigger in LS are impressive and accumulating but remain conflicting. Using focus-floating microscopy, Eisendle et al. detected *Borrelia* species in 38 of 60 cases (63%) of lichen sclerosus and in 61 of 68 (90%) of positive controls of classic borreliosis, but *Borrelia* species were absent in all negative controls. *Borrelia* species were detected significantly more often in early inflammatory-rich (31 of 39 [80%]) than in late inflammatory-poor (7 of 21 [33.3%]) cases ( $P=.001$ ). Polymerase chain reaction findings were positive in 25 of 68 positive controls (37%) and negative in all 11 cases of lichen sclerosus and all 15 negative controls.<sup>123</sup>

Furthermore, investigations by Aberer et al. support the hypothesis that some *Borrelia* species enhance collagen mRNA expression and can stimulate growth factors responsible for increased collagen production.<sup>124</sup>

There are few reports about antibiotic treatment in LS, however, doxycycline, penicillins and cephalosporines were successfully used.<sup>97,125,126</sup> This warrants further studies.<sup>127,128 123,129-154</sup>

### **Mycoplasma**

Mycoplasma infection is thought to be a potential cofactor in LS.<sup>155,156</sup>

Both PCR and ELISA proved a significant presence of Mycoplasma when compared to controls in patients with LS (PCR positivity: 48/51 vs. 12/40,  $p<0.01$ ; ELISA positivity 22/40 vs. 5/26,  $p<0.01$ ), while only PCR data showed significant difference between morphoea patients and controls (17/20 vs. 12/40,  $p<0.01$ ): these cases had no significant Mycoplasma antibody positivity.<sup>150</sup>

### **HPV**

Pilatz et al. provided evidence that HPV is usually not present in the foreskin of boys with persistent phimosis after their first year of life and that topical glucocorticoid treatment failure is not associated with HPV or any specific histopathological changes (LS). These results showed no relationship between HPV and LS and are in accordance with the literature.<sup>157-160</sup>

**Epstein-Barr virus** was found in a preliminary study, the follow-up will elucidate whether EBV could play a role in LS. **Hepatitis C virus** infection and **Helicobacter pylori** are described in single reports to be associated with LS.<sup>161-163</sup>

### **Microbiome**

Alterations of the microbiome may also play a role in the development or chronic course of LS. There are recent studies that demonstrate the role of a dysbiosis in the pathogenesis of LS and correcting the composition of the microbiome may be applicable in supplementary LS therapy by targeting the restoration of the beneficial flora.<sup>164-168</sup> Interestingly, urinary infections and use of absorbents (panty liners) are also reported to be more common in symptomatic LS patients.<sup>169</sup>

### **Psychological factors**

Genital LS has an enormous impact on the patient's psychological and sexual wellbeing. There are some studies that investigated the topic and usually highlight the impact of LS on the patient's quality of life; the psychological constitution as a risk factor is e.g. studied by Grasso et al.<sup>170-172</sup>

Grasso et al. investigated anxiety as risk factor for vulval LS and describe that women ( $n=25$ ) suffering from LS

already have a psychic labile condition with an anxiety degree that will impact on the variability and the progress of LS and could have a causal role in the development of the disease.<sup>170</sup>

### Hormones

Data by Günthert et al. suggest that disturbance of the androgen dependent growth of the vulvar skin by oral contraceptive pills (OCP) and especially by OCPs with anti-androgenic properties might trigger the early onset of LS in a subgroup of susceptible young women.<sup>173</sup>

### BMI / DM / CAD / smoking

People with a family history of diabetes mellitus (DM) and men with elevated body mass index (BMI), diabetes mellitus, coronary artery disease (CAD) and smoking were at increased risk of developing LS.<sup>19,68,91,174</sup>

Development and chronicity of LS may not be a purely dermatologic condition, but may be associated or confounded by systemic disease or vascular compromise like CAD, DM and smoking.

Also Virgili et al. found that overweight and obesity, blood hypertension, hypothyroidism and an educational attainment equal or above upper secondary school level were more frequent among the study patients with LS than among the general Italian population. Moreover, a family history of genital LS was reported more frequently than expected among GLS patients. These factors were similar in males and females. The disease tended to occur later in females than in males.<sup>175</sup>

However, Sideri et al. were not able to support this hypotheses, as no difference was observed in their distribution of cases and controls with reference to education, smoking habits, body mass index, and previous history of diabetes.<sup>109</sup>

Buried penis has been reported as a trigger on several occasions, as has risk of recurrence of LS after surgery in obese males.<sup>176-180</sup>

### Food

Multiple conditional logistic regression analysis showed that vulval dystrophy was positively associated with eating **hot (spicy) food** (OR = 2.55, 95% CI: 1.24 - 5.25), mood (OR = 4.27, 95% CI: 1.96 - 9.29), order of pregnancy (OR = 3.37, 95% CI: 2.11 - 5.40), vulvitis (OR = 6.74, 95% CI: 2.66 - 17.09) and urethritis (OR = 11.02, 95% CI: 1.01 - 120.19).<sup>110</sup>

Eating **pork** is reported to possibly worsen symptoms of LS.<sup>169</sup>

### Medication

A study by Alharbi confirms the association between Immune Checkpoint Inhibitors (ICIs) and LS and lichen planus.<sup>181</sup> Corticosteroid (local/systemic or both) and calcineurin inhibitor treatment might improve patients' pain and prevent the progression of adverse events. In addition, some cases require ICI cessation to achieve complete remission. Finally, LS and lichen planus should be included as a part of the immune-related side effects of checkpoint inhibitor medications.

### Protecting factors

There was no association between retinoids and risk of vulval LS, but intake of carotenoids was inversely and strongly associated with vulval LS.<sup>109</sup>

## 5. Diagnosis

The diagnosis of LS is usually made according to the characteristic clinical appearance. In typical cases a biopsy may not be needed, but many clinicians prefer to take a biopsy at presentation. In children a biopsy of genital skin is not usually performed, because it may be very traumatic for the child. A biopsy should be performed if the clinical diagnosis is uncertain, dysplasia / carcinoma is suspected or if there is failure of first line treatment, also in children.<sup>10,182</sup>

Clinical and pathological correlation is essential. In early disease histology can be non-specific.

### Further investigations

Investigation for autoinflammatory disease should be done if clinically indicated, because some diseases (e.g. thyroid disease, pernicious anaemia, vitiligo, diabetes mellitus) are associated with LS in females.<sup>183</sup> These conditions may be asymptomatic. Skin swabs for bacterial, fungal or viral infection are only useful to exclude co-existing infection, if there are symptoms or signs suggestive of this. Patch testing, an epidermal test on the back to prove a contact allergy, is rarely required and only if secondary (medicament) allergy is suspected. The advice of a dermatologist should be sought.

### LS in children

Special attention has to be paid to children with anogenital disease and it has to be kept in mind that children are not “little adults”.

A child friendly setting must be created. Talking about anogenital problems may be even more difficult for children than for adults. Children should be accompanied by a person they trust and they should be allowed and encouraged to talk about their complaints in their own words.

A safe environment needs to be created. The investigation of the anogenital site should be performed by an experienced physician who knows the disease, the anatomy of the genitals in children and who knows how to deal with children.

The investigation of girls should not be performed using a gynaecological chair, as this may humiliating and may cause anxiety, an examination table is more appropriate. Explain what you are about to do and ask the child for its consent.

If the clinical picture is not diagnostic and you consider a biopsy weigh the pros and cons. Sometimes a second visit after a few months' time will offer a clearer picture, or discuss the case in an interdisciplinary team, or refer to an experienced colleague. A biopsy is the ultimate action and should be avoided whenever possible.

Explain the disease and its treatment in words the child is able to understand, demonstrate where ointments need to be applied and explain the importance of long-term follow-up.

## 6. Differential diagnoses

Mucosal or erosive lichen planus is the main differential diagnosis. Inverse psoriasis, eczema / lichen simplex, non-specific balanoposthitis, vitiligo (particularly difficult in children), morphea, graft versus host disease (GvHD), autoimmune bullous diseases, plasma cell vulvitis/balanitis, Paget disease, ISIL/hSIL and SCCs may show clinical features resembling LS. If the diagnosis is in doubt, a biopsy has to be performed.<sup>184</sup> For more information on diseases that need to be differentiated the IUSTI guideline may be consulted.<sup>185</sup>

One interesting case report describes an erosive vulvovaginitis, histologically not compatible with LS or lichen planus but associated with an intralesional *Borrelia burgdorferi* infection, it resolved after 5 months of treatment with topical clindamycin and oral doxycycline.<sup>186</sup>

Infections and a contact dermatitis may be superimposed, and these should be identified and treated.

## 7. Introduction into treatment

### 7.1 Aims of treatment

Apart from individual treatment goals, the therapeutic approach should in general be multidimensional and aim at:

1. Rapid improvement of symptoms such as pruritus, pain or burning.
2. Maintenance or improvement of quality of life including sexual life or voiding.
3. Disease control looking at signs of disease to avoid i.e. scarring, resorption of structures, skin atrophy, and malignant transformation.
4. Reduction of flare-ups.
5. Cure of LS in males.

For each patient the aims of treatment have to be assessed individually. In the course of the disease, these aims have to be reassessed from time to time.

### 7.2 Assessment of the treatment success

Treatment success should be based on both patient reported outcome measures (PROMs) to assess treatment goals 1.), 2.), and 4.) and on clinician-related outcome measures to address treatment goal 3.). To date, however, there is no consensus as to which assessment tools are to be used for this purpose.<sup>187,188</sup>

The **Core Outcomes for Research in Lichen Sclerosus (CORALS)** project is an interdisciplinary and interprofessional ongoing initiative to establish the most important outcomes to be measured in future trials of genital lichen sclerosus.<sup>189</sup> However, these outcomes “patient-reported symptoms, clinical (visible) signs and quality of life specific to LS” may also be useful features to be evaluated at each visit in clinical practice. It will vary as to how this will be performed; an initial photo at presentation is thought to be very helpful.

During follow-up visits, the treatment success (and potential side effects) may be assessed by longitudinal comparison of the items listed below. An initial photo seems inevitable for comparison of the possible progression of the disease; notes regarding important aspects have to be taken on an individual base:

#### Assessment of treatment:

##### a) Symptoms:

Intensity, 0-10 Numerical Rating Scale (NRS), and duration of itch, pain, burning, soreness, and discomfort.

##### b) Signs:

Erythema, oedema, hyperkeratosis, pallor / hypopigmentation, haemorrhages / ecchymoses, fissures, erosions, ulcerations, sclerosis, fusion of structures i.e. clitoral hood fusion, narrowing of the introitus, fourchette web, labial fusion in women, phimosis and sclerosis of the frenulum in men, meatal and urethral strictures, perianal involvement. Ideally using a grading scale (e.g. Meuli 1994<sup>81</sup>):

1° foreskin can be retracted but shows a narrowing ring, 2° glans is partially visible, 3° meatus is visible, phimosis 4° pin hole.

c) Sexual aspects:

Dyspareunia, anorgasmia, erosions/fissures due to sexual intercourse, erectile dysfunction in men

d) Urological aspects:

- Dysuria, pain of the bladder (abacterial cystitis)
- Lower Urinary Tract Symptoms (LUTS) and urethral strictures (meatus)

e) Gynaecological aspects:

Vaginal discharge/bleeding and menstrual problems in women

f) Other aspects:

- (In)tolerance of topicals, including emollients
- Irritant and/or allergic contact dermatitis, signs of infection
- Psychological aspects, particularly in young adolescents starting to be sexually active


Clinical severity scales to allow intra- and interindividual comparison of treatment response is still an unmet need in the context of LS.<sup>190</sup> For this purpose, the Clinical Lichen Sclerosus Score (CLISSCO) consisting of 3 “Symptoms”, 3 “Signs” and 6 “Architectural changes” rated on a 0-4 point Likert-scale was recently proposed (for vulvar LS only).<sup>190</sup>

After the initial treatment of usually 3 months and subsequent revision and counselling, the intervals of follow-up visits strongly depend on the activity, subjective burden and severity of LS. At each visit the type, amount and place where the creams have to be applied need to be explained:

- In more active disease follow-up visits every 3-6 months may be indicated. In selected cases experiencing intense symptoms visits may be scheduled more frequently.
- In long-term controlled disease, annual visits may suffice to re-adjust topical treatment and check for signs of inflammation and malignant transformation.

## 8. Treatment

### 8.1 Skin care and basic therapy

<p>We <b>recommend</b> the use of topical ointments instead of creams or gels in lichen sclerosus patients.</p>	↑↑	<p style="text-align: right;">&gt;75%</p>  <p style="text-align: right;">(11/12) Consensus-based</p>
<p>We <b>cannot make a recommendation</b> in favour of wearing silk rather than cotton briefs for lichen sclerosus patients.</p>	0	<p style="text-align: right;">100%</p>  <p style="text-align: right;">(15/15) Consensus-based</p>
<p>We <b>suggest</b> avoidance of trigger factors (mechanical factors such as trauma, unnecessary surgical interventions, piercings) and irritants (excessive water exposure or cleansing products, synthetic and tight clothing, use of wet wipes, etc.) at the affected sites in lichen sclerosus patients.</p>	↑	<p style="text-align: right;">100%</p>  <p style="text-align: right;">(15/15) Consensus-based</p>
<p>We <b>suggest</b> regular change of incontinence pads/absorbent pads and urine-soaked undergarments to maintain dry conditions as much as possible, as well as careful management of urine incontinence in lichen sclerosus patients.</p>	↑	<p style="text-align: right;">100%</p>  <p style="text-align: right;">(15/15) Consensus-based</p>
<p>We <b>cannot make a recommendation</b> concerning the use of oral contraceptives in females with lichen sclerosus.</p>	0	<p style="text-align: right;">100%</p>  <p style="text-align: right;">(14/14) Consensus-based</p>

<p>We <b>suggest</b> to avoid the application of over the counter medications, lenitive herbal products, topical antihistamines and anaesthetics and perfumed products due to an increased risk of inducing contact sensitization in lichen sclerosus patients.</p>	↑	<p>100%</p> <p>100 % Agreement</p> <p>(23/23) Consensus-based</p>
<p>We <b>recommend</b> reassuring adherence to adequate treatment and ruling out other causes such as allergies, infections and malignancy if the clinical picture worsens or symptoms like itch or pain increase.</p>	↑↑	<p>100%</p> <p>100 % Agreement</p> <p>(13/13) Consensus-based</p>

## Introduction

Sites affected by anogenital LS are anatomically prone to moisture, friction and occlusion. Maceration and fissuring in LS may be worsened by contact with local irritants e.g. sweat, urine, vaginal discharge, menstrual blood, cleansing products like soap, and underwear.

Contact allergy is another potential aggravating factor for itch and irritation.

Furthermore, the anogenital site is susceptible to fungal, bacterial and viral infections; these may worsen and alter symptoms and the clinical course of LS.

### *General advice to patients with anogenital LS*

- Attention to personal hygiene is important but patients should avoid local application of irritating soaps, shampoos and bubble baths. It is strongly recommended that simple emollients are used as soap substitutes.<sup>191</sup>
- Application of a skin barrier ointment before swimming, bathing or voiding to protect the skin may be useful.
- Regular application of a barrier emollient to protect against local irritants is particularly important in LS patients who are incontinent of any degree, even if minor.<sup>192</sup>
- On anogenital skin, ointment preparations are preferred to creams because they contain less contact sensitizers, are less irritant, allow better skin penetration and provide a better barrier effect.<sup>193</sup>
- Tight-fitting garments should be avoided. One controlled randomized double blind study reported that patients undergoing treatment for LS had fewer symptoms when wearing silk rather than cotton underwear.<sup>194</sup>

### **Silk underwear**

A controlled randomized study showed that women undergoing treatment for LS have fewer symptoms when wearing silk rather than cotton briefs.<sup>194</sup> However, results may be biased because the study was financially supported by the manufacturer, furthermore it is difficult to perform a masked controlled trial, because the



difference between silk fabrics and cotton cannot be hidden. Further studies are needed to verify the effect of silk underwear in genital LS.

#### **Avoidance of triggering factors (see chapter 4)**

Mechanical factors, including friction due to tight clothing, sexual abuse, surgery, radiotherapy or trauma are known to be implicated in both development and maintenance of LS lesions, due to the Koebner phenomenon.<sup>56,112,195,196</sup>

A moist environment and chronic irritation from urine exposure due to occlusion and/or urinary incontinence have been increasingly recognized as trigger factors for LS development and/or LS maintenance. The role of occlusion has been supported by Gupta *et al.*, based on the observation that only the opposing surfaces of glans in men and vulva in women were affected in early stages of the disease, while non-occluded sites were spared.<sup>197</sup> An association between urinary incontinence and LS was initially described by Owen and Yell in a study of seven women, four of whom experienced clearance of LS following control of the incontinence.<sup>115</sup> In addition, a retrospective study suggested that urinary incontinence may be implicated also in the development of paediatric vulval LS.<sup>198</sup> The role of urine and occlusion has been further supported by studies on LS affecting perineal urethrostomies, urostomies and peristomal LS, as well as on males with a history of urological interventions and micro-incontinence.<sup>199-201</sup>

Obesity, arterial hypertension, coronary artery disease, diabetes mellitus and smoking have also been associated with the development and chronicity of LS.<sup>20,68</sup>

The role of infectious agents, particularly *Borrelia burgdorferi*, human papilloma virus, hepatitis C and Epstein-Barr virus, has yet to be elucidated.<sup>146,202,203</sup>

Finally, disturbance of the androgen-dependent growth of the vulval skin by oral contraceptives, especially those with anti-androgenic properties, has been suggested to trigger early onset LS in young women.<sup>204</sup>

#### **Risk of contact allergy**

Studies looking at the prevalence and risk of complicating contact allergy in patients with LS are sparse and characterized by low numbers of included LS patients. Two early studies found relevant reactions when patch testing in 9/19 (47%) and 7/16 (44%) LS patients, respectively.<sup>205,206</sup> The allergens involved included neomycin, clioquinol, and cinchocaine. In a recent study the most common allergens were fragrances, patients' own products and local anesthetics.<sup>207</sup> There were no positive patch tests to corticosteroids among these LS patients.<sup>205,207</sup> However, in a study including 42 LS patients of 66 participants, 4.5% were found to have a positive patch test to topical corticosteroids including two LS patients.<sup>208</sup>

The study by Corazza *et al.* highlighted the frequent use of products based on botanical ingredients among women with itchy vulval diseases, and pointed out that contact dermatitis is a potential adverse effect of those products.<sup>208</sup>


The relevance of patch test results should be carefully evaluated as a positive patch test result does not always implicate a role in aetiology of a vulval dermatitis. A few previous studies have discussed whether the finding of eosinophils or eosinophilic spongiosis in LS, when present, could be a marker for the coexistence of autoimmune bullous disease or allergic contact allergy. One study of 121 patients with vulval LS found that the presence of eosinophilic spongiosis, marked lymphocyte exocytosis, dermal eosinophils and excoriations predicted poor symptomatic response to treatment, and the authors recommended patch testing to rule out an additional allergic contact dermatitis in the case of such histological findings.<sup>209</sup> Keith et al. investigated 235 LS patients, 14% were males and 22% had extragenital, suggested an association between tissue eosinophils in LS and an associated disease, but the finding was not statistically significant. The authors concluded that the finding of tissue eosinophils alone should not lead to examination for an underlying associated disease, e.g. contact dermatitis or autoimmune bullous disease, unless clinical signs of such a condition are present.<sup>210</sup>

### **Treatment of itch**

In addition to pain, itch is a key symptom in genital LS; in fact 62.3% of patients complain of itch.<sup>211</sup> The pathophysiology of itch in LS is thought to be complex and multifactorial.<sup>212</sup> It mainly depends on inflammation and immune dysregulation, therefore only an appropriate therapy of the underlying disease may treat this disturbing symptom which may be controlled in 80-90 % of female LS patients who correctly follow advised standard treatment (e.g. with potent topical steroids).<sup>5</sup> Daily applications of emollients may positively affect itch, preserving the skin barrier integrity and making the skin softer. An open-label non-comparative study, performed in women affected by mild-to-moderate vulval LS, evaluated the efficacy of a topical product containing avocado and soybean extracts and other lenitive and antioxidant principles administered for 24 weeks, in association with a dietary supplement containing avocado and soybean extracts, vitamin E and para-aminobenzoic acid. Amongst 23 included women, the mean itch value decreased significantly at week 12 and 24 compared to baseline.<sup>213</sup> Based on our experience, many patients may benefit from adding itch-relieving compounds such as polidocanol 3% to emollients, but controlled studies to support this observation are still lacking. Particular attention should be paid to sensitizers such as local anaesthetics, e.g. lidocaine, and herbal products, e.g. calendula and menthol which should be avoided.

## 8.2 Topical treatment

### 8.2.1 Emollients

We <b>recommend</b> co-treatment with topical emollients during standard therapy in women with genital lichen sclerosus.	↑↑	100%  100 % Agreement (17/17) Expert Consensus
We <b>recommend</b> co-treatment with topical emollients in girls with genital lichen sclerosus.	↑↑	
We <b>suggest</b> co-treatment with topical emollients in men with genital lichen sclerosus.	↑	
We <b>suggest</b> co-treatment with topical emollients in boys with genital lichen sclerosus.	↑	
We <b>suggest</b> co-treatment with topical emollients in patients with extragenital lichen sclerosus.	↑	

#### Mechanisms of action and efficacy

Emollients may give additional symptom relief after an initial treatment with topical steroids.

An open trial of topical steroid followed by maintenance daily treatment (cold cream) in women showed that symptom relief was maintained, however, one cannot extrapolate from this that this was the effect of the emollient or a long term effect of steroid.<sup>214</sup> A randomized trial of topical vitamin E cream compared to emollient following an initial treatment with topical corticosteroid showed similar relapse rates over a one year period, thus vitamin E does not appear to have any advantage over an emollient.<sup>215</sup>

#### Dosage: acute and maintenance

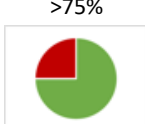
As for the dosage there are currently no publications available. Based on our experience, we recommend applying emollients during the acute phase at least two times a day to moisturize the skin, improve the skin barrier and make it more resistant to irritating external factors such as clothing, toilet paper, sanitary pads, urine, soaps, vaginal discharge, sweat, lubricants, semen and friction during sexual intercourse or sports. In case of vulval burning during urination, application of emollients prior to urination might help to reduce skin contact with urine. However, to avoid a diluting effect of topical steroids, emollients should better not be applied simultaneously.

Following the acute phase, the use of emollients may also be helpful to maintain the improved skin condition. Ideally, they should be applied on a daily basis or at least following the use of soaps in the genital area.

### **Safety and special considerations**


Generally, emollients are very well tolerated and no safety concerns have been raised. However, in rare cases they may lead to irritant or allergic contact dermatitis. For example, additives such as benzoic acid, benzalkonium chloride, polyethylene glycol or sodium lauryl sulphate (SLS) are known irritants<sup>216,217</sup> that may be components of emollients. Likewise, benzoic acid may act as an allergen in emollients as others can such as lanolin, jojoba oil, propylene glycol fragrances and balsam of Peru belonging to the most frequent ones.<sup>216,218</sup> Therefore, only fragrance-free emollients should be used. In case of suspicion of an allergic contact dermatitis either standard patch testing or a repeated open application test (cubital application of the suspected topical with reading after 24 hours and, if no reaction is visible, repeated daily for 7-10 days) might be a simple and helpful test for a delayed type hypersensitivity.

## 8.2.2 Topical and intralesional corticosteroids


We <b>recommend</b> ultrapotent or potent topical corticosteroids in women with genital lichen sclerosus.	↑↑	 <p>&gt;75% (16/17)<sup>1</sup> Evidence- and consensus-based</p>
We <b>recommend</b> ultrapotent or potent topical corticosteroids in girls with genital lichen sclerosus.	↑↑	
We <b>recommend</b> ultrapotent or potent topical corticosteroids in men with genital lichen sclerosus.	↑↑	
We <b>recommend</b> ultrapotent or potent topical corticosteroids in boys with genital lichen sclerosus.	↑↑	
We <b>suggest</b> ultrapotent or potent topical corticosteroids in patients with extragenital lichen sclerosus.	↑	
<sup>1</sup> Abstention		
<p>Ultrapotent topical corticosteroids: Direct evidence available for:</p> <ul style="list-style-type: none"> <li>• Women: <ul style="list-style-type: none"> <li>○ Cochrane review (2 RCTs)</li> <li>○ 5 further RCTs <ul style="list-style-type: none"> <li>▪ Improvement of symptoms: GRADE ⊕⊕⊕⊕ high - ⊕○○○ very low</li> <li>▪ QoL: GRADE ⊕⊕⊕○ moderate - ⊕⊕○○ low</li> <li>▪ Sexual function: GRADE ⊕○○○ very low</li> <li>▪ Urinary function: GRADE ⊕⊕○○ low</li> <li>▪ Patient global assessment: GRADE ⊕⊕○○ low</li> <li>▪ Physician global assessment: GRADE ⊕○○○ very low</li> <li>▪ Minor adverse events: GRADE ⊕○○○ very low</li> </ul> </li> <li>○ 9 non-comparative/non-prospective studies (n=513)</li> </ul> </li> <li>• Girls <ul style="list-style-type: none"> <li>○ 7 non-comparative/non-prospective studies (n=155)</li> </ul> </li> <li>• Women and girls: <ul style="list-style-type: none"> <li>○ 1 RCT <ul style="list-style-type: none"> <li>▪ Improvement of symptoms: GRADE ⊕⊕⊕○ moderate</li> </ul> </li> </ul> </li> <li>• Females age unknown: <ul style="list-style-type: none"> <li>○ 1 non-comparative/non-prospective study (n=59)</li> </ul> </li> <li>• Men: <ul style="list-style-type: none"> <li>○ 4 non-comparative/non-prospective studies (n=104)</li> </ul> </li> <li>• Men and boys: <ul style="list-style-type: none"> <li>○ 1 non-comparative/non-prospective study (n=185)</li> </ul> </li> </ul> <p>Potent topical corticosteroids: Direct evidence available for:</p> <ul style="list-style-type: none"> <li>• Women: <ul style="list-style-type: none"> <li>○ 3 RCTs</li> </ul> </li> </ul>		

- Improvement of symptoms: GRADE ⊕⊕⊕⊕ high - ⊕○○○ very low
- Patient global assessment: GRADE ⊕⊕○○ low
- Physician global assessment: GRADE ⊕○○○ very low
- 14 non-comparative/non-prospective studies (n=988)
- Girls
  - 1 non-comparative/non-prospective study (n=11)
- Boys
  - Cochrane review (1 RCT)
  - 2 non-comparative/non-prospective studies (n=83)

For specific results, see Evidence report

We <b>recommend</b> the use of topical steroid ointments instead of creams or lotions in lichen sclerosus.	↑↑	<p>&gt;75%</p>  <p>(12/13)<sup>1</sup> Consensus-based</p>
--	----	---

<sup>1</sup>1 Abstention

We <b>suggest</b> intralesional corticosteroids to hyperkeratotic lesions in women with topical steroid-resistant genital lichen sclerosus (provided malignancy has been excluded).	↑	<p>&gt;75%</p>  <p>(15/16)<sup>1</sup> Evidence- and consensus-based</p>
We <b>cannot make a recommendation</b> with respect to intralesional corticosteroids in girls with genital lichen sclerosus.	0	
We <b>cannot make a recommendation</b> with respect to intralesional corticosteroids in men with genital lichen sclerosus.	0	
We <b>cannot make a recommendation</b> with respect to intralesional corticosteroids in boys with genital lichen sclerosus.	0	
We <b>cannot make a recommendation</b> with respect to intralesional corticosteroids in patients with extragenital lichen sclerosus.	0	
<sup>1</sup> 1 Abstention		
<p>Direct evidence available for:</p> <ul style="list-style-type: none"> <li>• Women:           <ul style="list-style-type: none"> <li>○ 1 non-comparative/non-prospective study (n=88)</li> </ul> </li> </ul> <p>For specific results, see Evidence report</p>		

**Summary: no uniform recommendation possible:**• **Initial treatment:**

- Clobetasol propionate 0.05% (ointment) or Mometasone furoate seem similarly effective.<sup>219</sup> Usually a fingertip unit is used.
- Some recommend steroid ointments once daily for 3 months; others recommend 1 month daily, then slow reduction to e.g. alternate days application after daily Rx for another 2 months.

**Aim:**

- Healing of fissures & erosions
- Hyperkeratosis should remit almost completely
- Sclerosis should soften: improvement of phimosis
- Pallor and architectural changes will usually not improve

• **Long-term treatment**

**Aim:** It is thought to prevent architectural changes and carcinoma development.<sup>59</sup>

- Some recommend continuous Rx e.g., once or twice per week others treat only active disease (A RCT to investigate this is planned, “PEARLS”: <https://www.fundingawards.nihr.ac.uk/award/NIHR135121>).
- Various potencies of steroids are used; there is most experience with potent or ultrapotent topical steroids.
- There are hardly any steroid-associated adverse effects, like skin atrophy, in continuous long-term treatment observed. Usually a 30 g tube of ointment is sufficient for one year treatment, the steroid ointment has to be applied to the site that initially showed signs of LS.
- Emollients should be used liberally

**General introduction to the topic**

This chapter deals with corticosteroids delivered by topical application and intralesional injection. Corticosteroids possess anti-inflammatory action that can reduce the inflammation of lichen sclerosus.<sup>220</sup>

**Ultrapotent and potent topical corticosteroids****Mechanisms of action and efficacy**

With well-established efficacy and safety, potent or very potent topical steroids like clobetasol propionate 0.05% cream or ointment are recommended as first-line treatment, both in the acute episodes and the maintenance phases.<sup>221,222,223</sup>

Potent topical corticosteroids function as an anti-inflammatory and anti-fibrotic agent. They influence multiple different signalling pathways by switching off activated (pro)-inflammatory genes.<sup>59,220,224</sup> They also have a rapid anti-pruritic effect.

In clinical practice, potent topical steroids rapidly improve local signs and symptoms, usually in less than 10 days.

Creams and ointments are the most frequently used vehicles as they spread easily and adhere adequately to mucosal surfaces. However, as per our experience, several different types of vehicles should be tested by the patient to find the most efficacious and comfortable treatment formulation that helps to maintain adherence. However, ointments are usually less stinging, contain less contact allergens, provide a better barrier function and usually deliver the active ingredient better to the skin than creams or lotions.

The effectiveness of ultrapotent and potent topical steroids appear comparable in the treatment of genital LS. Most studies are performed with ultrapotent steroids (clobetasol propionate), however, in certain situations modern potent steroids like mometasone furoate may be preferred, namely in children because the skin is thinner and steroid related side effects may occur more frequently with ultrapotent steroids and in pregnancy where resorption of the steroid should be avoided because of safety aspects.

### **Females with genital LS**

About 60%-70% of LS patients achieve complete remission of their symptoms after a 3-month course of clobetasol propionate 0.05%, usually once daily application.<sup>5,219,225</sup> Similarly effective was mometasone furoate (MMF) 0.1% once daily after 12 weeks in a head-to-head trial, 59% and 37% of patients in the clobetasol propionate group and 67% and 48% in the MMF group achieved an improvement of at least 75% in subjective and objective scores, respectively.<sup>219,225</sup>

There is evidence that less potent steroids (e.g. triamcinolone and prednicarbate) are also effective as maintenance therapy and for the treatment of moderate episodes or recurrences.<sup>59,226,227</sup>

There are no comparative randomized trials in girls with LS, however, non-comparative studies show that treatment with potent to very potent topical steroids is effective in suppressing signs and symptoms of LS.<sup>228,229</sup> In some patients LS will go into remission after childhood, however, the course is variable and close follow-up during and after puberty needs to be assured in order to detect recurrences of LS early.<sup>230</sup>

### **Males with genital LS**

Both mometasone furoate and clobetasol dipropionate are effective in treating early and intermediate penile LS, but the rate of cure is unknown. A placebo-controlled RCT assessed the efficacy of topical mometasone furoate 0.05 ointment in treating penile LS in 40 boys after 5 weeks' application.<sup>231</sup> Mometasone furoate was found to improve the clinical grade of phimosis in 7/17 boys (41%) after 5 weeks treatment; no improvement was seen in late disease (the treatment was not curative, all were circumcised after topical treatment). No local or systemic adverse events occurred in either group. A study in 56 boys found topical corticosteroids effective in mild LS limited to the prepuce only, but ineffective in those with established scar formation; LS was not proven histologically.<sup>232</sup>



A retrospective study in 21 men with penile LS found clobetasol dipropionate 0.05% cream effective in 16/21 (76%) (6 required circumcision) and safe with no risk of epidermal atrophy after 7 weeks treatment in average.<sup>233</sup> 185 males treated with clobetasol propionate 0.05% (for about 12 weeks with decreasing frequency) were analysed retrospectively, 60% were successfully treated, with a relapse in some reducing it to 50% success rate, the mean follow-up was 15 months.<sup>85</sup>

The risk of development of penile cancer in men with LS is not known.

### **Dosage: acute and maintenance**

In clinical trials, clobetasol propionate 0.05% cream or ointment was applied once or twice daily for 3 months, or in a stepwise approach, i.e., applied once or twice daily for 1 month then once daily or alternate day treatment for 2 months; possibly depending on the severity of signs and symptoms and the age of the patient (women vs girls).<sup>221,225,234</sup>

There is no consensus on the standard dosage regimen for the treatment of LS. The usual recommendation is to apply strong to very strong topical steroids for 3 months without interruption, until complete or nearly complete clinical remission is achieved, followed by either continuous treatment once or twice weekly or ad hoc treatment in case of signs of recurrence (hyperkeratosis, erythema, pruritus).<sup>59,222</sup> In general ultrapotent to potent agents are used in the acute phase and initial treatment periods (1-3 months). Subsequently the topical steroids are tapered.

Only in rare instances, there is a complete remission without recurrence. There is evidence that also less potent steroids (e.g. triamcinolone and prednicarbate) are effective as maintenance therapy and for the treatment of moderate episodes or recurrences.<sup>59,226,227</sup> In active disease the dose may be increased to daily applications for 1 or 2 weeks.

### **Safety**

Adverse effects of topical steroids are rarely seen. Rarely local irritation and burning, especially during the first treatment applications and if the skin is particularly inflamed, are experienced, this is more often observed when creams instead of ointments are used. In the long term, dryness, hypopigmentation, and dermal atrophy may be observed, particularly to keratinized skin. However, topical steroids can be applied in LS over years without significant clinically relevant adverse effects. The undesirable effects of stinging, burning, and xerosis are most commonly linked to the vehicle of the topical steroid rather than to the corticosteroid itself.<sup>235</sup>

However, it is important to point out where the topicals have to be applied and how much has to be used; e.g., one fingertip unit is sufficient to treat the whole vulva. It should be pointed out that the topical steroid has to be applied to areas that are affected by LS, e.g., the clitoris, the labia minora, the interlabial sulci and perineum. Topical steroids must not be applied to unaffected skin where they will cause adverse effects like erythema, irritation and dermal atrophy if continuously used.

### **Monitoring**

There is no specific local or biological monitoring to be considered.

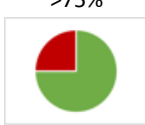
As there is an estimated risk for vulval intra-epithelial neoplasia (VIN) or invasive squamous cell carcinoma (SCC) of approximately 5% in affected women, life-long follow-up annually is recommended.

Any suspicious area, such as new papules/nodules, atypical lesions or non-healing ulcers of areas involved with LS should be biopsied for histological assessment.

### **Intralesional corticosteroids**

Intralesional injection of triamcinolone acetonide or dexamethasone may be an alternative treatment to potent topical steroids in LS for some patients.<sup>236-238</sup> In a 5-year study Ventolini et al. used 5 ml per vulval site in pruritic vulval LS of a solution containing 10ml triamcinolone 2 mg and 0.25% bupivacaine. Ultrapotent topical corticosteroids applied weekly were compared to monthly anaesthetic/corticosteroid subdermal injections combined with topical steroids.<sup>238</sup> The response to injections was more rapid and prolonged, however, patients were less satisfied with the injections; potent topical GCs remain first line.<sup>238</sup> Intralesional steroid injections may be tried if there is a lack of response to potent / ultrapotent topical steroids if e.g. poor penetration (e.g. in very hyperkeratotic lesions) or a lack of compliance is considered.<sup>237</sup> Intralesional corticosteroid injections should be avoided in atrophic skin or in small areas as the tissue may become damaged and ulcerate.

## 8.2.3 Topical calcineurin inhibitors

We <b>suggest</b> topical calcineurin inhibitors in women with genital lichen sclerosus as second choice or as an additional treatment if topical corticosteroids are contraindicated or insufficient. (off label)	↑	 <p>&gt;75% (15/16) Evidence- and consensus-based</p>
We <b>suggest</b> topical calcineurin inhibitors in girls with genital lichen sclerosus as second choice or as an additional treatment if topical corticosteroids are contraindicated or insufficient. (off label)	↑	
We <b>suggest</b> topical calcineurin inhibitors in men with genital lichen sclerosus as second choice or as an additional treatment if topical corticosteroids are contraindicated or insufficient. (off label)	↑	
We <b>suggest</b> topical calcineurin inhibitors in boys with genital lichen sclerosus as second choice or as an additional treatment if topical corticosteroids are contraindicated or insufficient. (off label)	↑	
We <b>cannot make a recommendation</b> with respect to topical calcineurin inhibitors in patients with extragenital lichen sclerosus. (off label)	0	
<p>Direct evidence available for:</p> <ul style="list-style-type: none"> <li>• Women: <ul style="list-style-type: none"> <li>○ Cochrane review (1 RCT)</li> <li>○ 6 non-comparative/non-prospective studies (n=107)</li> </ul> </li> <li>• Girls <ul style="list-style-type: none"> <li>○ 1</li> </ul> </li> <li>• Women and girls <ul style="list-style-type: none"> <li>○ 1 RCT <ul style="list-style-type: none"> <li>▪ Improvement of symptoms: GRADE ⊕⊕⊕○ moderate</li> </ul> </li> </ul> </li> <li>• Boys <ul style="list-style-type: none"> <li>○ 1 non-comparative/non-prospective study (n=20)</li> </ul> </li> </ul> <p>For specific results, see Evidence report</p>		

### General introduction to the topic

Two topical calcineurin inhibitors (TCIs), pimecrolimus 1% cream and tacrolimus 0.1% and 0.03% ointment, licensed for the treatment of atopic eczema, are used off label to treat lichen sclerosus.<sup>239-253</sup> There are few randomized studies comparing TCIs vs. clobetasol propionate in vulval LS.<sup>245,254,255</sup>

### Mechanisms of action and efficacy

Tacrolimus is a lipophilic compound that inhibits the second messenger calcineurin and blocks the transcription of proinflammatory cytokines such as interleukin (IL)-2 and interferon- $\gamma$ . By inhibiting calcineurin, tacrolimus

also reduces antigen presentation and T-cell activation. Moreover, it affects other cell types involved in pruritus and inflammation such as mast cells, eosinophils and basophils by inhibition of IL-3, IL-8, IL-13 and granulocyte/macrophage colony-stimulating factor. On epidermal antigen-presenting cells, the FcεR1 receptor expression is reduced. While many of the pharmacological effects of topical tacrolimus parallel those of corticosteroids, side effects such as skin atrophy and telangiectasia are not observed with topical tacrolimus and pimecrolimus.<sup>243,244</sup>

### **Women with genital LS**

Both groups of a double-blind, randomized trial of 38 women with biopsy-proven vulval LS showed similar improvement in pruritus and burning/pain after a 12-week treatment period with either topical pimecrolimus or clobetasol propionate.<sup>254</sup> Clobetasol was found to be superior in improving inflammation when compared with pimecrolimus (P = 0.015).

The relief of symptoms in LS by pimecrolimus is also supported by several case series.<sup>240,256,257</sup> Complete remission with relief from itch, pain and inflammation was achieved in 35% (9/26) after 2 months and in 42% (11/26) after 6 months. After 2 months twice daily application of pimecrolimus cream 1%, complete (19 of 20) or partial (1 of 20) clinical remission was obtained in 20 patients (80%). Five patients (20%) showed no clinical response. Post-treatment biopsies from 23 women showed decreased p53 staining, the number and staining intensity of Bcl-2-positive basal keratinocytes was increased. Whether the observed decrease in p53 and increase in Bcl-2 expression will provide protection from malignant progression warrants long-term follow-up.<sup>256,258</sup>

The Female Sexual Distress Scale (FSDS) was administered upon enrolment and at the end of the trial in women enrolled in a double-blind 12-week trial comparing clobetasol vs. pimecrolimus for the treatment of LS. Thirty-one of 36 women had adequate treatment of LS as determined by a dermatopathologist's evaluation of pre and post-treatment biopsy specimens. The mean baseline FSDS score for the clobetasol group was 29 and post-treatment it was 15 (p=0.001). In the pimecrolimus group, the mean baseline FSDS score was 27 and post-treatment 21 (P=0.001).<sup>255</sup>

A multicentre, phase II trial assessed the safety and efficacy of tacrolimus ointment 0.1% for the treatment of LS.<sup>244</sup> 84 patients (49 women, 32 men and 3 girls) between 5 and 85 years with long-standing, active LS (79 with anogenital and 5 with extragenital LS) were treated twice daily for 16 weeks. 14 dropped out early (surgery in 8 men?). Clearance of active LS was reached by 43% (ITT 36%) of patients after 24 weeks of treatment and partial resolution by 34% (ITT 29%) of patients. Maximal effects occurred between weeks 10 and 24 of therapy.

Virgili et al. reported 11 women with vulval LS achieving complete remission in 36% and partial remission in a further 55% after 3 months of treatment with tacrolimus ointment 0.1%.<sup>247</sup>

Sotiriou et al. treated 10 postmenopausal women with biopsy-proven recalcitrant vulval LS with tacrolimus ointment 0.1% twice daily for 8 weeks. Analysis of subjective scores showed a positive result of the drug on pruritus, burning and pain. Reduction of symptoms occurred within the first 2 weeks of treatment in all patients. The visual analogue scale decreased from 2.55 at baseline to 0.95 at week 8, but only a minor influence on the hyperkeratosis, atrophy, sclerosis and depigmentation was shown. Nine out of 10 patients achieved a minor improvement in clinical signs. The treatment duration in this study was only 8 weeks, which could explain the poor clinical response.<sup>248</sup>

**Men with genital LS**

Kyriakou et al. assessed retrospectively that clobetasol propionate 0.05% cream is effective in the treatment of genital LS in males. Maintenance therapy with methylprednisolone aceponate 0.1% cream or tacrolimus 0.1% ointment suggests that there is no difference between the two in preventing relapses.<sup>259</sup>

**TCIs in children with genital LS**

There are few case series reporting treatment of LS with topical tacrolimus in children.

Three pre-pubertal girls and 3 adults were treated with 0.1% tacrolimus ointment once daily. All patients experienced complete resolution with long-lasting remission for up to 1 year.<sup>260</sup> Matsumoto et al. reported a 5-year-old girl with vulval LS unresponsive to mild topical corticosteroids, who was treated successfully with tacrolimus ointment 0.03% once daily with complete remission after 14 weeks.<sup>261</sup>

14 prepubertal girls (4 to 11 years) with anogenital LS were treated with 0.03% tacrolimus ointment twice daily for 16 weeks, then 9 of the 14 patients adhered to 2 times weekly for further 6 months (a total of 10 months). Clinical improvement occurred in all patients (100%). Complete response of symptoms and signs was achieved in 5 (36%), 9 (64%) and 11 (79%) patients at 8 weeks, 16 weeks, and 10 months respectively. During the follow-up period of 1 year, 4 of 5 (80%) had a recurrence of symptoms, while only 2 of 9 (22%) patients who were on maintenance therapy developed recurrence of disease.<sup>262</sup>

20 patients after penile surgery with histological confirmation of LS participated in an adjuvant treatment study. Subsequent to surgery parents applied tacrolimus 0.1% ointment twice daily to the glans and the meatus for 3 weeks. Further 18 patients with possible early LS were clinically followed up without any treatment. Clinical follow-up was performed up to 13 months. All 20 LS patients completed the study without any relevant side effects. Two relapses occurred and were treated with an additional 3-week cycle of topical tacrolimus 0.1% ointment. None of the 18 early LS cases progressed to full-scale LS. This study shows that tacrolimus 0.1% ointment applied immediately after surgery in fully established LS is a tolerable and most probably safe adjuvant treatment option. Median disease control in all treated individuals was >1 year.<sup>263</sup>

**Extragenital LS**

Use of topical tacrolimus on its own for extragenital lichen sclerosus proved to be unsuccessful<sup>249,250</sup> or inferior to topical corticosteroids.<sup>245</sup> However, treatment of extragenital LS with tacrolimus combined with UV light was successfully used in few patients.<sup>250,259,264</sup>

**Dosage: acute and maintenance**

There is no consensus on the treatment of topical calcineurin inhibitors for genital lichen sclerosus. The usual approach is to apply topical calcineurin inhibitors initially twice daily possibly followed by once daily, as soon as the lesions regress, for 3 to 6 months continuously.<sup>239,241</sup>

Topical calcineurin inhibitors may be used for maintenance therapy in girls after initial treatment with topical clobetasol 0.05% once or twice daily for several weeks. Steroids may be tapered to once daily applications on weekends and topical tacrolimus 0.1% introduced once daily during the week. With maintained clearance of lesions, clobetasol application may be discontinued and tacrolimus tapered to once daily on weekends only; this may avoid steroid induced adverse effects.<sup>265</sup>

### **Safety**

There are no significant differences in reported adverse drug reactions between clobetasol and pimecrolimus, both appear well tolerated. Although mild local skin reactions like burning and itching lasting for 3– 14 days are reported, in particular with tacrolimus.


Topical calcineurin inhibitors do not seem to induce skin atrophy, hypopigmentation, striae, telangiectasias, rebound flares, or hypothalamo-pituitary adrenal axis suppression. The large molecular size of topical calcineurin inhibitors minimizes their absorption through the skin into the circulation and therefore, their long-term use is associated with minimal systemic absorption with no evidence of systemic accumulation in adult and paediatric pharmacokinetic studies.<sup>251</sup> The blood concentrations of pimecrolimus were checked in 10/26 patients (39%) and were undetectable in all cases, there were no systemic adverse reactions.<sup>240</sup>

Infections such as genital herpes and vulvovaginal candidiasis both occurred in 2% of patients treated with tacrolimus. No malignancy was observed during an 18-month follow-up period.<sup>244</sup> The immunosuppressive effect of topical tacrolimus may have triggered bacterial vaginosis in the context of LS in a 10-year-old girl.<sup>266</sup>

The theoretical safety concern (observed in an animal study) that topical calcineurin inhibitors may increase the risk of lymphoma and other cutaneous malignancies is not supported by multiple case-control, meta-analysis studies and post marketing registries.<sup>252,253</sup>

**In conclusion**, TCIs twice daily for at least 12 weeks have some effect in suppressing symptoms (pruritus, burning, dyspareunia) in LS, however, clinical signs are usually better treated by potent topical steroids.<sup>195,245</sup> Both topical tacrolimus<sup>239,244,246-249</sup> and pimecrolimus<sup>240,246,247,249</sup> are reported to control vulval lichen sclerosus, they are suggested in females with corticosteroid-resistant disease or intolerance to steroids.<sup>223</sup> However, in boys and men, surgical therapy may be more appropriate as a second choice. The long-term use and effect of TCIs in LS is not well investigated.

## 8.2.4 Topical retinoids

We <b>cannot make a recommendation</b> with respect to topical retinoids in women with genital lichen sclerosus. (off label)	0	 <p>100% 100% Agreement (21/21) Evidence- and consensus-based</p>
We <b>cannot make a recommendation</b> with respect to topical retinoids in girls with genital lichen sclerosus. (off label)	0	
We <b>cannot make a recommendation</b> with respect to topical retinoids in men with genital lichen sclerosus. (off label)	0	
We <b>cannot make a recommendation</b> with respect to topical retinoids in boys with genital lichen sclerosus. (off label)	0	
We <b>cannot make a recommendation</b> with respect to topical retinoids in patient with extragenital lichen sclerosus. (off label)	0	
Direct evidence available for: <ul style="list-style-type: none"> <li>• Women:               <ul style="list-style-type: none"> <li>○ 3 non-comparative/non-prospective studies (n=50)</li> </ul> </li> </ul> For specific results, see Evidence report		

### Introduction

Retinoids induce changes in both the dermis and epidermis. Many of their tissue effects are mediated by their interaction with two families of nuclear receptors, the retinoid acid receptors (RARs) and retinoid X receptors (RXRs).<sup>267</sup> An imbalance in the expression of nuclear RARs, namely of RAR- $\alpha$  and RAR- $\gamma$ , has been postulated to be involved in the pathogenesis of -vulval LS.<sup>268</sup>

### Mechanisms of action and efficacy

There are few case series reporting topical retinoids in the treatment of LS.

In an open, uncontrolled clinical study Virgili et al. treated 22 patients with vulval LS with topical 0.025% tretinoin once a day five days per week for one year. Cessation of itch was observed in 76%, 19% improved. 75% had no more burning sensations and 78% had no more pain with sexual intercourse (11% had less pain). Clinical scores improved in 58% showing complete remission of hyperkeratosis, 21% had partial remission. Sclerosis went into complete remission in 5% and partially in 35%; erosions healed completely in 50% and partly in 25%. Remission was obtained up to 12 months post-therapy in 13 patients (4-13; average 7 months); one patient reported a recurrence in month 13.<sup>269</sup>

An 84-year-old women was treated with topical 0.01% tretinoin twice daily for the first month followed by 0.025% topical tretinoin. Two months later the pruritus and clinical appearance had improved.<sup>270</sup>

Topical application of 13-cis retinoic acid (0.5% cis-retinoic acid in ointment) resulted in complete disappearance of LS signs in 11 of 20 patients with LS (6 partial, 3 no response) usually after 1 to 2 months of daily retinoid application. Maintenance treatment followed for 2-4 months once or twice weekly. Follow-up off treatment 4 to 9 months later showed no recurrence.<sup>271</sup>

0,025% topical tretinoin, applied with an alternate-day regimen for a period of 24 weeks induced an improvement of at least 75% in subjective and objective scores, respectively in 35.3% and 17.6% of vulval LS patients (n=17).<sup>272</sup> Moreover, 35.3% and 58.8% of patients achieved an improvement in Global Subjective Score (GSS) of at least 75% and 50% compared with baseline, respectively. Mean scores of itching, leukoderma (pallor) and hyperkeratosis decreased significantly in the study patients.

A retrospective, open label, nonrandomized, comparative cohort study compared the efficacy and tolerability of 12-week mometasone furoate (MMF) 0.1% ointment plus tretinoin 0.05% cream short contact therapy versus mometasone furoate 0.1% ointment plus a cold cream in active VLS. An improvement of at least 75% in subjective and objective scores was achieved in 50% and 61.1% of patients in the former group respectively, compared with 100% and 63.1% in the second group. The combination of MMF with a topical retinoid did not enhance the effectiveness of MMF.<sup>273</sup>

An interesting observation is described by Kaya et al. CD44-targeted deficiency in mouse epidermis results in LS-like histological picture.<sup>38</sup> In human genital and extragenital LS lesions, the epidermal expression of CD44 is decreased or absent, both at the protein and mRNA levels, which is correlated with an accumulation of hyaluronate in the superficial dermis. This suggests that LS might result from an epidermal damage of unknown origin, responsible for a progressive decrease in keratinocyte CD44, subsequently leading to dermal changes in which hyaluronate accumulation is a conspicuous feature.<sup>39</sup> It was hypothesized that restoring epidermal CD44 expression might be a therapeutic target in LS. The topical application of retinoids dramatically increases epidermal CD44 expression at both the protein and mRNA levels in murine and human skin.<sup>274</sup> Retinaldehyde 0.05%, a precursor of precursor of retinoids, strongly inducing CD44 when applied on murine and human skin, was applied twice daily to histologically-proven LS of the vulva in one patient. After one month application significant clinical improvement was observed with the disappearance of the histological characteristics of the disease and the presence of an epidermal hyperplasia, CD44 expression in the epidermis was completely restored and dermal HA disappeared.<sup>274</sup> A double-blind parallel trial in 20 adult patients with biopsy-proven vulval LS comparing mometasone furoate plus retinaldehyde with mometasone furoate plus placebo for 6 months did not allow exploration of the effect of retinaldehyde monotherapy and lacked potency to demonstrate strong synergy with mometasone furoate.<sup>275</sup> It is suggested that agents with the potential of increasing epidermal CD44 should be tried in LS.

### **Safety:**

Side effects, mainly mild erythema and burning, are reported in about 35% of patients.<sup>272</sup> Seldom patients discontinue treatment due to adverse effects.


### **Special considerations:**

Premenopausal women should use contraception when treated with topical retinoids.



Treatment of vulval LS with topical retinoids is thought to have a beneficial effect, and retinoids may be tried if topical steroids fail to reduce hyperkeratosis and may be considered as additional treatment. However, retinoids should not be regarded as alternative to topical steroids and calcineurin inhibitors.

## 8.2.5 Topical hormone preparations

We <b>recommend against</b> topical <u>testosterone</u> and topical <u>dihydrotestosterone</u> in women as a treatment for genital lichen sclerosus.	↓↓	<p>100%</p>  <p>(16/16) Evidence- and consensus-based</p>
We <b>recommend against</b> topical <u>progesterone</u> in women as a treatment for genital lichen sclerosus.	↓↓	
We <b>recommend against</b> topical <u>oestrogen</u> on the vulva in women as a treatment for genital lichen sclerosus. However, women may have additional genitourinary syndrome in which topical vaginal oestrogens may be helpful.	↓↓	
We <b>recommend against</b> topical hormone preparations in girls as a treatment for genital lichen sclerosus.	↓↓	
We <b>recommend against</b> topical hormone preparations in men as a treatment for genital lichen sclerosus.	↓↓	
We <b>recommend against</b> topical hormone preparations in boys as a treatment for genital lichen sclerosus.	↓↓	
We <b>recommend against</b> topical hormone preparations in in patients as a treatment for extragenital lichen sclerosus.	↓↓	
<p>Direct evidence available for:</p> <ul style="list-style-type: none"> <li>● Women: <ul style="list-style-type: none"> <li>○ Cochrane review (5 RCTs with testosterone, dihydrotestosterone, progesterone)</li> <li>○ 1 RCT (testosterone) <ul style="list-style-type: none"> <li>▪ Improvement of symptoms: GRADE ⊕○○○ very low</li> </ul> </li> <li>○ 4 non-comparative/non-prospective (testosterone n=80); progesterone (n=60); clobetasol propionate + estradiol (n=17)</li> </ul> </li> </ul> <p>For specific results, see Evidence report</p>		

### Hormonal receptors of the vulva

The assumed higher incidence of LS in peri- and postmenopausal women suggests a pathogenic role of sex hormones in LS. In an early study by Friedrich in 1984, free serum testosterone and androstenedione were significantly decreased in patients with untreated vulval LS; an abnormal 5 alpha-reductase activity in these patients was suggested.<sup>276</sup> Consequently topical testosterone 2% was used in female LS patients and showed remission of LS in a subgroup of patients, but androgenic side effects like clitoral enlargement, hirsutism, acne

vulgaris and amenorrhoea were common and unacceptable.<sup>10,276,277</sup> In normal female genitals the transition from vagina to vulva is marked by an increase in androgen receptors and a decrease in oestrogen and progesterone receptors.<sup>278</sup> Whether there is a pattern of altered hormone receptor expression or even loss or increase in LS tissue is not clear, but AR expression seems to be decreased.<sup>279,280</sup> It has been suggested that disturbance of the androgen-dependent growth of the vulval skin by oral contraceptives (OCP) and especially by OCPs with anti-androgenic properties might trigger the early onset of LS in a subgroup of susceptible young women.<sup>204</sup> In contrast, progesterone-only methods for contraception were also negatively associated with vulval LS.<sup>19</sup>

Several findings support the influence of a hormonal pathogenesis in LS, which might be important for the treatment of the disease. A regulatory role of sex hormones regarding immunology and repair was shown in cutaneous biopsies.<sup>281</sup> But no significant benefit for topical testosterone, dihydrotestosterone, oestrogens and progesterone in the treatment of LS could be demonstrated in randomized controlled trials (see below).

## **Topical sex hormones**

### **Topical oestrogens**

Topical oestrogens are commonly used as a treatment of postmenopausal vulvovaginal atrophy in women.<sup>282,283</sup> However, the postmenopausal vulva shows only minor shrinkage of tissue, and pronounced atrophy should be regarded as suspicious.<sup>284</sup> Topical oestrogens supplemented to the vagina are a well-established treatment in the oestrogen-deficient post-menopausal situation. Oestrogen decrease can cause dryness and splitting of the skin and mucosa resulting in dyspareunia due to decreased vaginal blood flow and less lubrication but is independent from vulval changes of LS, although both conditions may occur simultaneously. Vaginal treatment with topical oestrogens might be of advantage for sexually active postmenopausal women with LS due to its lubrication effect, to avoid soreness and tearing after intercourse. The vulva itself has few oestrogen receptors which however may be upregulated in some situations.<sup>285</sup> Therefore, topical oestrogens for the treatment of LS alone cannot be recommended, even though published data of comparative trials is not available.

### **Topical testosterone and dihydrotestosterone**


Topical testosterone 2% was used in female LS patients and is reported to induce remission of LS in a subgroup of patients, but androgenic side-effects like clitoral enlargement, hirsutism, acne vulgaris and amenorrhoea were common and unacceptable.<sup>10,276,277</sup> Five RCTs are published that compare testosterone with other treatments.<sup>277,286-289</sup> Two small studies did not find significant efficacy of testosterone 2% after 3 months treatment [participant-rated improvement or remission of symptoms/investigator rated improvement of gross appearance]. No significant difference in severe adverse drug reactions was found between the testosterone and placebo groups.<sup>277,286</sup> A very small cross over trial on dihydrotestosterone vs. placebo found no significant efficacy in either participant-rated improvement of symptoms or investigator-rated improvement of gross appearance.<sup>287</sup> One small study found that testosterone was significantly less effective than clobetasol propionate. No significant differences in adverse drug reactions were found between the testosterone and clobetasol propionate groups.<sup>277,290</sup> A very small cross over trial did not find significant differences in efficacy between testosterone and dihydrotestosterone [participant rated remission of itching; participant rated remission of dyspareunia; investigator rated gross improvement].<sup>288</sup> One small study found, that testosterone, when used as maintenance therapy after an initial treatment with topical clobetasol propionate, worsened the

symptoms ( $P < 0.05$ ) while the vehicle-based placebo caused no change in symptoms or gross appearance.<sup>289</sup> No significant differences in adverse drug reactions between testosterone and placebo were found.<sup>289</sup> We recommend against the treatment of LS with topical testosterone or dihydrotestosterone.

### **Topical progesterone**

Two case series suggested efficacy of topical progesterone in women with vulval dystrophy.<sup>291,292</sup> A small randomized study for the treatment of 79 LS patients with advanced disease and a mean age of 57 years did not find significant efficacy of progesterone 2% cream when compared to topical clobetasol propionate 0.05% [participant rated improvement or remission of symptoms/investigator rated global degree of improvement].<sup>277</sup> Leone *et al.* investigated 30 patients in an RCT: 15 women were treated topically for 6 months with 2.5% progesterone cream and 15 women were treated with Vaseline. Of the patients treated with progesterone, resolution of symptoms was observed in 9, an improvement in 5 and none worsened. Of the controls, five patients had some benefit, and five worsened. The immunohistochemical scores of pre- and post-treatment biopsies investigated for epidermal growth factor and its receptor were significantly higher after progesterone treatment compared to placebo.<sup>293</sup> There is also a report of the use of 2% progesterone cream in vulval biopsy-proven LS in a child. There was complete resolution of her pruritus. The clinically visible signs of LS persisted.<sup>294</sup> A pilot study suggested that topical progesterone is effective in the treatment of early onset LS in young women when used in a concentration of 8%.<sup>204</sup> In a small randomized controlled trial of 37 premenopausal women with histologically confirmed LS topical progesterone 8% was compared to topical clobetasol propionate 0.05%.<sup>295</sup> After 12 weeks of treatment, there were no significant differences in patient-administered symptom scores, but physician-evaluated severity score showed significant differences favouring clobetasol propionate. No severe side effects occurred in any of the study groups, however because there was no placebo arm in the study, it is not clear if topical progesterone treatment is completely ineffective.<sup>295</sup> Nevertheless, topical progesterone has not been shown to be very effective and is not superior to topical clobetasol propionate in the treatment of LS. We suggest against the use of topical progesterone for the treatment of LS.

### 8.3 Platelet rich plasma

We <b>cannot make a recommendation</b> with respect to platelet rich plasma in women with genital lichen sclerosus.	0	100%  (21/21) Evidence- and consensus-based
We <b>cannot make a recommendation</b> with respect to platelet rich plasma in girls with genital lichen sclerosus.	0	
We <b>cannot make a recommendation</b> with respect to platelet rich plasma in men with genital lichen sclerosus.	0	
We <b>cannot make a recommendation</b> with respect to platelet rich plasma in boys with genital lichen sclerosus.	0	
We <b>cannot make a recommendation</b> with respect to platelet rich plasma in patients with extragenital lichen sclerosus.	0	
Direct evidence available for: <ul style="list-style-type: none"> <li>• Women:               <ul style="list-style-type: none"> <li>○ 1 non-comparative/non-prospective study (n=28)</li> <li>○ 1 non-comparative/non-prospective study (adipose-derived mesenchymal cells + platelet-rich plasma) (n=15)</li> </ul> </li> <li>• Females age unknown:               <ul style="list-style-type: none"> <li>○ 1 non-comparative/non-prospective study (n=15)</li> <li>○ 1 non-comparative/non-prospective study (adhesiolysis followed by PRP) (n=38)</li> </ul> </li> <li>• Men and boys:               <ul style="list-style-type: none"> <li>○ 1 non-comparative/non-prospective study (n=45)</li> </ul> </li> <li>• Mixed adults:               <ul style="list-style-type: none"> <li>○ 1 RCT (AD-SVF+PRP vs. AD-SVF) (n=40)                   <ul style="list-style-type: none"> <li>▪ Improvement of symptoms: GRADE ⊕○○○ very low</li> <li>▪ QoL: GRADE ⊕⊕○○ low</li> </ul> </li> <li>○ 1 non-comparative/non-prospective study (n=94)</li> </ul> </li> </ul> For specific results, see Evidence report		

#### General introduction to the topic:

Platelet rich plasma (PRP) is an autologous blood-derived product that contains platelet concentrations at least 2/3 times above the normal level and includes platelet related growth factors.<sup>296</sup> The concept of PRP began in the 1970s in the field of haematology to treat patients with thrombocytopenia. In the 1980s and 1990s, PRP began to be used in surgical procedures such as maxillofacial surgery and plastic surgery. Since then, PRP had been used in orthopaedic procedures, cardiac surgery, sports injuries, plastic surgery, gynaecology, urology, and more recently in medical esthetics.<sup>297</sup> Platelets contain  $\alpha$  granules that provide various growth factors and cytokines, such as platelet derived growth factors (PDGF), transforming growth factor  $\beta$ 1 (TGF  $\beta$ 1), TGF  $\beta$ 2, vascular endothelial growth factor (VEGF), basic fibroblast growth factor (bFGF) and epithelial growth factor (EGF)<sup>298</sup>, which are important for healing processes by influencing inflammation, angiogenesis, stem cell

migration and cell proliferation.<sup>296,299,300</sup> According to the working definition of PRP, the concentration for PRP must be 1,000,000 platelets/ $\mu\text{l}$ ,<sup>301</sup> to best stimulate proliferation of endothelial cells and angiogenesis, which in turn has a positive effect on certain diseases.<sup>302</sup>

PRP is produced from the individual's own blood by centrifuging venous blood and removing erythrocytes and platelet poor plasma. There are different systems for the production of PRP (commercially marketed systems or systems developed specifically for experimental studies), resulting in heterogeneous preparations.<sup>303</sup> This affects the comparability of PRP studies.

### **Mechanisms of action and efficacy:**

#### Vulval lichen sclerosus

In a randomized, double blind, placebo-controlled trial 19 women received 2 treatments of PRP (5 ml each (subdermally / intradermally) separated by 6 weeks) and 10 received placebo treatments. There was no significant difference in the histopathological evaluation of inflammatory infiltration or in the Clinical Scoring System (CSS) for vulval LS between PRP and placebo.<sup>304</sup>

15 patients treated with the same treatment regimen in an uncontrolled pilot study. 7/12 (58%) patients who completed the trial showed decreased inflammation on their post treatment biopsies, and 5/12 (42%) had no change or an increase in inflammation. The Investigator's Global Assessment (IGA) indicated a statistically just significant improvement after treatment (pre-treatment:  $2.67 \pm 0.49$  vs post-treatment  $1.83 \pm 0.83$ ;  $p=0.0054$ ). Changes in subjective VAS scores for pruritus and burning were not statistically significant.<sup>305</sup>

A small uncontrolled cohort study of 28 women unresponsive to topical steroids were treated with 3 PRP treatments 4 to 6 weeks apart and again at 12 months. After the last treatment, no lesion was visible in 8 (29%), in 17 (61%) the lesion was smaller than at the beginning of the therapy and in 3 (11%) there was no change. 15 patients (54%) had no more symptoms after treatment.<sup>306</sup>

#### Penile lichen sclerosus

45 male patients, who failed to improve after at least 6 months of ultrapotent topical steroid therapy or who requested an alternative treatment, were treated with at least two (median 4; range 2 – 10) PRP treatments (1–3 ml each). The authors described a significant improvement after PRP treatment ( $p < 0.001$ ), both in the IGA on a six-point Likert scale and in the DLQI (change of IGA  $2.04 \pm 0.71$ ; change of DLQI  $7.73 \pm 4.92$ ).<sup>307</sup>

#### Mixed

In a case series by Tedesco et al. 13 male and 18 female patients with genital LS were treated with 2-4 mL of PRP 3 times every 15 days.<sup>308</sup> After 12 months follow-up, an improvement of the symptoms was observed in 19 patients (62%), stability was observed in 11 patients (35%) and worsening of the disease was observed in one patient (3%).<sup>308</sup> In a later study Tedesco et al. compared the efficacy of PRP in 43 male and 51 female patients with genital LS.<sup>287</sup> Also in this trial patients received 2-4 mL of PRP 3 times every 15 days. It is unclear whether the patients described in the first trial were also included in this study. 52.1 % of the patients were symptom free after PRP therapy, but 14.9 % of the patients stated that they were symptom free before the PRP treatment. The number of patients who still suffered from itching, pain and burning after the treatment was significantly reduced in both sexes (women: 80-->22%, 33-->8%, 37-->16% respectively; men: 37-->9%, 19-->5%, 23-->3% respectively). A statistically significant reduction in dyspareunia was only observed in men (men 34% -->12%; women 37% -->31%).<sup>309</sup>

**Dosage:**

There are no dosage standards. In most studies, 2-5 ml of PRP were injected subdermally and intradermally.<sup>304,305,309,310</sup> In most studies, 2-3 treatments were applied at intervals of 2-6 weeks.<sup>304-306,309,310</sup>

However, there were also patients who received up to 10 PRP treatments.<sup>307</sup>

In some studies, PRP was activated with CaCl<sub>2</sub> or thrombin before injection to stimulate the platelet degranulation.<sup>306,311</sup> In other studies, no prior *ex vivo* activation took place.

**Safety:**

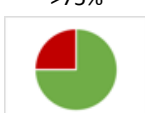
No adverse reactions were reported except transient discomfort and bruising at the injection sites.<sup>305</sup>

**Special considerations:**

Some studies mention that the injection site was anaesthetised with numbing creams or injections of local anaesthetics before PRP treatment.<sup>306,307,309</sup>

There are some small trials investigating the efficacy of surgical interventions with additional PRP treatment. In a RCT 40 patients with genital LS (16 females; 24 males) were treated with adipose tissue derived stromal vascular fraction (ADSVF) or with ADSVF-enriched PRP therapy. The combination therapy was not better and in advanced disease even worse.<sup>310</sup> In other uncontrolled cohort studies patients were treated with adipose-derived mesenchymal cells and PRP or with adhesiolysis followed by PRP.<sup>312,313</sup>

## 8.4 UV therapy

We <b>suggest</b> UVA 1 therapy in women with genital lichen sclerosus as a second choice treatment, taking into account carcinogenicity and practicality.	↑	<p>&gt;75%</p>  <p>(14/15)<sup>1</sup> Evidence- and consensus-based</p>
We <b>recommend against</b> UV therapy in girls with genital lichen sclerosus.	↓↓	
We <b>cannot make a recommendation</b> with respect to UV therapy in men with genital lichen sclerosus.	0	
We <b>recommend against</b> UV therapy in boys with genital lichen sclerosus.	↓↓	
We <b>recommend</b> UV therapy in patients with extragenital lichen sclerosus.	↑↑	
<sup>1</sup> Abstention		
<p>Direct evidence available for:</p> <ul style="list-style-type: none"> <li>• Women: <ul style="list-style-type: none"> <li>○ 1 RCT (UVA-1) <ul style="list-style-type: none"> <li>▪ Improvement of symptoms: GRADE ⊕⊕○○ low- ⊕○○○ very low</li> <li>▪ QoL: GRADE ⊕⊕○○ low</li> <li>▪ Physician global assessment: GRADE ⊕○○○ very low</li> </ul> </li> </ul> </li> <li>• Extragenital: <ul style="list-style-type: none"> <li>○ 2 non-comparative/non-prospective studies (UVA-1) (n=20)</li> </ul> </li> <li>• Mixed (genital and extragenital involvement): <ul style="list-style-type: none"> <li>○ 1 non-comparative/non-prospective study (UVA-1) (n=14)</li> </ul> </li> </ul> <p>For specific results, see Evidence report</p>		

### **Mechanisms of action and efficacy:**

Phototherapy, especially with ultraviolet (UV) A, is an effective and well established treatment option for sclerosing skin diseases such as morphea and extragenital LS, and numerous studies (including prospective controlled trials) have been performed for both conditions.<sup>314-318</sup> In contrast, only few data exist on the efficacy of UV therapy for genital LS, and most reports are based on small case series or single case reports. In an open pilot study including 12 patients with anogenital inflammatory diseases (including genital LS, genital lichen planus, and vulval eczema), cream psoralen plus UVA (PUVA) chemophototherapy resulted in a significant clinical improvement (reduction in size of lesions, erythema, and/or pruritus; 10-20 treatments in most patients).<sup>319</sup> In 2006, the first case series of genital LS treated with UVA1 phototherapy was published. All patients were women with severe genital LS uncontrolled by ultrapotent topical corticosteroids. Three patients had moderate and two had minimal clinical improvement, and one of these relapsed within 3 months and another after a year. Both had a further course of UVA1 therapy, resulting in minimal improvement in one and moderate improvement in the other. In the remaining three, disease severity had improved to a point where intermittent use of topical corticosteroids resulted in acceptable control.<sup>320</sup>



In a randomized-controlled study comparing the efficacy of UVA1 phototherapy (applied in a special UVA1 device) with high potent topical corticosteroids (0.05% clobetasol propionate) in 30 women with genital LS, UVA1 resulted in a significant clinical improvement but was inferior to topical high potent corticosteroids with respect to practicability, relief of itch, and improvement in quality of life. The predominantly reported short-term adverse effects of UVA1 phototherapy in this study were mild and included erythema, pruritus, xerosis cutis, and tanning.<sup>321</sup>

**Dosage:**

Low (20 J/cm<sup>2</sup>) or medium (50-50 J/cm<sup>2</sup>) dose UVA1 phototherapy for a total of 40 applications per cycle.

**Safety:**

In general, UVA1 is well-tolerated, side-effects might include early erythema directly after irradiation, tanning of the irradiated lesion as well as itching or burning shortly after treatment.

**Monitoring:**

If possible, clinical examination during UVA1 should be performed weekly or every 14 days.

**Special considerations:**

UVA1 phototherapy can be combined with topical corticosteroids or topical calcipotriol (2 hours before or after irradiation).

UVA1 is less potent than topical high-potent corticosteroids in suppressing signs and symptoms of genital LS.

UVA1 might be considered as alternative therapy for genital LS in cases that failed to respond to other treatments.

**UV light in extragenital lichen sclerosus**

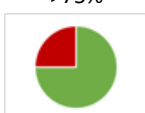
Only few studies exist on the safety and efficacy of UV light in extragenital LS.<sup>322-324</sup> However, the efficiency of UVA1 phototherapy in extragenital LS was first established by Kreuter *et al.* in 2001.<sup>323</sup> The authors report improvement of LS lesions following 40 sessions of long-wave UVA1 irradiation (four sessions per week for ten weeks, total of 40 treatments, 20 J/cm<sup>2</sup> low-dose UVA1 per session, 800 J/cm<sup>2</sup> cumulative dose). One year later, Kreuter *et al.* were able to present the improvement of extragenital LS in ten patients, all being treated by the established standard irradiation protocol.<sup>324,325</sup>

As far as PUVA therapy in extragenital LS is concerned, one case report demonstrated a promising therapeutic attempt.<sup>326</sup> Interestingly, single UVA1 progressed from 0.3 to 2.3 J/cm<sup>2</sup> resulting in a cumulative dose of 31.7 J/cm<sup>2</sup> during a six week period.

Narrowband (NB)-UV-B phototherapy alone or in combination with salt water (balneophototherapy) is a well-established therapy for psoriasis. Similar to UVA1, only few case reports exist on NB-UVB for extragenital LS.<sup>322,327</sup> However, a large RCT in patients with morphea has shown that NB-UV-B significantly improved skin lesions, but medium-dose UVA1 was significantly more effective than NB-UV-B.<sup>328</sup> Based on these findings, NB-UV-B might be considered as an alternative treatment for extragenital LS in centres where UVA1 is not available.

Care has to be taken in patients who may have additional connective tissue diseases, such as lupus erythematosus, which may pose a contraindication for light treatment.<sup>329</sup>

## 8.5 Photodynamic therapy

We <b>cannot make a recommendation</b> with respect to photodynamic therapy in women with genital lichen sclerosus. (off label).	0	 <p>&gt;75% (14/15)<sup>1</sup> Evidence- and consensus-based</p>
We <b>recommend against</b> photodynamic therapy in girls with genital lichen sclerosus.	↓↓	
We <b>cannot make a recommendation</b> with respect to photodynamic therapy in men with genital lichen sclerosus. (off label)	0	
We <b>recommend against</b> photodynamic therapy in boys with genital lichen sclerosus.	↓↓	
We <b>cannot make a recommendation</b> with respect to photodynamic therapy in patients with extragenital lichen sclerosus. (off label)	0	
<sup>1</sup> Abstention		
Direct evidence available for: <ul style="list-style-type: none"> <li>• Women:               <ul style="list-style-type: none"> <li>○ 1 RCT (ALA-PDT)                   <ul style="list-style-type: none"> <li>▪ Improvement of symptoms: GRADE ⊕⊕○○ low</li> </ul> </li> <li>○ 11 non-comparative/non-prospective studies (ALA-PDT) (n=423)</li> </ul> </li> </ul> For specific results, see Evidence report		

### **Mechanisms of action and efficacy:**

In contrast to UV therapy, robust data exist on the use of photodynamic therapy (PDT) in vulval LS. A recently published review of the literature on PDT for genital LS included 11 prospective studies, 5 case series, and 4 case reports.<sup>330</sup> Only one controlled cohort study exists.<sup>331</sup> The number of patients in all studies on PDT for vulval LS ranged from 1 to 102. 5-aminolevulinic acid (5-ALA) was used as the photosensitizer in the majority of studies (n=17), and 19 reports used red light (one report used green light) as light source. In 16 studies, resolution of pruritus, which causes major discomfort for patients with vulval LS, was reported. Besides subjective symptoms, Li et al. reported a significant reduction of objective LS findings including leucoplakia, erythema, hyperkeratosis, purpuric lesions, and itching related excoriations.<sup>332</sup> However, other studies found no objective improvement following PDT.<sup>333,334</sup>

### **Dosage:**

In most studies, 20% 5-ALA was applied for 4-6 hours (mostly 3 hours), followed by coherent (630nm) or non-coherent (570-670nm) red light. Doses might fluctuate between 9 and 180 J/cm<sup>2</sup>, with a range of 100–150 J/cm<sup>2</sup>

in most studies. For light intensity, a minimum of 40 and a maximum of 700 mW/cm<sup>2</sup> can be applied. 3 to 5 PDT procedures might be necessary.


**Safety:**

The overall tolerability (pruritus and mild pain in most cases) of PDT in vulval LS was good, and none of the studies were discontinued due to complications. PDT treatments may be repeated several times, with no risk for development of resistance.

**Special considerations:**

PDT is a valuable therapeutic option for vulval LS refractory to standard treatment with high potent topical corticosteroids. PDT is particularly effective in terms of resolution of subjective symptoms, e.g. pruritus.

## 8.6 Laser therapy

We <b>cannot make a recommendation</b> for fractionated ablative CO <sub>2</sub> laser treatment in women with genital lichen sclerosus.	0	<p>100%</p>  <p>(15/15) Evidence- and consensus-based</p>
We <b>cannot make a recommendation</b> for non-ablative Nd:YAG laser in women with LS in order to soften the tissue.	0	
We <b>cannot make a recommendation</b> for ablative CO <sub>2</sub> laser treatment in men with genital lichen sclerosus.	0	
We <b>cannot make a recommendation</b> for non-ablative Nd:YAG laser in men with Lichen sclerosus in order to soften the tissue.	0	
We <b>cannot make a recommendation</b> with respect to laser treatment in patients with extragenital lichen sclerosus.	0	
We <b>cannot make a recommendation</b> for combination laser treatment in lichen sclerosus (e.g. ablative and non-ablative).	0	
We <b>recommend against using</b> laser treatment in children with Lichen sclerosus.	↓↓	
<p>Direct evidence available for:</p> <ul style="list-style-type: none"> <li>• Women: <ul style="list-style-type: none"> <li>○ 2 RCTs (CO<sub>2</sub> laser) <ul style="list-style-type: none"> <li>▪ Improvement of symptoms: GRADE ⊕⊕○○ low - ⊕○○○ very low</li> <li>▪ QoL: GRADE ⊕⊕⊕○ moderate</li> <li>▪ Sexual function: GRADE ⊕○○○ very low</li> <li>▪ Urinary function: GRADE ⊕⊕○○ low</li> <li>▪ Patient global assessment: GRADE ⊕⊕○○ low - ⊕○○○ very low</li> <li>▪ Physician global assessment: GRADE ⊕⊕○○ low</li> <li>▪ Minor adverse events: GRADE ⊕○○○ very low</li> </ul> </li> <li>○ 1 RCT (Nd:YAG laser) <ul style="list-style-type: none"> <li>▪ Improvement of symptoms: GRADE ⊕⊕○○ low - ⊕○○○ very low</li> <li>▪ Patient global assessment: GRADE ⊕⊕○○ low</li> <li>▪ Physician global assessment: GRADE ⊕○○○ very low</li> </ul> </li> <li>○ 6 non-comparative/non-prospective studies (CO<sub>2</sub> laser) (n=159)</li> <li>○ 1 non-comparative/non-prospective study (Er:YAG laser) (n=28)</li> </ul> </li> <li>• Females age unclear: <ul style="list-style-type: none"> <li>○ 1 non-comparative/non-prospective study (CO<sub>2</sub> laser) (n=42)</li> </ul> </li> <li>• Men: <ul style="list-style-type: none"> <li>○ 2 non-comparative/non-prospective studies (CO<sub>2</sub> laser) (n=72)</li> </ul> </li> </ul>		

- Mixed adults:
    - 1 non-comparative/non-prospective study (CO<sub>2</sub> laser) (n=10)
- For specific results, see Evidence Report

## General introduction to laser treatment in lichen sclerosus

Laser therapy has recently been suggested as a new treatment option for genital LS. Recommendations are based on a few studies including mostly women.

Patients should be aware of commercial practices highlighting the efficacy of laser therapy in genital LS. Before performing laser therapy, patients should carefully discuss such treatment with a practitioner (dermatologist, gynaecologist, urologist) specialized in the management of LS.

### What is the aim of laser treatment in LS? / What can be achieved with this treatment in LS?

Various lasers are in use:

**Fractionated CO<sub>2</sub> laser** has got a wavelength of 10,600 nm allowing a superficial microablative effect in soft tissues. The ablative CO<sub>2</sub> laser may reduce hyperkeratoses, but will not suppress the inflammatory process and should therefore be used in combination with topical steroids. It is especially useful in hyperkeratotic disease. (Ongoing studies NCT05010421, NCT04951206, NCT05243563, NCT03665584).

**Nd:YAG laser**, 1064 nm wavelength, has an adequate penetration depth (5 mm) to induce a heat response in the dermis without ablative change. It is thought to reduce inflammation and remodel collagen, and possibly softens sclerosis and reduces fissuring. It is not known if e.g. during and after Nd:YAG laser treatment topical anti-inflammatory treatment will be needed.

By variation of pulse settings, the **Er:YAG laser** with a wavelength of 2940 nm can be used in an ablative or a non-ablative mode. Non-ablative settings have an adequate penetration depth to induce a heat response in the dermis, ablative settings enable the peeling of the skin surface.

**The combination** of Er:YAG and Nd:YAG lasers allows superficial ablation plus regeneration of the deep connective tissue (ongoing study NCT03926299).

A systematic review for laser treatment in genital LS discusses 24 studies, including 6 RCTs.<sup>305</sup> Diode laser, non-ablative Nd:YAG laser and fractionated CO<sub>2</sub> laser were used. Unfortunately, results were highly heterogeneous and the methodological quality was very low. Therefore, no meta-analysis could be performed. The authors conclude that there is not enough high-quality evidence to recommend laser treatment for genital LS and that long-term data over 6 months are missing.

## Carbon dioxide (CO<sub>2</sub>) laser

### Efficacy

In a prospective, randomized, double-blind and placebo-controlled study comparing 19 women treated with fractionated CO<sub>2</sub> laser and 18 women with a sham laser, no significant improvement in the histopathological change of vulval LS with fractionated CO<sub>2</sub> laser therapy compared with sham treatment (95% CI -1.14, 1.06,  $P=$ .76) was found, indicating that fractionated CO<sub>2</sub> laser is not an effective monotherapy for genital LS.<sup>306</sup> A large placebo effect has been observed since women in both the active treatment arm and sham treatment arm experienced a statistically significant improvement in symptoms, highlighting the importance of randomized controlled trials.

Two studies analysed the efficacy of the CO<sub>2</sub> laser treatment in men and women with no other disease than LS.<sup>335,336</sup> In a retrospective study of 62 men, Windahl showed that after a median follow-up of 14 years, 80% of the patients had neither symptoms nor signs of LS.<sup>335</sup> However, no control group or histopathological evaluation was available. Kartamaa et al. retrospectively concluded the efficacy of the CO<sub>2</sub> laser for skin lesions in a small number of patients, 5 men and 5 women. Skin lesions improved but reoccurred in some patients.<sup>336</sup>

Results are conflicting and potential confounders have to be considered: a) there is a known positive effect of the fractionated laser treatment on the genitourinary syndrome of menopause (GSM). Therefore, because of potential overlap of symptoms in some studies it may be difficult to clearly distinguish if the treatment effect is improving GSM or LS symptoms<sup>2</sup>; b) in some studies, topical steroids were continued during laser treatment<sup>3</sup> and c) methodological quality was poor<sup>335,336</sup>. In summary, a beneficial effect of the CO<sub>2</sub> laser on clinical symptoms in women with genital atrophy (GSM) can be assumed, however, a direct effect on the lichenoid inflammatory reaction of LS is at this point questionable.

### **Safety**

CO<sub>2</sub> laser treatment of genital LS was mostly well tolerated.<sup>337,338</sup> Before treatment, numbing of the skin is always needed.

Balchander *et al.* described a burning pain lasting for more than 7 days in 2 out of 40 women.<sup>339</sup> Minor burning and blistering at the laser site has also been observed by Burkett *et al.*<sup>340</sup>

### **Ongoing trials:**

NCT03665584: The purpose of this study is to look at the efficacy and safety of the FxCO<sub>2</sub> laser treatment (laser energy emitted) for LS as compared to a sham treatment (very minimal laser energy emitted).

NCT05010421: In this prospective, randomized, open-label, comparative study, treatment success after 3 courses of non-ablative treatment with CO<sub>2</sub> laser every 14 days will be compared with treatment success after topical application of clobetasol 0.05% over 3 months (daily in the first month, every other day in month 2, and 3 times/week during month 3) at the time point 3 months after treatment initiation.

## **Neodymium:yttrium aluminium garnet (Nd:YAG) and Erbium:yttrium aluminium garnet (Er:YAG) lasers**

### **Efficacy**

In a randomized, non-blinded study comparing 20 women using both topical steroids plus 3 non-ablative Nd:YAG laser sessions to 20 women using topical steroids alone, Bizjak-Ogrinc et al. showed no statistical difference in inflammation between the two groups comparing pre-treatment and post-treatment biopsies.<sup>341</sup> Symptoms including itch, burning and pain rated on a visual analogue scale were reduced in both groups compared with baseline but they were statistically significantly better in the laser group at one and 3 months follow-up and the effect was still significant at 6 months, although these symptoms started to increase again.

A non-controlled study of 28 women treated with Er:YAG laser showed a statistically significant reduction of itching and pain (pre- versus post-treatment) but no change in dyspareunia and hyperkeratosis.<sup>342</sup> A control group or histopathological evaluation of the effect was not available.

### **Safety**


Nd:YAG laser treatment for genital LS was well tolerated. Numbing of the skin is not necessarily needed. Some patients reported minimal discomfort described as a sensation of warmth in the study of Bizjak-Ogrinc et al.<sup>341</sup> In the study of Gomez Frieiro et al. 7% of the women considered the treatment by Er:YAG as tolerable.<sup>342</sup>

### **Ongoing trials:**

NCT03926299: The aim of this study is to test a new, minimally invasive dual laser technique to treat vulval LS. Efficacy and safety of the thermal non-ablative Nd:YAG laser and the ablative Er:YAG laser (FotonaSmooth SP® Spectro laser device) is determined and compared to the current standard treatment with high dose topical steroids. The hypothesis is that laser therapy is effective and similar to standard steroid therapy. Results are expected in 2023.



## 8.7 Cryotherapy

We <b>cannot make a recommendation</b> with respect to cryotherapy in women with genital lichen sclerosus.	0	 <p>100% 100% Agreement (21/21) Evidence- and consensus- based</p>
We <b>cannot make a recommendation</b> with respect to cryotherapy in girls with genital lichen sclerosus.	0	
We <b>cannot make a recommendation</b> with respect to cryotherapy in men with genital lichen sclerosus.	0	
We <b>cannot make a recommendation</b> with respect to cryotherapy in boys with genital lichen sclerosus.	0	
We <b>cannot make a recommendation</b> with respect to cryotherapy in patients with extragenital lichen sclerosus.	0	
Direct evidence available for: <ul style="list-style-type: none"> <li>• Women and girls:               <ul style="list-style-type: none"> <li>○ 1 non-comparative/non-prospective study (n=31)</li> </ul> </li> </ul> For specific results, see Evidence report		

### **Mechanisms of action and efficacy:**

Cryotherapy, also known as cryosurgery or cryoablation, is a minimally invasive procedure to freeze superficial cutaneous lesions. Liquid nitrogen (temperature  $-196^{\circ}\text{C}$ ) is used in most cases as cryogen. Cryotherapy is an easy to perform, inexpensive and highly effective treatment option for a variety of cutaneous diseases, including actinic and seborrheic keratoses, viral warts, or keloids.<sup>343</sup> It may be applied as open spray, cryoprobe or close contact technique.<sup>344</sup> No controlled studies exist on the use of cryotherapy for vulval LS. In a retrospective case series of 22 adult and 9 juvenile patients with vulval LS, all patients experienced a significant clinical improvement of skin lesions and symptoms, especially in pruritus.<sup>345</sup>





### **Dosage:**

Based on the current lack of robust data, cryotherapy cannot be recommended as a first or second line treatment for vulval LS. However, in experienced hands cryotherapy may be considered (1 cycle for 4 to 8 seconds on an area of about 4 square centimetres, excluding the clitoris, preferably in open spray or cryoprobe technique after application of topical anaesthetic agents) as a treatment option in patients with unbearable pruritus in whom guideline-conform treatment has failed.

### **Safety:**

Patients have to be informed about side effects of cryotherapy, which include blistering of the skin and pain.

## 8.8 Systemic treatment

<p>We <b>suggest</b> acitretin, taking into account teratogenicity, if systemic therapy is needed in women with genital lichen sclerosus. (off label)</p>	<p>↑</p>	<p>&gt;75%</p>  <p>(17/18)<sup>1</sup> Evidence- and consensus-based</p>
<p>We <b>suggest</b> acitretin if systemic therapy is needed in men with genital lichen sclerosus,. (off label)</p>	<p>↑</p>	<p>&gt;75%</p>  <p>(15/17)<sup>2</sup> Evidence- and consensus-based</p>
<p>We <b>suggest</b> MTX, taking into account teratogenicity, if systemic treatment is needed in adult patients with genital and/or extragenital lichen sclerosus,. (off label)</p>	<p>↑</p>	<p>&gt;75%</p>  <p>(15/16)<sup>1</sup> Consensus-based</p>
<p>We <b>recommend against</b> potassium para-aminobenzoate as a treatment for lichen sclerosus.</p>	<p>↓↓</p>	<p>100%</p>  <p>(15/15) Evidence- and consensus-based</p>
<p><sup>1</sup> Abstention <sup>2</sup> Abstention</p>		
<p>Direct evidence available for:</p> <ul style="list-style-type: none"> <li>• Women: <ul style="list-style-type: none"> <li>○ 1 RCT (acitretin) <ul style="list-style-type: none"> <li>▪ Improvement of symptoms: GRADE ⊕⊕⊕○ moderate</li> <li>▪ Patient global assessment: GRADE ⊕⊕⊕○ moderate</li> <li>▪ Minor adverse events: GRADE ⊕⊕⊕⊕ high</li> </ul> </li> </ul> </li> <li>• Men: <ul style="list-style-type: none"> <li>○ 1 RCT (acitretin) <ul style="list-style-type: none"> <li>▪ Improvement of symptoms: GRADE ⊕⊕⊕○ moderate</li> <li>▪ QoL: GRADE ⊕⊕⊕○ moderate</li> <li>▪ Physician global assessment: GRADE ⊕⊕⊕⊕ high</li> </ul> </li> </ul> </li> </ul>		

- Mixed adults:
    - 1 RCT (paraminobenzote)
      - Improvement of symptoms: GRADE ⊕○○○ very low
  - Extragenital LS:
    - 1 non-comparative/non-prospective study (MTX) (n=24)
- For specific results, see Evidence report

## **Introduction**

Many systemic treatments have been tried to improve LS. These include glucocorticosteroids; oral retinoids; ciclosporin; methotrexate; hydroxycarbamide, an antineoplastic drug used in myeloproliferative disorders; cycloferon, a low molecular weight interferon inducing substance; fumarate, used in the treatment of plaque psoriasis; hydroxychloroquine an antimalarial drug, used to reduce inflammation in the treatment of e.g. rheumatoid arthritis and lupus erythematosus; antibiotics (penicillins, cephalosporins, dirithromycin, doxycycline etc.); sulfasalazine, a sulfa drug and derivative of mesalazine, used in the treatment of inflammatory bowel disease and rheumatoid arthritis; Vitamin D, 1,25-dihydroxyvitamin D, the biologically active, hormonal form of the nutrient is important in the metabolism of calcium and phosphorus and is critical in building and maintaining healthy bones; Vitamin A & E, Vitamin A plays a role in regulating epithelial proliferation and differentiation, there are anti-oxidant effects of Vitamin E; potassium para-aminobenzoate, PABA is an intermediate in the bacterial synthesis of folate (Vitamin Bx) and is structurally similar to Sulfonamide drugs. The potassium salt is used as a drug against fibrotic skin disorders.<sup>223</sup> Biologics were recently tried in single cases, bigger studies have to show their effect.

The level of evidence is very low and the drugs are not tried in all forms of LS.

## **Systemic retinoids**

### **Mechanisms of action and efficacy**

There are several case series as well as two RCTs reporting on the treatment of LS with oral retinoids. In an open uncontrolled study Mørk et al. observed an improvement of clinical symptoms (patients' and physicians' assessment) in 6 of 8 patients with treatment-resistant vulval LS on oral etretinate (1 mg/kg/day) after 14-18 weeks.<sup>346</sup> Romppanen et al. treated 19 women with vulval LS with oral etretinate for 3 months (initial dose 0.54 mg/kg/day, maintenance dose 0.26 mg/kg/day).<sup>347</sup> A decrease in severity was achieved in nearly all cases among the group with severe vulval dystrophy.<sup>347</sup> Furthermore, two small double-blind, placebo-controlled studies for the treatment of genital LS with acitretin are published.<sup>348,349</sup> In a multicentre, double-blind study, Bousema et al. treated patients (78 enrolled, 46 included in efficacy analysis) with vulval LS with 20 to 30 mg acitretin or placebo for a total of 16 weeks. Symptoms and signs improved in the treatment group as well as in the placebo group. However, intensity of all symptoms and signs was lower in the acitretin group, with a statistically significant difference for pruritus, atrophy, and hyperkeratosis.<sup>348</sup> In another RCT by Ioannides et al., 52 male patients with severe, long-standing LS were randomised in a 2:1 ratio to receive acitretin (35 mg) or placebo for 20 weeks. Mean total clinical score of the acitretin group was significantly lower than that of the controls, which

was also accompanied by a significant improvement in mean DLQI.<sup>349</sup> Based on these results the authors concluded that acitretin is effective in longstanding male LS.<sup>348</sup>

### **Safety**

Retinoids are usually well tolerated, but sicca symptoms often occur as a side effect. Cholesterol, triglycerides and liver enzyme levels can increase during therapy, and should be checked regularly before and during therapy. Systemic retinoids are highly teratogenic, therefore all women of childbearing age must use safe contraception (during therapy and, depending on the drug, for up to three years after cessation of therapy).

### **Special considerations**

Retinoids may be considered if standard therapy for LS has failed.

## **Methotrexate**

### **Mechanisms of action and efficacy**

Methotrexate (MTX) is an antimetabolite and antifolate drug and acts by inhibiting the metabolism of folic acid. It is used in treatment of cancer and autoinflammatory diseases. A retrospective case series described 28 patients with LS, (24/28 with extragenital involvement) who were treated with MTX 2.5 to 17.5 mg weekly. There was initial improvement of LS in 21/28 cases and sustained improvement in 15 cases. Most patients were treated in combination with topical steroids or tacrolimus.<sup>350</sup> In another trial 7 patients with generalized LS (5 genital plus skin; 2 only skin) were treated with high-dose intravenous methylprednisolone sodium succinate, given as a 1000mg single dose for 3 consecutive days monthly plus MTX 15mg/week (oral) for at least 6 months (max. 10 months). All were previously unsuccessfully treated with topical steroids and UV phototherapy. Cutaneous LS in all patients improved after usually 3 months of treatment; 100% cure was not achieved and the effect on genital lesions was not reported. Adverse effects observed (nausea in 3 patients, headache in 3, and a 2-fold increase of liver enzyme levels in 1) were moderate and disappeared after the end of treatment.<sup>351</sup> A patient with generalized LS involving the skin and anogenital site was successfully treated with MTX 10mg/week for 8 months; improvement was noticed by 3 weeks and excellent response after 5 months.<sup>352</sup>

### **Dosage**

MTX between 10 and 15 mg/week (subcutaneous or oral) for 6 months possibly combined with systemic steroids is reported to improve treatment resistant generalized LS.

### **Safety**

The most common side effects are gastrointestinal problems, headache, fatigue, mood changes<sup>353</sup>, and elevated liver enzymes. Pancytopenias occur mainly in overdoses. Idiopathic pulmonary fibrosis has rarely been reported. Before starting MTX therapy, chronic infections (e.g. hepatitis B/C, HIV, tuberculosis) must be excluded and vaccinations following local guidelines are recommended. Complete blood count, kidney and liver profile are mandatory before and regularly during therapy. National guidelines should be consulted.

### **Special considerations**

Taking 5 mg of folic acid per week on a "non-MTX day", e.g. 24 hours after the administration of MTX, may reduce haematological side effects. Women and men must use safe contraception during therapy and for 6 months after therapy.

### **Potassium para-aminobenzoate**

#### **Mechanisms of action and efficacy**

PABA is an intermediate in the bacterial synthesis of folate (Vitamin B<sub>9</sub>) and is structurally similar to sulfonamide drugs. The potassium salt is used as a drug against fibrotic skin disorders.

A double blind placebo-controlled trial of oral para-aminobenzoate (Potaba) was carried out with 25 patients suffering from genital and extragenital LS. Potaba 3 g capsules four times daily versus placebo was tested in a RCT. Of the 21 patients who completed the two months trial, six showed some improvement on Potaba against seven on the placebo, an insignificant difference. Adverse effects were bad taste, vomiting and a rash.<sup>354</sup> Potassium para-aminobenzoate cannot be recommended.

### **Doxycycline**

#### **Mechanisms of action and efficacy**







The hints towards *Borrelia burgdorferi* as a trigger in LS are impressive and accumulating but remain conflicting. There are few reports about antibiotic treatment in LS, however, doxycycline, penicillins and cephalosporines were successfully used<sup>97,125,126</sup>; this warrants further study.


There are hardly any studies on the effect of doxycycline in LS, however, if standard treatment with topical steroids fails, doxycycline may be tried.

#### ***Other therapeutic approaches***

There are initial considerations and first case reports of treatment with biologics. A case of extragenital LS with itch and lichenification responded to dupilumab<sup>355</sup> and a case of ankylosing spondylitis and extragenital LS responded to secukinumab.<sup>356</sup> Two case reports described two patients with penile LS treated with intralesional adalimumab 40 mg/ml either twice weekly for 3 months (then every 6 weeks for 8 months) or once every 2 weeks for 8 weeks.<sup>357,358</sup> Both patients achieved significant improvement, with one patient experiencing complete relief of urinary symptoms after four biweekly injections and later CR after transitioning to subcutaneous administration of adalimumab. The other patient achieved near CR after 4 weeks, which was sustained for 8 months until a 10-week gap in treatment resulted in relapse. The patient was thereafter continued on biweekly injections with maintenance of mild disease. No side effects were reported.<sup>359</sup>


## 8.9 Surgical interventions

<p>We <b>suggest</b> de-adhesion / synechiolysis / perineoplasty in <u>women</u> with lichen sclerosus who have a persistent introital stenosis that causes mechanical problems in voiding or sexual intercourse, despite guideline-conform treatment with steroids..</p>	<p>↑</p>	<p>&gt;75%</p>  <p>(14/17)<sup>1</sup> Consensus-based</p>
<p>We <b>recommend against</b> surgical treatment for management of genital lichen sclerosus in <u>girls</u>.</p>	<p>↓↓</p>	<p>&gt;75%</p>  <p>(17/18) Consensus-based</p>
<p>We <b>suggest</b> circumcision, preferably removing the complete foreskin if guideline-conform treatment with e.g. steroids in <u>men</u> with phimosis caused by lichen sclerosus fails.</p>	<p>↑</p>	<p>100%</p>  <p>100 % Agreement (16/16) Consensus-based</p>
<p>We <b>suggest</b> frenuloplasty in combination with intralesional triamcinolone or alternatively, a complete circumcision if guideline-conform treatment with e.g. steroids in <u>men</u> with scarring or shortening of the frenulum caused by lichen sclerosus fails.</p>	<p>↑</p>	<p>100%</p>  <p>100 % Agreement (13/13) Consensus-based</p>
<p>We <b>suggest</b> urethroplasty using oral mucosa grafts in <u>men</u> with urethral stricture due to lichen sclerosus causing mechanical problems in voiding or sexual intercourse.</p>	<p>↑</p>	<p>&gt;75%</p>  <p>(12/15)<sup>2</sup> Consensus-based</p>
<p>We <b>suggest</b> circumcision, preferably removing the complete foreskin if guideline-conform treatment with e.g. steroids in <u>boys</u> with phimosis caused by lichen sclerosus fails.</p>	<p>↑</p>	<p>100%</p>  <p>100 % Agreement (15/15) Consensus-based</p>

<p>We <b>suggest</b> frenuloplasty in combination with intralesional triamcinolone, or alternatively, a complete circumcision if guideline-conform treatment with e.g. steroids fails in <u>boys</u> with scarring or shortening of the frenulum caused by lichen sclerosus.</p>	<p>↑</p>	<p>&gt;75%</p>  <p>(13/15)<sup>1</sup> Consensus-based</p>
--	----------	---

<sup>12</sup> Abstention

<sup>23</sup> Abstention

<p>Prior to surgery in females we <b>recommend</b></p> <ul style="list-style-type: none"> <li>• that women are informed about and agree to the continuation of topical treatment after surgery, usually with topical steroids.</li> <li>• interdisciplinary counselling including specialized pelvic floor physiotherapists and sex therapists.</li> </ul> <p>For surgical procedures in males <b>we recommend</b></p> <ul style="list-style-type: none"> <li>• removing the complete foreskin</li> <li>• having the removed foreskin investigated by a histopathologist to confirm lichen sclerosus and to exclude precancerous lesions like severe dysplasia, requiring a close follow-up after surgery.</li> <li>• pre- and post-operative treatment with topical corticosteroid ointments, e.g. 4 weeks before and 4-12 weeks after the procedure, starting 1 week postoperatively.</li> </ul>	<p>↑↑</p>	<p>&gt;75%</p>  <p>(14/15)<sup>1</sup> Consensus-based</p>
--	-----------	---

<sup>11</sup> Abstention

### **Surgical interventions in females**

Vulval LS can at any age cause scarring of the genitalia including agglutination of the labia minora, phimosis of the clitoral hood and narrowing of the introitus<sup>59,360-362</sup> leading to a decreased quality of life including sexuality and voiding problems. Surgical interventions in females with LS are indicated to improve urinary and sexual function, quality of life, treat precancerous lesions or vulval cancer. Treatment of LS associated vulval cancer will not be discussed in this guideline.

Women with vulval LS have a significantly decreased Female Genital Self-Image Scale (FGSIS), which correlates with sexual function.<sup>363</sup> Brauer et al. investigated the motives of women with LS undergoing surgery.<sup>17</sup> The main motives were the desire to be a “normal” woman, the desire to sexually satisfy the male partner, and the desire to regain the experience of intimacy and sexual enjoyment.<sup>364</sup> However, Lauber et al. observed a high number of patients with recurrent LS activity after surgery (56.1 %); this may be triggered by increased sexual activity after surgery or surgery itself.<sup>365</sup> Also Rangatchew et al. describe an increase in dyspareunia/apareunia after surgery in sexually active women as a result of LS relapse.<sup>366</sup>

Furthermore, several other factors affect women’s sexual life apart from LS, such as pelvic floor and vaginal spasms, lower urinary tract symptoms (LUTS) and psychological aspects. Some of the patients also report sensory symptoms, which might not only be due to scarring, but driven by damage of small nerve fibres during the course of LS.<sup>367</sup>

Interdisciplinary counselling including specialized pelvic floor physiotherapists and sex therapists prior to surgery is crucial. Surgery requires a strict protocol of perioperative treatment, including good local care and pre- and postoperative application of topical steroids until the wounds are healed. Prior to surgery, the motivation for vulval surgery and the expectations regarding the surgical outcome need to be clarified and discussed in order to achieve treatment satisfaction. Surgical treatment should be reserved for symptomatic patients suffering e.g. from recurrent tearing during intercourse (vulval granuloma fissuratum), phimosis with possibly decreased clitoral sensation and stenosis of the introitus or urethral opening.

All these factors need to be discussed prior to surgery and patients need to be carefully selected in order to have a good chance for the desired outcome after surgery. Furthermore, after the surgery the recommended treatment for LS (anti-inflammatory treatment, emollients) has to be continued long-term.

Women with LS very often suffer from lower urinary tract symptoms (LUTS), including abacterial cystitis. Urethral strictures due to LS are hardly observed in women and surgical intervention for this problem in females is sparsely described.<sup>368</sup>

**Perineoplasty** (modified Fenton's procedure), during which the posterior fourchette is excised and replaced by a tension-free vaginal advancement flap, was shown to be a safe procedure in these patients, with a low complication and a high satisfaction rate.<sup>369-373</sup>

Perineoplasty provides good functional results, enabling patients to resume or regain painless vaginal intercourse with a high satisfaction rate and low complication rate. In a long-term survey of 41 patients who underwent perineoplasty and de-adhesion, the overall satisfaction rate improved over time (90% after at least 6 months), suggesting good long term results in compliant patients.<sup>365</sup> However, in this study patients underwent surgery to improve their sexual life, but 31.7% of patients were postoperatively not sexually active. There are no randomized studies available in this setting, so it can be assumed that studies are performed in highly selected patients. More recent studies report that surgery improved the sexual life in most patients, however, most patients still had pain during intercourse.<sup>365,366,372,374,375</sup> In most studies patients were treated perioperatively with topical steroids. In case the perineoplasty procedure is not successful or as an alternative approach Frapell et al. suggests a double opposing Z-plasty with VY advancement of the perineum (Plymouth procedure).<sup>376</sup>



**Other surgical treatments** are the lysis of the labial fusion, de-hooding of the clitoral glans in case of phimosis (de-adhesion) and anterior vestibuloplasty with vaginal epithelium grafts.<sup>365,371,372,374</sup>

### **Surgical interventions in males**

If the standard anti-inflammatory treatment of LS in males does not lead to the desired result, surgery may be an option.

There is no surgical gold standard for the treatment of male genital lichen sclerosus. All recommendations have been based on non-randomized studies and expert opinion.<sup>377</sup>

Indications for surgery in males with LS are:

- Phimosis
- Sclerosis of the frenulum
- Lesions of the glans (expecting that they may improve after removal of the foreskin)
- Urethral strictures
- Cancerous or precancerous lesions

**Circumcision** for phimosis and changes of the glans

- Complete removal of the foreskin is recommended
- The removed foreskin should be sent for histological investigation to confirm LS and to exclude precancerous lesions like severe dysplasia or carcinomas, requiring a close follow-up after surgery.
- During circumcision it is mandatory to carefully evaluate and calibrate the external urethral meatus and navicular urethra (e.g. using progressive Nelaton plastic catheters from 10 to 16 Charrière).
- Potential adverse effects must be explained to the patient:
  - bleeding,
  - infection,
  - meatal stenosis,
  - loss of sensibility of the penile skin and/or
  - fistulae of the urethra after circumcision are rare, even in case of LS surgery;
  - psychological problems (rare)
  - circumcision in general bears the risk of meatal stenosis (around 1%), mainly seen in boys (because of the small lumen), but in cases of LS it is tenfold higher (10%). The reason could be the inflammatory process of the perifrenular area.
- In obese patients with LS the “environment” has to be restored. Occlusive effects of a “fat apron” need to be avoided and repaired if possible.
- Circumcision offers the highest rate of cure, but if the foreskin is preserved, preputioplasty and intralesional triamcinolone may be offered.

### **Urethral strictures**

The involvement of the urethra in LS is well known. Often the anterior male urethra (meatus, navicular, penile and bulbar tracts) is affected in genital LS,<sup>378-380</sup> however, also other parts of the urethra may be affected.<sup>381</sup> LS patients presenting with obstructive or irritative urinary symptoms are requested to have uroflowmetry and retrograde and voiding urethrography performed to determine if and where LS affects the urethra.

The surgical interventions for LS urethral stricture repair are related to the site and extension of the disease.

1. Strictures involving the external urinary meatus and navicular urethra are managed by:
  - A) Wide meatotomy
  - B) One-stage meatoplasty using oral mucosa transplant
  - C) Two-stage meatoplasty using oral mucosa transplant
  
2. Strictures involving the penile urethra are managed by:
  - A) First-stage urethroplasty (Johanson procedure).
  - B) One-stage urethroplasty using oral mucosa transplant.<sup>382</sup>
  - C) Two-stage urethroplasty using oral mucosa transplant.
  
3. Strictures involving the penile and bulbar urethra (pan-urethral stricture) are managed by:
  - A) One-stage urethroplasty using two oral mucosa grafts transplant.<sup>383</sup>
  - B) Definitive urinary diversion by perineal urethrostomy.<sup>223,384,385</sup>

It is very difficult to provide definite advice regarding the technique of choice, there are no randomized studies. The surgical technique should be based on the following parameters:

- Site, extension and pathological involvement of the urethra by LS.
- Surgical background and preference of the surgeon.
- Patient's counselling and acceptance of the surgeon's choice.

All these procedures are highly specialized and should only be performed by experienced surgeons. Potential adverse effects include:<sup>386</sup>

- Development of fistula
- Urinary tract infection
- Strictures

### **Surgical intervention in boys**

#### **Circumcision**

A recent review showed that topical corticosteroids in boys prevent circumcision in up to 35% of cases.<sup>387</sup> Median follow-up time however was short (median 4 months, range 6 weeks to 5 years). LS is thought to rarely occur in circumcised males<sup>388</sup> and circumcision is thought to have a high cure rate, but good studies are missing.

However, there are several studies which point out the curative effect of complete circumcision in boys. In a prospective study 10 boys with LS were clinically controlled 5 years after surgery and showed no signs of

recurrence.<sup>86</sup> This observation was confirmed in a much greater prospective series of 471 LS cases. 471 boys were followed up to for 12 months postoperatively, then yearly (no information about the mean follow-up time and the reason why half of the patients were lost to follow-up). At 1 year follow-up all patients were still in remission; the lesions of the glans disappeared within 6 months in 229 boys, in the remaining boys thereafter. The more severe the lesions are, the later they usually resolve, e.g. in the second year post-surgery.<sup>389</sup>

A couple of studies point out the necessity of complete removal of the foreskin to prevent recurrence. One retrospective series of 225 LS cases report 5 recurrences (50%) out of 10 LS cases treated by partial circumcision.<sup>87</sup>

### **Adverse effects**

In boys with LS, meatal stenosis, urethral strictures, and phimosis may be observed during the surgical procedure. Cohort studies show that 7–20% of boys circumcised for LS subsequently need a meatal procedure in the form of a meatotomy or meatoplasty within weeks to several months after circumcision.<sup>390</sup> However, a second operation only weeks after CC bears a high risk of recurrence; it should only be performed several months later, once LS is in remission.<sup>87</sup> Homer et al. showed that boys with LS requiring meatal procedures (meatal dilation in 25, meatotomy in 24) rarely underwent a meatal procedure at circumcision (4 of 49) and were less likely to have received preoperative topical steroids compared to boys not needing a later meatal procedure (2 of 49 vs 49 of 151,  $p < 0.05$ ).<sup>391</sup> Therefore, males with LS should be carefully investigated preoperatively and all features of LS should be operated on in the same procedure; furthermore, postoperative treatment with a potent topical steroid may reduce the rate of meatal stenoses (from 10% to 5%).

Wilkinson showed the successful combination of preputioplasty and intraoperative injection of triamcinolone into the LS lesions in 84 out of 104 cases.<sup>392</sup> 84 of 104 (81%) in the preputioplasty group had a fully retractile foreskin and no macroscopic evidence of LS. Of 104, 14 (13%) developed recurrent symptoms/LS requiring circumcision or repeat foreskin preputioplasty.<sup>392</sup> Lansdale et al. compared preputioplasty and intralesional triamcinolone (PIT) and circumcision in an RCT. However, due to small numbers of participants the efficacy of the technique could not be judged. There is no information about preoperative treatment.<sup>393</sup>

Recurrence after complete circumcision is reported particularly in cases of obese males with buried (concealed) penis.<sup>87,394-397</sup>

### **Meatodilatation, Meatotomy, Meatoplasty**

The rate of meatal stenoses is reported in 2%-37% patients with penile LS.<sup>389,395</sup> Meatal stenosis can be part of the initial clinical picture or develop several months after circumcision (as part of LS or as an adverse effect of surgery).

### **Urethral stenosis in boys**

Urethral LS is also seen after surgery for hypospadias in boys. In a descriptive analysis of 1.176 patients with failed hypospadias repair requiring further surgery 89 (7.6%) had histologically proven LS.<sup>398</sup> Apart from these special circumstances urethral LS in boys has been reported in only 5 cases (2 out of 130 LS cases: Barbagli 2004;

3 out of 41 LS cases: Gargollo 2005).<sup>381,395</sup> Both studies collected data over a period of 10 years. All five patients underwent one or more procedures (circumcision, cystoscopy) before urethral LS developed.

Arena (2018) used uroflowmetry (UF) to assess the outcome of 75 of 180 (41.6%) circumcised boys. Circumcision was followed by 3 months of clobetasol propionate 0.05% ointment.<sup>399</sup> At two weeks, 32 of 75 patients (42.7%) displayed a pathological UF. At six months, 15 patients (20%) had pathological UF and a new cycle of clobetasol was prescribed. At one year, 10 patients (13.3%) had pathological UF and underwent progressive urethral dilatation or meatoplasty. At 18 months, 71 patients (94.7%) displayed regular UF, 3 underwent a meatoplasty and one a staged urethroplasty for a severe urethral stenosis. At two years, UF was normal in 74 out of 75 (98.7%). Therefore, clinical and uroflowmetric follow-up of paediatric patients with LS is mandatory for a prompt identification of post-voiding dysfunction; the application of very potent topical steroids after circumcision in boys seems advantageous, only 13% of patients needed surgical intervention for urethral or meatal stenosis.

## **Surgical intervention in men**

### **Circumcision**

Surgical treatment by circumcision can be curative if the disease is treated early when still localized to prepuce and glans only. Data of 287 men with genital LS were reviewed retrospectively. Complete circumcision led to healing in 276 (92%). Detailed follow-up data is not available, however, the authors state that "mild glans disease may revert to a normal appearance within 6 months, and in more severe cases resolution may continue for up to 2 years after circumcision". The disease remained active in 11 (3.9%) patients requiring glans resurfacing or urethroplasty (the study does not differentiate between boys and men). If LS led to a buried corona with a fusion between foreskin and glans circumcision may be a challenging procedure requiring subtle separation of the adhesions and complete removal of the foreskin (circumcision).<sup>394</sup> Another study of 215 Patients with genital and/or urethral LS reported a 100% cure after circumcision if LS was limited to the foreskin (mean follow-up 65 months, range 12-170 months).<sup>400</sup> Long term follow-up studies have not been performed.

### **Glans resurfacing**

If LS remains active on the surface of the glans after circumcision topical treatment seems to be of limited benefit (Garaffa<sup>401</sup> used only "mild" topical steroids, Depasquale<sup>394</sup> used clobetasol propionate 0.05%). Ongoing LS carries the risk of progressing into the urethra and may lead to severe impairment of sexual and urinary function. Surgical therapy consists in removing the affected skin and replacing it with skin grafts. An alternative technique is laser ablation. Garaffa reported the largest series of patients treated by glans resurfacing, 26 of 31 (84%) operated patients were reported to be "fully satisfied with cosmetic and functional results".<sup>401,402</sup> Resurfacing in cases of persistent glanular LS is successful in the majority of patients.

### **Meatal dilatation, Meatotomy, Meatoplasty**

If meatal stenosis occurs and is strictly limited to the meatal lips meatodilatation, meatotomy or meatoplasty may be successful. Meatotomy by a ventral slit followed by dilatation, however, may lead to a distal hypospadias

deformity as reported in 6 out of 32 LS patients (20%).<sup>403</sup> Some, therefore, prefer meatoplasty (85% satisfactory results reported).<sup>404</sup> Long-term results (10 years) are "excellent".<sup>405,406</sup> Kulkarni reported a success rate of 80% in 15 patients (mean follow-up 59 months, range 12-139 months), but 100% if combined with circumcision (8 patients).<sup>400</sup> If LS spreads to the fossa navicularis the best surgical strategy to assure a high rate of objective and subjective success is not determined. Dilatation and urethrotomy continue to be the most commonly used approaches despite frequent progression of disease with subsequent need of surgical repair. Dilation and urethrotomy may also increase scar formation, thus adding to stricture length and severity, complicating subsequent open repair.<sup>407</sup> A generous ventral meatotomy followed by anti-inflammatory topical treatment may help.<sup>408</sup> But cosmetic results are unsatisfactory as it may produce a hypospadiac meatus and may lead to a splaying micturition. Alternatively, meatoplasty with a dorsal oral mucosa graft is recommended.<sup>408</sup> But both meatotomy and meatoplasty may result in stricture recurrence (20.5% vs 7.5%,  $p=0.04$ ).<sup>409</sup> Comparative results of 93 patients who underwent distal urethroplasty for isolated fossa navicularis and meatal strictures including 42% of patients with LS were reported. Successful reconstruction requiring no further intervention occurred in 84% of patients overall. Subgroup analysis revealed success in 87% of men with simple meatotomy, 75% with meatoplasty and 66% of one-stage reconstruction using a substitute material. Patients with LS showed a significantly greater rate of stricture recurrence (20.5% vs 7.5%,  $P=0.04$ ). Patients who underwent simple meatotomy were investigated by questionnaire and most (84%) were either satisfied or very satisfied with the results and 82% described their outcomes as good or excellent.<sup>409</sup> The involvement of LS in urethral strictures on pathological examination of tissue of 99 male patients was studied. Authors concluded that genital LS with meatal involvement should be considered as a negative prognostic factor as far as proximal urethral involvement is concerned and patients with meatal stenosis require careful follow-up. It was speculated that urinary obstruction caused by distal, meatal or navicularis stenosis may promote epithelisation of the urethral mucosa, creating the basis for LS to diffuse into the remaining tract.<sup>385</sup>

Snodgrass et al. found that 40% of patients who had circumcision for meatal LS (complete excision, including total replacement of the involved urethra) had recurrences of LS at a median of 2 years.<sup>388</sup> Ten of the 12 investigated patients had hypospadias (8 of them prior to surgery). There was one 10 year old boy who developed LS after neonatal circumcision (which is regarded to be very rare) and one 6 year old boy with meatal involvement after circumcision for LS. He responded to topical treatment with clobetasol propionate alone.

## Urethroplasty

Urethroplasty of urethral strictures in LS is a challenging procedure and should only be performed by experienced urethral surgeons. In 1998 Venn presented a study comparing 12 one-stage pedicled penile skin-flap urethroplasties with 16 two-stage free graft urethroplasties using non-genital skin. All patients with pedicle penile skin urethroplasty had a recurrence of LS.<sup>410</sup> Moreover an oral mucosa graft is regarded as the tissue of choice for urethroplasty of urethral strictures in LS.<sup>377</sup> Most commonly used are buccal mucosa grafts from one or both cheeks but mucosal grafts from the inner lips and even the tongue seem also suitable.<sup>411</sup> There are still authors advocating bladder mucosa or even colonic mucosa but this means an abdominal incision to harvest the graft.<sup>412</sup> In 2000 Depasquale et al. presented their 14-year experience and results of about 200 interventions on urethral strictures. They recommended the complete excision of diseased urethra and replacement by a mucosal graft in a two-stage procedure; no recurrences was observed during 1 to 9 years follow-up.<sup>394</sup> In recent years

most data support a more differentiated surgical strategy which consists of ‘one-stage dorsal oral mucosa onlay graft` urethroplasty<sup>384</sup> extending the buccal mucosa grafts to the meatus thus creating a dorsal meatoplasty<sup>413</sup> in selected cases. If the stricture is limited to the penile urethra the procedure can be performed by a circumcoronal incision, de-gloving the penile skin until proximal of the stricture. If the stricture extends beyond the penoscrotal junction (panurethral stricture), a midline perineal approach is used, followed by invagination of the penis as described by Kulkarni et al..<sup>414</sup> Dubey et al. recommend a one-stage dorsal buccal mucosa onlay urethroplasty if preliminary urethroscopy reveals a urethral calibre of more than 6 Fr and the urethral plate is not severely scarred.<sup>413</sup> Kulkarni and Barbagli et al. suggest using this technique as first choice if the following criteria apply:


- age < 70 years
- primary repair
- decreased urinary flow
- histology showing slight or moderate disease, without cancerous or precancerous lesions
- there should only be focal involvement of the glans, penile skin, and meatus
- the urethral plate should be viable or salvageable.

Success rates following this strategy are reported to be 80 - 90% with a mean follow-up of 32 to 58 months.<sup>400,413,415</sup> One reason against the use of grafts (and in favour of flaps, which in LS is problematic) is the poor blood supply of the graft if placed as a ventral onlay. The dorsal onlay graft seems to solve this problem.<sup>416</sup> In older patients (> 70 years), patients with previous multiple failed repairs, severe disease on histology, full involvement of the glans, penile skin and meatus and a scarred urethra a two-stage urethroplasty is recommended.<sup>400,413,415</sup> During the first stage a perineal urethrostomy is made. The urethra is excised and mucosal graft applied. In the second stage the neo-urethra is tubularized, connected with the proximal urethra and uerethrostomy is closed 4-6 months later. Kulkarni and Barbagli strongly suggest leaving the decision as to whether the second stage will be performed to the patient. Many elderly patients and patients with a long history of failed uerthroplasties are tired of multiple operations and may prefer to keep the perineal urethrostomy. But even then, a failure rate of 28% (recurrence, stenosis) is observed. Results of two-stage urethroplasty in accordance with the mentioned criteria have a higher rate of failure than the one-stage procedure, 27 % in penile 2 stage urethroplasty.<sup>400</sup> The discussion concerning the best treatment of urethral stricture in LS is ongoing. Results of long term follow-up (10 years) combined with analysis of quality of life of these patients are awaited.<sup>400</sup>


## 9. Features of extragenital lichen sclerosis


In contrast to genital LS, extragenital disease is much less frequent, it affects approximately 10-20% of patients with LS.<sup>6</sup> It predominantly occurs in women, with a reported female/male ratio of 7:2.<sup>417</sup> Extragenital LS without concomitant genital disease is very rare. Extragenital LS and morphea share clinical similarities, and intraindividual coexistence of both conditions is reported.<sup>418</sup> Clinically, extragenital LS appears as porcelain-like polygonal papules or plaques (Figure 3). Several morphologic variants have been reported for extragenital LS, including bullous, ulcerative, annular, desquamative, teleangiectatic, angiokeratomatous, verrucous, and vitiligoid LS.<sup>417</sup> In bullous extragenital LS, blister formation might be explained by 2 mechanisms. Firstly, stability of the basal membrane zone is disrupted by interface dermatitis-induced liquefaction degeneration of the basal layer. Secondly, oedema of the papillary dermis disrupts the collagen fibres and flattens the rete ridges.<sup>419</sup> The majority of lesions are asymptomatic or accompanied by mild itching. In widespread extragenital LS affecting several anatomical sites, cutaneous atrophy and sclerosis might cause substantial discomfort. Extragenital LS can affect the entire body, but predisposed anatomical sites include the trunk (sub-mammary, abdomen, buttocks, shoulders, wrists, and chest) and proximal extremities.<sup>325</sup> The head (e.g. eyelids, forehead, or scalp) is rarely affected.<sup>420-422</sup> Bullous LS is predominantly located in sites that are prone to trauma, e.g., the belt region. Blister formation in extragenital LS can become haemorrhagic and may lead to superficial erosions and complicating secondary bacterial or fungal infections.<sup>351</sup> The Koebner phenomenon is a recognised feature of extragenital LS. Scarring, trauma, or tattoos have been reported in association with extragenital LS.<sup>423,424</sup>

## 10. Lichen sclerosus in pregnancy


<p>In most women, lichen sclerosus does not worsen during pregnancy and may even improve.</p>	<b>State- ment</b>	<p>&gt;75%</p>  <p>(14/16)<sup>1</sup> Expert Consensus</p>
---	------------------------	--

<sup>1</sup> Abstention

<p>We <b>recommend</b> vaginal delivery in women with lichen sclerosus, unless there are contraindications.</p>	↑↑	<p>&gt;75%</p>  <p>(9/10) Consensus- based</p>
---	----	---

<p>Lichen sclerosus seems not to be associated with impaired post-procedure perineal wound healing.</p>	<b>State- ment</b>	<p>&gt;75%</p>  <p>(14/15)<sup>1</sup> Expert Consensus</p>
---	------------------------	--

<sup>1</sup> Abstention

<p>We <b>recommend</b> maintenance treatment during pregnancy, consisting of a potent TCS, such as mometasone furoate, with the minimum frequency needed to control the disease.</p>	↑↑	<p>&gt;75%</p>  <p>(14/15)<sup>1</sup> Expert Consensus</p>
--	----	--

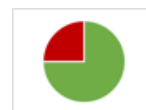
<sup>1</sup> Abstention



We **recommend** careful surveillance in the post-partum period in lichen sclerosus patients to make sure that treatment is continued in active lichen sclerosus.

↑↑

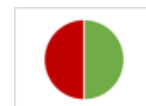&gt;75%

(12/13)<sup>1</sup>Expert  
Consensus<sup>1</sup> Abstention

We **cannot make a recommendation** with regard to the use of topical corticosteroid injection (TCI) during pregnancy and breastfeeding in lichen sclerosus patients.

0

&gt;50%

(12/16)<sup>1</sup>Expert  
Consensus<sup>1</sup> Abstention

### Course of Lichen sclerosus during pregnancy and lactation

Reports on LS course during pregnancy and its effect on delivery are scarce. Trokoudes & Lewis studied prospectively 36 pregnancies in 22 patients with LS. All pregnant women were treated with clobetasol propionate 0.05% ointment, 45% of women reported improvement of LS during pregnancy and needed less topical corticosteroids (TCS), none experienced worsening of LS. There were 33 vaginal deliveries and three Caesarean sections, due to failure to progress during delivery. Episiotomies were performed in nine women, of which three were related to assisted instrumental deliveries, 15 women experienced obstetric tears, none developed LS in the obstetric scar or reported sexual dysfunction during follow-up of up to 4 years.<sup>425</sup> Similarly, in a survey of 45 women with LS, a total of 13 deliveries were reported, of which twelve were vaginal deliveries with episiotomy and one was a Caesarean section.<sup>426</sup>

Also Nguyen et al. report a favourable course of LS during pregnancy, of 33 pregnancies in 29 women, 27 had spontaneous vaginal births, two had instrumental deliveries for standard obstetric indications and four had Caesarean sections, while only one of the latter was performed due to LS related scarring in a non-compliant patient (good compliance was defined as always/mostly following treatment regimens). One woman developed LS in a perineal scar. All women were treated with TCS, their need of TCS did not change during the course of their pregnancies. The authors stress that compliance to treatment during and after pregnancy is crucial to prevent relapses. Relapses only developed post-partum in patients who neglected TCS treatment, likely due to physical and emotional distraction.<sup>427</sup>

A retrospective study by Koltitz et al. evaluated eight pregnant women with LS and reported that 63% were asymptomatic and 25% experienced exacerbation of symptoms during pregnancy. Two patients received no therapy and six were initially treated with TCS, however three of them discontinued treatment due to fear of harming the unborn child. There were three vaginal (two complicated by second-degree lacerations, not known

if related to LS), four Caesarean deliveries (three of them because of obstetrical reasons, one because of unknown reason) and one without documented method of delivery.<sup>428</sup>

Günthert et al. evaluated the effect of oral contraceptives in 40 women with LS, four became pregnant and noted complete remission of LS during pregnancy.<sup>204</sup> Helm et al. showed a variable effect of pregnancy on LS, with half of the LS patients experiencing exacerbation and half improvement of LS symptoms.<sup>429</sup> Rarely LS is diagnosed during pregnancy, Haefner et al. documented two patients with newly diagnosed LS in pregnancy, both women had spontaneous vaginal deliveries.<sup>430</sup> Nothing is known about their medical history, therefore it cannot be judged if LS began before pregnancy. Finally, a population-based case control study demonstrated no difference in number and type of vaginal deliveries, perineal suturing or perineal healing post-delivery between LS patients and the control group.<sup>19</sup>

### **What treatments are available for lichen sclerosus during pregnancy?**

The gold standard for LS treatment is TCS. However, the risk of foetal growth retardation following the regular use of ultrapotent topical steroids by the mother cannot be excluded, therefore women are reluctant to use potent TCS during pregnancy.<sup>431,432</sup> However, studies have shown that even ultrapotent TCS used for prolonged periods to treat LS are safe, because the treated area is small.<sup>59</sup>

Topical calcineurin inhibitors are not licensed for pregnant or breastfeeding women.

Systemic retinoids are severely teratogenic, their use in women of childbearing age is strictly regulated; for safety reasons also topical retinoids must not be used in pregnancy.


Perineal injury and scarring may trigger LS. Long-term effects of perineal injury on LS has not been studied well. The risk of potential injury or episiotomy during vaginal delivery may be reduced by antenatal perineal massage, it should be recommended to all pregnant women independent of the presence of LS.<sup>433</sup>


### **Recommendation for treatment during pregnancy**

There is no objection to occasional use of TCS in genital LS (e.g. once or twice a week), however, potent TCS (e.g. mometasone furoate) are preferred to very potent TCS (clobetasol propionate) during pregnancy.<sup>434</sup>


All other treatments are not recommended during pregnancy and lactation.

## 11. Pain in lichen sclerosus


<p>We <b>recommend</b> considering potential trigger factors for genital pain such as urine exposure or mechanical friction in patients with lichen sclerosus.</p>	↑↑	<p>100%</p>  <p>100 % Agreement</p> <p>(14/14) Consensus-based</p>
--	----	---

<p>We <b>suggest</b> to avoid sexual intercourse if attempts are recurrently painful.</p>	↑	<p>&gt;75%</p>  <p>(11/13)<sup>1</sup> Consensus-based</p>
---	---	---

<sup>12</sup> Abstention

<p>We <b>recommend</b> referral to a pelvic floor physical therapist for patients with complaints due to pelvic floor hypertonia.</p>	↑↑	<p>&gt;75%</p>  <p>(10/11)<sup>1</sup> Consensus-based</p>
---	----	---

<sup>11</sup> Abstention

<p>We <b>recommend</b> referral to a sexologist for patients who experience sexual dysfunction and/or persistent genital pain.</p>	↑↑	<p>100%</p>  <p>100 % Agreement</p> <p>(10/10) Consensus-based</p>
--	----	---

### Introduction

Patients with lichen sclerosus may experience local genital pain due to LS which will have a negative impact on sexuality.<sup>435</sup> Urinary exposure can trigger or worsen pain in patients with LS, just like sexual touching and sexual intercourse. Males with LS having penetrative sex can notice penile pain (dyspareunia). Women with LS having penetrative sex can notice vulval pain (dyspareunia). Painful sexual encounters, especially when recurrent and prolonged can lead to insufficient arousal and/or secondary pelvic floor hypertonia. In males, insufficient arousal

can cause erectile and orgasmic dysfunction. In females, insufficient arousal can lead to insufficient lubrication and orgasmic dysfunction. Chronic pain can lead to a chronic pain syndrome with peripheral (neuroproliferation) and central (neuromodulation) sensitisation, described in women with vulvodynia.<sup>436,437</sup> Secondly, women and men with genital lichen sclerosus report numerous bladder, bowel and pain comorbidities.<sup>438</sup> Characteristically bacterial infection can be excluded and treatment is challenging. It is not known if measures that are taken in interstitial cystitis including laser treatment may be helpful in this LS related bladder pain.<sup>439</sup> Further study of these comorbidities with standardised screening instruments in the LS population is needed. Additionally, practitioners should be cognizant of these associated disorders and consider screening in patients with LS.<sup>71</sup>

Genital pain (either due to active LS or by urinary or physical triggering), sexual dysfunction and pelvic floor hypertonia can maintain or even reinforce each other. Genital pain may be not only associated with somatic aspects but also with psycho/social and sexual dysfunction. Management of genital pain requires not only attention for somatic/pain-medication treatment but also attention for psychosocial and sexual health and attention for pelvic floor muscle rehabilitation.

### **Genital pain in women**

The ISSVD (International Society for the Study of Vulvovaginal Disease) classifies chronic vulval pain<sup>440</sup> in:

- Vulval pain due to somatic disease. This may be vulval pain directly due to active LS and is expected to improve or dissolve on successful treatment of the LS.
- Vulvodynia: non-somatic vulval pain.

The ISSVD emphasises the occurrence of somatic vulval pain in combination with vulvodynia.

In clinical practice two types of vulvodynia are distinguished:

Localised provoked vulvodynia which is more common in young women and which is characterized by longstanding or recurrent pain at (attempt to) coitus/ penetration. When examining these patients localized areas which are (extremely) painful to even minimal palpation are found in the vestibulum. The pelvic floor is hypertonic and can be carefully examined by inspection (ask if the woman is able to contract and relax her pelvic floor muscles) or by outer palpation of the perineal body. Vaginal digital examination - if possible - can confirm hypertonia. Vaginal pelvic floor hypertonia can be a reflex of the vaginal musculus pubococcygeus but can also be more or less permanent and generalized through the whole pelvic floor. This may be associated with problematic defaecation (constipation) and voiding.

Counselling should consist of education about LS and education about requirements for successful intercourse, such as:

- physically healthy vulval and vaginal epithelium which can withstand penile-vaginal friction;
- sexual desire and arousal for lubrication of vulva and vagina; referral to a sexologist may be indicated.
- relaxation of vaginal pelvic floor muscles for compliance enabling the penis to enter; referral to a specialized pelvic floor physical therapist may be indicated.

Generalized spontaneous vulvodynia which is more common in peri- and post-menopausal women and is characterized by chronic (> 3 months) “burning” vulval pain, independent of coitus or palpation. The pain is

neuropathic in presentation, often radiates to the vagina, anal area, abdomen, bladder or thighs, and worsens when sitting on a hard surface. It may be associated with other pain syndromes.

Treatment consists of counselling in combination with medication used for other types of neuropathic pain such as amitriptyline, nortriptyline, gabapentine and pregabalin. Even low doses may be effective.

### **Genital pain in men**

In men genital pain (penodynia) may also be caused by (a combination of) pain due to active LS, irritation of the penile glans by sexual activities, pelvic floor hypertonia and genital dysaesthesia.

To reduce LS related pain, LS treatment should be optimized to achieve a healed epithelium that can withstand friction.

If neuropathic pain is part of the problem, counselling in combination with medication used for other types of neuropathic pain such as amitriptyline, nortriptyline, gabapentin and pregabalin is recommended. Even low doses may be effective.

If pelvic floor hypertonia is part of the problem, the patient should be referred to a specialized pelvic floor physiotherapist.

If sexual desire, arousal and erectile function are part of the problem, referral to a sexologist may be indicated.


## 12. Follow-up

<p>We <b>recommend</b> regular follow-up examinations for lichen sclerosus patients; initially e.g. every 1 to 6 months until the disease has stabilized, and once stable, e.g. once a year.</p>	<p>↑↑</p>	<p>100%</p> <p> 100 % Agreement</p> <p>(15/15) Expert Consensus</p>
<p>We <b>suggest</b> that patients with mild lichen sclerosus could be monitored by general practitioners and through self-monitoring.</p>	<p>↑</p>	<p>&gt;75%</p> <p> &gt;75% Agreement</p> <p>(15/16) Expert Consensus</p>
<p>We <b>recommend</b> that all children with lichen sclerosus are followed by a specialist with expertise in treating lichen sclerosus.</p>	<p>↑↑</p>	<p>100%</p> <p> 100 % Agreement</p> <p>(15/15) Expert Consensus</p>
<p>We <b>recommend</b> that all adult lichen sclerosus patients who do not respond to treatment with potent topical steroids or who have precancerous lesions of the vulva or penis are followed by specialists, e.g. dermatologists, gynaecologists or urologists.</p>	<p>↑↑</p>	<p>100%</p> <p> 100 % Agreement</p> <p>(15/15) Expert Consensus</p>
<p>We <b>recommend</b> that lichen sclerosus patients with voiding problems are referred to an appropriate specialist, such as a urologist or urogynaecologist.</p>	<p>↑↑</p>	<p>100%</p> <p> 100 % Agreement</p> <p>(15/15) Expert Consensus</p>

For the follow-up of lichen sclerosus patients, we **recommend** the following:

- monitor treatment effectiveness (including symptom relief/control, normalisation of skin colour and texture),
- ask about problems in voiding, defaecation and sexual function,
- monitor for the development of precancerous or cancerous lesions,
- ensure adherence to treatment.


↑↑

100%  
  
100% Agreement  
(15/15)  
Expert  
Consensus

We **recommend** that patient education includes

- recognition of lichen sclerosus changes that point towards disease progression or cancer development (ulceration, non-healing lesions, papules, wart-like lesions),
- information about the importance of adherence to treatment to help prevent disease progression,
- avoidance of trigger factors,
- awareness of symptoms of autoimmune diseases (e.g. thyroid disease).

↑↑

>75%  
  
>75% Agreement  
(13/14)  
Expert  
Consensus

Lichen sclerosus (LS) has a potential for spontaneous or treatment related remission but can, if untreated, progress to irreversible structural changes in the affected anogenital site, including resorption of labia minora, agglutination of the clitoral hood, phimosis, stenosis of introitus vaginae and meatus urethrae or stricture, and patients with LS have a risk of developing squamous cell carcinoma. Gold standard of treatment for LS are potent topical steroids. Follow-up is needed for the evaluation of the treatment effect, compliance, disease progression, side effects of the treatment and signs of (pre-) cancerous lesions.

### **Clinical examination and frequency**

Structural changes of the affected anogenital skin is one main concern in LS patients as these changes may lead to female and male dyspareunia and micturition disorders.<sup>195,441,442</sup> The clinical examination at the first visit should ideally include a clinical photo as a starting point for comparison in follow-up visits.

Treatment early in the disease course can induce symptom relief/control, normalize the skin colour and texture especially in children<sup>87,443-445</sup>, whereas in longstanding disease where scarring occurred the treatment goal is symptom control, reducing progression of scar formation and screening for squamous cell precancer and cancer.<sup>59</sup> A close follow-up is needed in the early stage preferably within 3 months after the initial consultation to ensure treatment efficacy, potential side effects (atrophy due to topical steroids, irritant or allergic reactions)

and compliance.<sup>59</sup> A large prospective study of 507 women with vulval LS, showed that almost 30% of the women were only partially compliant to treatment. Significantly more of these partially compliant woman showed vulval adhesions or scarring compared with treatment compliant women.<sup>59</sup> Likewise two studies in prepubertal girls assessing the benefit of adherence to long-term treatment showed that a high percentage of girls achieved complete disease suppression in contrast to girls who did not adhere to long-term treatment.<sup>59,443</sup> These studies underline the importance of treatment and compliance to treatment. The goal of treatment has to be explained at follow-up visits and the supply of treatment must be guaranteed. Follow-up also includes inquiries about changes in miction, defaecation and sexual function. Change in defaecation can lead to constipation. If changes in miction/voiding are reported the patient should be referred to a urologist or urogynaecologist. The urological investigation should include a uroflowmetry. If this shows an obstructive pattern or the patient has a clear meatal stenosis, a retrograde urethrogram should be performed to exclude a distal urethral stricture (lichen?) or another pathology responsible for the urological symptoms. Early treatment of inhibited micturition will prevent further complications.<sup>446</sup>

After the initial follow-up LS patients should be seen regularly, e.g. every 3-6 months for 2 years and if the disease is stable follow-up visits may be scheduled once a year.<sup>59</sup> Mild LS in adults might be followed up by the general practitioner or local gynaecologist, next to self-monitoring. All children with LS and adults unresponsive to treatment with a potent topical steroid or if vulval or penile precancer or cancer is an issue should be followed up by a specialist, specialized in anogenital skin diseases.


For decades a common perception was that LS would remit at puberty, but this has since been challenged and remission of LS in childhood might be determined more by early successful treatment than by hormonal factors.<sup>444,445</sup> We do not know in how many children with LS the disease will continue in adult life. Current data suggests that even if remission has occurred in childhood or puberty, follow-up in adult life should be ensured, at least in females.<sup>447</sup>

LS may be associated with a number of diseases, namely autoinflammatory diseases in women (see chapter 1 introduction, section on associated diseases).



### 13. Patient Education Programs

<p>We <b>recommend</b> that patients are educated and followed up by a physician experienced in lichen sclerosus.</p>	<p>↑↑</p>	<p>100%</p> <p> 100 % Agreement</p> <p>(16/16) Expert Consensus</p>
<p>We <b>recommend</b> that lichen sclerosus patients are guided and supported in dealing with lichen sclerosus in daily life and sexual health.</p>	<p>↑↑</p>	<p>100%</p> <p> 100 % Agreement</p> <p>(15/15) Expert Consensus</p>
<p>We <b>recommend</b> that lichen sclerosus patients are made aware of patient organisations and their offers, if available.</p>	<p>↑↑</p>	<p>100%</p> <p> 100 % Agreement</p> <p>(16/16) Expert Consensus</p>
<p>We <b>recommend</b> that lichen sclerosus patients receive information regarding the anatomy of the affected sites.</p>	<p>↑↑</p>	<p>100%</p> <p> 100 % Agreement</p> <p>(16/16) Expert Consensus</p>
<p>We <b>recommend</b> providing e written information and online information, e.g. information brochures or flyers to lichen sclerosus patients.</p>	<p>↑↑</p>	<p>100%</p> <p> 100 % Agreement</p> <p>(16/16) Expert Consensus</p>
<p>We <b>recommend</b> that lichen sclerosus patients are specifically educated about the benefits and safety aspects of each treatment option proposed.</p>	<p>↑↑</p>	<p>100%</p> <p> 100 % Agreement</p>

		<p>(16/16) Expert Consensus</p>
<p>We <b>recommend</b> that lichen sclerosus patients are motivated and guided to perform self-examinations.</p>	<p>↑↑</p>	<p>100%  (16/16) Expert Consensus</p>

LS is a chronic disease which can have significant complications that affect quality of life including sexuality. It is necessary for patients to be educated so that they can effectively manage their condition. Patient organizations meet these needs for some patients; a new development are patient education programs offered at hospitals. We recommend the following minimum standard of patient education:

**Minimum standard of patient education**

Information and guidance for patients with LS is important and indispensable and should be continued throughout diagnosing and treating LS. There will be different phases with different accents, repeated information helps to understand what happens.

- **Diagnosis.** Usually, the LS diagnosis is made by a physician taking the patient’s history and examination.
  - o When examining the patient, always provide the patient a hand mirror so that you examine the anogenital area together, and explain what you see: signs/changes caused by LS.
  - o At the time of diagnosis most patients are overwhelmed and not able to focus and concentrate. Explain at least: LS is a chronic, inflammatory disease, affecting mainly the anogenital site. The gold standard of treatment are topical corticosteroids.
  - o A short-term follow-up appointment after diagnosing will give the patient a chance to pose further questions and supports compliance. Offer the patient to bring an accompanying person to the appointment.
- **Anatomy.** Most patients don’t know much about the genital anatomy. In order to treat themselves properly, patients need to get informed about their anogenital region.
  - o Male patients: Mostly the foreskin, frenulum, glans and urethral opening are affected; in rarer instances the urethra. Explain that the foreskin and the meatus can become tight causing problems when urinating and during sexual activities. Use a drawing or picture to explain.
  - o Female patients: Make a drawing of the vulva and explain the different parts, such as labia minora and majora, urethral opening, clitoris and clitoral hood, introitus and hymenal parts, perineum and anus; see chapter 6 of the guideline. Explain that the clitoris can become covered by the clitoral hood. Show a drawing of the clitoral body and explain, that most of the clitoral complex is internal, and that sexual stimulation of the clitoris remains possible.
- **The disease LS.** Every patient needs to be informed and educated about symptoms and signs of LS, potentially irritating factors (cleaning habits, cloths, micturition/voiding, defaecation, and intercourse), the

chronic nature of LS, the potential progression of the disease, and the importance of self-examination. So, it is important to explain to every patient:

- The most frequent anogenital complaints are itching in females and pain in males.
  - Skin in anogenital LS can become fragile, eroded, thickened, and/or sclerotic and may bleed.
  - Urination and defecation can be(come) painful (irritating). Rinsing with a bottle of water during urination will dilute the urine and make urination more comfortable.
  - Alternatively the skin may be protected with some greasy ointment, e.g. Vaseline, before urination, defaecation or taking a shower etc.
  - Hypertonia of the pelvic floor muscles as a result of pain can worsen micturition/defaecation and sexual penetration in females.
  - Avoiding mechanical triggers like tight clothing or hard bicycle saddle can help to reduce the pain.
  - Provide written information, for example information leaflets from patient organisations.
  - Point out meaningful websites\*with information from a patient association.
- **Treatment of LS.** LS seems to be rather under- than over treated.<sup>448</sup> With the help of good information and education about the use of topical corticosteroids (TCS) adherence to therapy can be promoted. Inform your patient about the following:
- Potent or ultrapotent TCS (see chapter treatment) are the first-choice treatment to suppress inflammation. Treatment with TCS, is recommended to be used long term, a single of treatment is not sufficient.
  - Point out that the warning of side-effects in the instruction leaflet of TCS may be ignored in the treatment of LS.
  - Half a fingertip of potent or ultrapotent TCS is sufficient, this must be applied to all sites that are affected by LS.
  - Daily use of greasy ointments, in particular in females, is necessary to protect the skin (as often as desired, but at least once a day). Explain about different types of emollients and let the patient find out what works best for her/him.
  - LS is a chronic disease which needs long-term treatment and follow-up.
- **Self-examination of the anogenital skin.** The patient needs to know what is healthy and what diseased skin, so tell the patient:
- Regular inspection of their anogenital skin, if necessary by using a hand mirror or taking a photo of the anogenital skin with a mobile phone, is necessary to observe any possible change. A physician should be seen in case suspicious changes are noticed (e.g. wounds that won't heal, thickened skin that doesn't resolve).
- **Quality of Life (QoL).** Anogenital LS may influence the QoL, affecting daily life like work, social activities, partnership or sexuality.<sup>449,450</sup> So inquire if patients experience any problems in daily life, ideally by introducing as follows:
- “We know from other patients and studies that LS can cause problems in (quality of) life. Are there things you would like to ask or discuss? E.g. changes in mood, sleeping problems, anxiety, depression, suicidal thoughts?”
  - “Does your partner have any questions/concerns?”
  - “Would you like more support, such as a referral to a psychologist or sexologist?”
  - Inform about national patient organisations, if available.

- **Sexuality/ sexual health.** Anogenital LS may influence sexuality because of the location of the disease in the anogenital site and the changes caused by LS. So inquire if patient experience any problems or have any questions concerning their sexuality and explain and inform as follows:

**For females:**

- Labia minora may become shorter, disappear and may fuse; the clitoral hood may cover the clitoris. These changes may lead to a narrowed introitus, in addition the skin may become tight and intercourse can become painful or impossible.
- Unaroused intercourse should (always) be avoided; sexual desire and arousal/lubrication and relaxation of the pelvic floor muscles is required.
- Lubricants - preferably hypoallergenic, e.g. silicone based or petroleum based (white soft paraffin, Vaseline, glycerine) - and change of coitus position can help. Do not use emollients containing petroleum jelly in combination with condoms, because that reduces their reliability.
- Fused labia/clitoral hood over the clitoris do not directly cause problems reaching orgasm; but can reduce arousal due to fear and/or pain and result in problems reaching orgasm. A flat vibrator may be helpful for soft external stimulation to enhance vulval blood flow.
- A risk of ongoing painful intercourse can be sensitisation/hypersensitivity of the vulva and hypertonicity of the pelvic floor muscles.
- There is little evidence if stretching of the introitus (with fingers, dilators or penetrative sex) will harm and lead to worsening of LS (Koebner phenomenon) or if stretching will prevent narrowing of the introitus in the long-term.
- An alternative for painful coitus is non-coital sex. Inform that women (and their partner) can make the choice to give up intercourse; if feelings of guilt or shame hamper that decision, point at possibility of guidance by sexologist or medical psychologist.
- Surgical intervention is only applied if structures are fused and cause substantial problems. LS in females cannot be cured by surgery and recurrences are frequent!

**For males:**

- Friction of foreskin, glans and urethral opening can become painful during manual, oral and penetrative sex. Ejaculation can be irritating if the urethra is affected by LS. Lubricants and/or condoms can help. Lubricants/emollients containing petroleum jelly in combination with condoms reduces their reliability.
  - Urine is thought to be an important trigger in LS, therefore men are advised to remove the last urine drop after urination carefully and possibly protect the skin with greasy emollients before and after urination.
  - Surgical interventions, like circumcision, is recommended if topical treatment fails. This needs to be discussed with a specialized physician.
  - Ask the patient: Do you want (more) support or a referral to a psychologist or sexologist? (You may have some colleagues you can refer to because it is often difficult to find such specialists.)
- **Referral.** Because of the impact of LS on quality of life and sexuality, the patient (and partner) should be informed about the possibility of guidance/treatment and may be referred to a specialist like psychologist (in case of problems like shame, guilt, depression), sexologist (in case of sexual problems) or pelvic physiotherapist (in case of pelvic floor hypertonia.)

- Patients need to have easy access to a list of physicians who are familiar with LS, free contact information on the internet should be made available to all patients.

**\*Websites**

[www.lichensclerosus.ch](http://www.lichensclerosus.ch)

[www.lichensclerosus.dk](http://www.lichensclerosus.dk)

[www.lichensclerosus.nl](http://www.lichensclerosus.nl); <https://redvulva.nl/de-vulva/>; <https://www.lsnederland.nl/folder-vulvaonderzoek-binnenkant-06-05-2021-3-2/>

[www.lichensclerosus.org](http://www.lichensclerosus.org)

**Lichen sclerosus patient organizations**

Austria: [www.lichensclerosus.at](http://www.lichensclerosus.at)

Denmark: [www.lichensclerosus.dk](http://www.lichensclerosus.dk)

France: [www.lichensclereux.fr](http://www.lichensclereux.fr)

Germany: [www.lichensclerosus-deutschland.de/home](http://www.lichensclerosus-deutschland.de/home); [www.verein-lichensclerosus.de](http://www.verein-lichensclerosus.de)



Italy: [www.lisclea.it](http://www.lisclea.it)

Netherlands: [www.lsnederland.nl/](http://www.lsnederland.nl/)

Switzerland: [www.lichensclerosus.ch](http://www.lichensclerosus.ch)

United Kingdom: [www.lichensclerosus.org](http://www.lichensclerosus.org) (no membership fee or annual meetings, only a website with information)

## 14. Interdisciplinary management

<p>We <b>recommend</b> a referral to a specialist, for example:</p> <ul style="list-style-type: none"> <li>- if no adequate improvement of signs and symptoms after adequate treatment is observed;</li> <li>- if there are complications that require specialized approaches, such as functional impairment requiring surgical treatment or chronic pain syndromes requiring care by a pain specialist;</li> <li>- if psychological support is needed;</li> <li>- if sexological support is needed.</li> </ul>		<p style="text-align: center;">100%</p> <div style="text-align: center;">  <p>100% Agreement</p> </div> <p style="text-align: center;">(13/13) Expert Consensus</p>
---	---	--

### When should patients be referred to another specialty or a physician specialized in LS?

LS affects the skin and anogenital mucosa in men and women, adults and children. Thus, LS occurs in a diverse population (men, women, adults and children) and has a huge impact on physical and psychological health because of the involvement of the anogenital site, the chronicity of the disease and complications that may occur.<sup>185,451-454</sup> The care of patients with LS is, therefore shared between general physicians, paediatricians, dermatologists, gynaecologists, urologists, paediatric surgeons, psychologists, sexologists and physiotherapists. However, not each physician is equally familiar with LS in particular if complications occur. A multidisciplinary approach is mandatory in order to achieve adequate care and a referral is recommended:

- if a physician is not familiar with inflammatory anogenital diseases, e.g. LS,
- if no adequate improvement of signs and symptoms after adequate treatment is observed,
- if there are complications that relate to other specialties, e.g. patients, seen by dermatologists, who need specialized surgical intervention because of anal, meatal, urethral or introital strictures or patients seen by urologists who have not had adequate topical treatment for LS may be referred to a physician specialized in topical medical treatment (e.g. dermatologists / gynaecologists),
- if transition to adult medicine is necessary,
- if psychological and/or sexological support is needed.

### Is there a need for interdisciplinary clinics?

Interdisciplinary clinics for the care, with an integrative approach, of patients with anogenital LS exist in several countries, e.g. in the Netherlands, Denmark, and the United Kingdom <https://bssvd.org/>.<sup>455</sup> This means that physicians of different specialties see the patient simultaneously during a consultation.

However, interdisciplinary clinics are costly and should therefore be reserved for special circumstances.



In favour of interdisciplinary clinics is a more comprehensive management, a) giving the possibility to discuss potential options of care in case the disease is about to lead or already led to complications like strictures, cancer etc. and b) the possibility to provide a summarized, less conflicting information for patients. As a result, they

may even be cost-saving if handled with care. We see the need for interdisciplinary clinics in the following situations to discuss the diagnosis, therapeutic approach and follow-up:

- if no adequate improvement occurs despite optimal treatment,
- to clarify special issues e.g. sexual abuse,
- if complications like strictures causing problems with urination or intercourse and
- if cancer development is an issue.

Ideally patients in these special situations are seen in an interdisciplinary clinic, however, if this is not possible due to local circumstances, an interdisciplinary referral needs to be arranged.

## 15. Improvement of care

<p>We <b>recommend</b> raising awareness in the general population about lichen sclerosus.</p>	↑↑	<p>100%</p>  <p>100 % Agreement</p> <p>(14/14) Expert Consensus</p>
<p>We <b>recommend</b> raising awareness among health care professionals about lichen sclerosus.</p>	↑↑	<p>100%</p>  <p>100 % Agreement</p> <p>(14/14) Expert Consensus</p>
<p>We <b>recommend</b> that specialists document the signs and symptoms well, ideally taking a photo whenever required, and informing their colleagues to whom a referral is made of their findings.</p>	↑↑	<p>100%</p>  <p>100 % Agreement</p> <p>(13/13) Expert Consensus</p>
<p>We <b>recommend</b> that a list of physicians with experience in lichen sclerosus is made available to patients and referring doctors.</p>	↑↑	<p>&gt;75%</p>  <p>(12/13) Expert Consensus</p>

### Current situation:

LS patients experience large differences in their care:

Some patients are seen at departments of Gynaecology or Dermatology at hospitals that may or may not be specialized in LS, others are seen by their gynaecologist or dermatologist, again who may be or not specialized in LS, and others are seen by their general practitioner.

However, many physicians do not know the disease or they do not have enough knowledge of the care of the disease. There is therefore a delay in making the diagnosis possibly leading to complications of LS (scarring / cancer development). This lack of knowledge also creates insecurity and anxiety in patients.

Access to physicians specialized in LS would help to diagnose the disease early and help the patient to better understand and treat their disease, this also improves compliance.



**Conclusion “awareness & education”:**

The general population needs to be educated about the existence of LS to recognize signs and symptoms early so LS can be treated as early as possible. Early treatment may prevent scar formation and cancer development.<sup>59</sup>

Physicians need to be educated about LS to recognize signs early and be able to initiate treatment as early as possible. In doubt, they need to refer patients to a specialist in LS.

Specialists should document signs and symptoms well, ideally take a photo in the beginning, and inform colleagues about their findings (including a photo) to guarantee support in care and educate.

Long waiting times for visits to specialists for LS could be bridged by educating general practitioners and local specialists.

A list of physicians specialized in LS should be made widely available to patients and referring physicians.

**The ideal scenario** is an interdisciplinary team or a LS centre with a team of specialists, including gynaecologists, dermatologists, urologists, physiotherapists, psychologists and sexologists, depending on the individual need of the patient, to provide individualized advice of care.

**Need:** Studies that evaluate the effect of care by specialists vs. non-specialists; the effect of interdisciplinary clinics on care and economic implications.

Interdisciplinary team: gynaecology, dermatology, urology, paediatric surgeon, specialized pathologist / dermatopathologist, general practitioner, psychologist / sexologist, pelvic floor therapist.

## 16. Future research

In a James Lind Alliance Priority Setting Partnership physicians and patient representatives determined the “Top 10 uncertainties” to be addressed in future research.<sup>456</sup> The list below is based on identified uncertainties and is complemented by additional important research questions.

### Important research questions:

#### Diagnosis

- What is the best way to diagnose lichen sclerosus?
- On what criteria should the diagnosis be based upon?

#### Pathophysiology

- What is the precise pathomechanism in LS?
- Is LS an autoimmune disease?<sup>195,457</sup>
- Developments of *in vivo* and *in vitro* models of LS (such as already available for psoriasis<sup>458</sup> or atopic dermatitis<sup>459</sup>) are needed for translational research.
  - Such models could be crucial to deepen the understanding of the disease mechanisms in LS and to identify novel therapeutic targets.
- What are the pathophysiological similarities and differences between LS and lichen planus?
  - Why do some patients have an overlap between LS and lichen planus?
  - Does overlap between LS and LP exist or has an individual patient only one disease, how to define overlap between LS and LP?
  - Will anti-inflammatory treatments investigated for lichen planus (e.g. apremilast, JAK inhibitors or anti-IL-17 antibodies, see Chapter 10) and morphea (clinical trial using Dupilumab) be candidates for the treatment of LS?

#### Risk factors

- What are potential risk factors or triggers for LS?<sup>20</sup> (see also chapter 6)
  - Can their avoidance prevent the development or progression of the disease?
  - Is there a link between microbiota and LS?<sup>460</sup>

#### Genetics

- Genetic sequencing studies are needed to determine if there is a genetic link

#### Gender and age differences

- Is the pathomechanism of LS the same in men and women, children and adults?
- Can treatment recommendations be adopted from one sex to another and from adults to children?<sup>211,461</sup>

#### Cancer

- Why is LS associated with an increased risk of genital cancer?

- How to detect LS patients with increased cancer risk?
  - What are predisposing factors for the development of genital carcinomas in LS patients?
  - Are there reliable early clinical indicators that suggest the development of cancer in LS patients?
  - Are there early features, e.g. histopathological and detectable precursor markers (e.g. p53, Ki-67) for malignant transformation?<sup>462,463</sup>
- How can the risk of genital cancer development be decreased in genital LS?
- Can adequate therapy reduce the risk of cancer development in LS patients?<sup>59</sup>

### Course of LS

- How to avoid anatomical changes, which often lead to a poor sexual life and have an high impact on quality of life
- Are there distinct patterns of LS or is there only one "LS"? E.g. are hypertrophic variants, genital / extragenital LS / scarring / non-scarring LS all the same disease?
- How often does LS in children (boys and girls) persist in adulthood?
- Should all children with LS be followed up in adulthood and for how long?
- Does it make sense to stage LS and is there a histological and clinical correlation of the changes?<sup>464</sup> Or is it better to just describe the clinical changes and their progression in a defined and systematic manner, as outlined in Kirtschig & Cooper p.26, Figure 5.1.<sup>94</sup> and Meuli 1994 describing the progression of penile changes.<sup>81</sup>

### Treatment

- More randomized controlled trials are needed to determine if new treatment options are effective and in whom. This concerns in particular the following treatment options:
  - Oral Doxycycline (see chapter triggering factors and chapter 8.8))
  - Adipose tissue stromal vascular fraction<sup>310</sup>
  - Energy-based modalities such as the fractional CO2 laser treatment (see chapter 9.6)
  - Treatment with Polydeoxyribonucleotide<sup>465</sup>
  - Platelet rich plasma<sup>466</sup> (see also chapter 9.3)
  - Photodynamic therapy (see chapter 9.5)
  - High intensity focused ultrasound
  - Hyaluronic acid applications / combined with oxygen.<sup>467</sup>
  - Biologics (e.g. TNF alpha inhibitors) and small molecules (e.g. Apremilast (Phosphodiesterase-4-Inhibitor), Janus kinase inhibitors, topical JAK inhibitors, Dupilumab anti-IL-4/ IL-13, Tralokinumab anti-IL-13, Nemolizumab IL-31RA, Rituximab anti-CD 20, anti-IL-17, anti-IL-31 ) which might possibly interfere with the pathophysiology of LS (see chapter 9.8)
- Cold atmospheric pressure plasma.<sup>212,468</sup> Are there key mediators that could potentially be targeted therapeutically?<sup>195</sup>
- When, in whom and what surgical treatments should be offered for LS?
- Is it necessary to continue treatment for patients with LS who do not have any symptoms and/or signs of disease activity?

A randomised controlled trial is underway that addresses this question

<https://www.fundingawards.nihr.ac.uk/award/NIHR135121>

- MC2 Therapeutics has patented and initiated development of drug candidates for chronic kidney disease associated pruritus (stages 3-5) and lichen sclerosus. The pathogenesis of genital LS is possibly driven by chronic urine exposure leading to nerve changes and skin damage caused by carbamylation. A leading drug candidate is an effective isocyanate scavenger demonstrating >90 % inhibition of protein carbamylation and counteracting the morphological skin changes induced by carbamylation. This may offer new treatment approaches. [https://www.prnewswire.com/news-releases/mc2-therapeutics-announces-breakthrough-discovery-with-the-potential-to-help-millions-of-people-suffering-from-urea-associated-skin-diseases-301615674.html?tc=eml\\_cleartime](https://www.prnewswire.com/news-releases/mc2-therapeutics-announces-breakthrough-discovery-with-the-potential-to-help-millions-of-people-suffering-from-urea-associated-skin-diseases-301615674.html?tc=eml_cleartime).
- What role does complementary therapy play in LS? Many forms of alternative medicine are offered to patients, however, they are usually not well investigated and must not replace gold standard treatment. Aromatherapy, using e.g. essential oils and other aroma compounds, is such an attempt, however, there are no studies available that support its benefit in the treatment of LS. Well-designed studies are needed.

#### **Core outcome set**

- There is a lack of standardised, mandatory outcomes that are recorded by all clinical trials and therefore trial results are not comparable in meta-analyses. The development of a core outcome set (COS) has been initiated<sup>456</sup>. Outcomes consist of 'domains' (what to measure) and 'instruments' (how to measure). Consensus was met in 2022 for the domains '*quality of life – LS specific*', '*symptoms*' and '*clinical (visible) signs*', this needs to be further developed.<sup>469</sup>
- [www.nottingham.ac.uk/go/CORALS](http://www.nottingham.ac.uk/go/CORALS)

#### **Patient care**

- When do we need an interdisciplinary approach in the care of LS? (see also chapter 15)
- How to organize the transition of affected children to adult medicine after puberty<sup>461</sup>?
- How to reduce the diagnostic delay in LS<sup>190</sup>?
- Awareness: How to best inform patients, clinicians and nursing staff about LS?

## 17. Upcoming treatments

In the past decade, the advent of biologics (e.g. TNFalpha inhibitors, anti-IL-2, -4, -12, -13, -17, -22, -23, -36, and IgE directed therapies) and small molecules (e.g. apremilast, janus kinase (JAK) inhibitors) changed the treatment of inflammatory skin diseases such as psoriasis, atopic dermatitis or chronic urticaria fundamentally. Some of these new drugs have also been used off label in other inflammatory skin conditions with promising effect including mucosal lichen planus (LP).<sup>1-6</sup>

Costs and adverse effects have to be considered, but higher costs may be justified in conditions which cause irreversible scarring and impact significantly on quality of life. It still needs to be established if such treatments have an effect on cancer development in mucosal LP.

However, these novel drugs have not been studied in LS, indicating both an unmet need and an unexplored large therapeutic potential with marketed drugs.

Therefore, the use of these drugs in LS can currently not be recommended. However, an off label use of topical or systemic JAK inhibitors, apremilast or tildrakizumab, may be justified in patients with vulval LS provided they suffer from an overlap with mucosal lichen planus.

According to [clinicaltrials.gov](https://clinicaltrials.gov) (April 2022), no clinical trials on systemic treatments in LS are planned, ongoing or completed. The majority of trials listed in this register deal with laser-based techniques or topical treatments, mainly corticosteroids or topical calcineurin inhibitors. Several ongoing or completed trials are on autologous platelet rich plasma, photodynamic therapy and UVA1 in vulval LS. These trials are important, as they will help to increase the still low evidence of these treatment modalities in LS. Remarkably, to date there is no study registered on [clinicaltrials.gov](https://clinicaltrials.gov) addressing male LS, paediatric LS or extragenital LS, highlighting the need for coordinated multi centre initiatives to conduct studies including all LS populations.

### **Lichen sclerosus on [clinicaltrials.gov](https://clinicaltrials.gov), searched in April 2022**

N=35 (of which four were also for other vulval diseases)

- Biomarkers in vulval LS
- Mona Lisa Touch Laser vs. Clobetasol in VLS (completed)
- Injection of autologous fatty tissue associated with autologous platelet rich plasma (completed)
- Fractional CO<sub>2</sub> plus PDT in VLS
- VLS influence on quality of life (completed)
- Nd:YAG laser vs. topical betamethasone in VLS
- Microbiome in postmenopausal VLS
- CO<sub>2</sub> Laser plus topical steroids vs. topical steroids only in VLS n=3 (completed)
- Platelet rich plasma for VLS n=2 (completed)
- Clobetasol propionate vs. PDT and vs. low intensity laser in VLS (completed)
- 2940 nm fractional laser for VLS
- Fractional CO<sub>2</sub> in VLS n=3 (two completed)
- Rivelin plain patches in VLS (completed)
- Vulval scarring grading scale for LS (completed)
- Progesterone vs. clobetasol propionate in VLS (completed)
- Clobetasol propionate vs. UVA1 in VLS (completed)

- Clobetasol vs. pimecrolimus for VLS (completed)
  - Clobetasol propionate vs. tacrolimus (completed)
  - Dual laser for VLS (completed)
  - AI temperature-controlled radiofrequency technology and electrical stimulation in vulval leukoplakia/VLS
  - Low level laser to improve quality of life in VLS (completed)
  - Early detection of vulval cancer through self-examination (EDuCATE) Intervention Study
  - Ruxolitinib Cream (JAK inhibitor) NCT05593445 (recruiting)
- 
- Most studies are on laser based treatments and topical treatments (corticosteroids, topical calcineurin inhibitors).
  - NO study on male LS
  - NO study on paediatric LS
  - NO study on systemic treatment

A further issue is the delayed diagnosis of LS. This often leads to therapeutic delay and development of scarring and genital cancer. A study is underway that aims to develop the digital recognition of LS supported by artificial intelligence <https://www.wohlva.ch/>. A cell phone application will offer digital recognition of LS; it will then give stratified recommendations. This may reinforce patients who are ashamed of their genital problem to seek professional medical help rather sooner than later.

## **X. Strengths and limitations**

The vision of this guideline was to provide a comprehensive evidence-based up-date on all aspects of LS care with high relevance to the practising clinicians.

The formal structure of the guideline document has been changed to follow the structure and style of the EuroGuiDerm guidelines, this reflects the latest methodological rigour in guideline development.

We assembled a guideline development group (GDG) that included clinical and methodological experts from across Europe, including patients. Our clear conflict of interest policy has created more transparency.

The biggest drawback of this guideline is the lack of randomized controlled trials performed in LS. Topical corticosteroids remain the gold standard, however, in recent years, interest in LS increased and new treatment approaches are in development, this may mean that this guideline will soon be outdated.

## **XI. Acknowledgements**

The authors like to thank the physicians and specialists who contributed to the development of this guideline. We especially thank the British Association of Dermatologists for providing the data from their systematic review. They kindly agreed to utilize and update this data, which formed the evidence base for our guideline.

## XI References

1. Kirtschig G, Happle R. [Lichen sclerosus et atrophicus of the vulva. Successful local treatment with a potent corticosteroid]. *Gynakologe*. Jun 1994;27(3):181-2. Lichen sclerosus et atrophicus der Vulva. Erfolgreiche Lokalbehandlung mit einem potenten Kortikosteroid.
2. Schünemann H, Brożek J, Guyatt G, Oxman A. *GRADE handbook for grading quality of evidence and strength of recommendations*. Updated October 2013 ed. The GRADE Working Group; 2013.
3. Green C, Guest J, Ngu W. Long-term follow-up of women with genital lichen sclerosus. *Menopause Int*. Mar 2013;19(1):28-29. doi:10.1177/1754045312472861
4. Balasubramaniam P, Lewis FM. Long-term follow-up of patients with lichen sclerosus: does it really happen? *J Obstet Gynaecol*. Apr 2007;27(3):282. doi:10.1080/01443610701251539
5. Cooper SM, Gao XH, Powell JJ, Wojnarowska F. Does treatment of vulvar lichen sclerosus influence its prognosis? *Arch Dermatol*. Jun 2004;140(6):702-6. doi:10.1001/archderm.140.6.702
6. Powell JJ, Wojnarowska F. Lichen sclerosus. *Lancet*. May 22 1999;353(9166):1777-83. doi:10.1016/s0140-6736(98)08228-2
7. Arnold S, Fernando S, Rees S. Living with vulval lichen sclerosus: a qualitative interview study. *Br J Dermatol*. Dec 2022;187(6):909-918. doi:10.1111/bjd.21777
8. Ranum A, Pearson DR. The impact of genital lichen sclerosus and lichen planus on quality of life: A review. *Int J Womens Dermatol*. Oct 2022;8(3):e042. doi:10.1097/jw9.0000000000000042
9. Commission E, Research D-Gf, Innovation, et al. *Scoping study on evidence to tackle high-burden under-researched medical conditions : discussion paper*. Publications Office of the European Union; 2023.
10. Neill SM, Lewis FM, Tatnall FM, Cox NH. British Association of Dermatologists' guidelines for the management of lichen sclerosus 2010. *Br J Dermatol*. Oct 2010;163(4):672-82. doi:10.1111/j.1365-2133.2010.09997.x
11. Niamh L, Naveen S, Hazel B. Diagnosis of vulval inflammatory dermatoses: a pathological study with clinical correlation. *Int J Gynecol Pathol*. Nov 2009;28(6):554-8. doi:10.1097/PGP.0b013e3181a9fb0d
12. Fung MA, LeBoit PE. Light microscopic criteria for the diagnosis of early vulvar lichen sclerosus: a comparison with lichen planus. *Am J Surg Pathol*. Apr 1998;22(4):473-8. doi:10.1097/0000478-199804000-00013
13. Day T, Wilkinson E, Rowan D, Scurry J. Clinicopathologic Diagnostic Criteria for Vulvar Lichen Planus. *J Low Genit Tract Dis*. Jul 2020;24(3):317-329. doi:10.1097/igt.0000000000000532
14. Attili VR, Attili SK. Clinical and histopathological spectrum of genital lichen sclerosus in 133 cases: Focus on the diagnosis of pre-sclerotic disease. *Indian J Dermatol Venereol Leprol*. Nov-Dec 2022;88(6):774-780. doi:10.25259/ijdv1\_640\_20
15. Derrick EK, Ridley CM, Kobza-Black A, McKee PH, Neill SM. A clinical study of 23 cases of female anogenital carcinoma. *Br J Dermatol*. Dec 2000;143(6):1217-23. doi:10.1046/j.1365-2133.2000.03891.x
16. Sahn EE, Bluestein EL, Oliva S. Familial lichen sclerosus et atrophicus in childhood. *Pediatr Dermatol*. Jun 1994;11(2):160-3. doi:10.1111/j.1525-1470.1994.tb00572.x
17. Aslanian FM, Marques MT, Matos HJ, et al. HLA markers in familial Lichen sclerosus. *J Dtsch Dermatol Ges*. Oct 2006;4(10):842-7. doi:10.1111/j.1610-0387.2006.06087.x
18. Sherman V, McPherson T, Baldo M, Salim A, Gao XH, Wojnarowska F. The high rate of familial lichen sclerosus suggests a genetic contribution: an observational cohort study. *J Eur Acad Dermatol Venereol*. Sep 2010;24(9):1031-4. doi:10.1111/j.1468-3083.2010.03572.x
19. Higgins CA, Cruickshank ME. A population-based case-control study of aetiological factors associated with vulval lichen sclerosus. *J Obstet Gynaecol*. Apr 2012;32(3):271-5. doi:10.3109/01443615.2011.649320
20. Virgili A, Borghi A, Cazzaniga S, et al. New insights into potential risk factors and associations in genital lichen sclerosus: Data from a multicentre Italian study on 729 consecutive cases. *J Eur Acad Dermatol Venereol*. Apr 2017;31(4):699-704. doi:10.1111/jdv.13867



21. Kirtschig G, Kuik D. A Dutch cohort study confirms familial occurrence of anogenital lichen sclerosus. *Journal of Women's Health Care*. 2014;3(6)
22. Marren P, Yell J, Charnock FM, Bunce M, Welsh K, Wojnarowska F. The association between lichen sclerosus and antigens of the HLA system. *Br J Dermatol*. Feb 1995;132(2):197-203. doi:10.1111/j.1365-2133.1995.tb05013.x
23. Gao XH, Barnardo MC, Winsey S, et al. The association between HLA DR, DQ antigens, and vulval lichen sclerosus in the UK: HLA DRB112 and its associated DRB112/DQB10301/04/09/010 haplotype confers susceptibility to vulval lichen sclerosus, and HLA DRB10301/04 and its associated DRB10301/04/DQB10201/02/03 haplotype protects from vulval lichen sclerosus. *J Invest Dermatol*. Nov 2005;125(5):895-9. doi:10.1111/j.0022-202X.2005.23905.x
24. Azurdia RM, Luzzi GA, Byren I, et al. Lichen sclerosus in adult men: a study of HLA associations and susceptibility to autoimmune disease. *Br J Dermatol*. Jan 1999;140(1):79-83. doi:10.1046/j.1365-2133.1999.02611.x
25. Khan Mohammad Beigi P. The Immunogenetics of Morphea and Lichen Sclerosus. *Adv Exp Med Biol*. 2022;1367:155-172. doi:10.1007/978-3-030-92616-8\_7
26. Powell J, Wojnarowska F, Winsey S, Marren P, Welsh K. Lichen sclerosus premenarche: autoimmunity and immunogenetics. *Br J Dermatol*. Mar 2000;142(3):481-4. doi:10.1046/j.1365-2133.2000.03360.x
27. Villa M, Dragonetti E, Grande M, et al. Skin phototype and local trauma in the onset of balanitis xerotica obliterans (BXO) in circumcised patients. *In Vivo*. January-February 2012;26(1):143-146.
28. Koupaie J. Letter: Lichen sclerosus et atrophicus associated with Turner syndrome. *Arch Dermatol*. Aug 1976;112(8):1174. doi:10.1001/archderm.1976.01630320072023
29. Lagerstedt M, Karvinen K, Joki-Erkkilä M, Huotari-Orava R, Snellman E, Laasanen SL. Childhood lichen sclerosus--a challenge for clinicians. *Pediatr Dermatol*. Jul-Aug 2013;30(4):444-50. doi:10.1111/pde.12109
30. Wegiel M, Antosz A, Gieburowska J, et al. Autoimmunity Predisposition in Girls With Turner Syndrome. *Front Endocrinol (Lausanne)*. 2019;10:511. doi:10.3389/fendo.2019.00511
31. Edmonds E, Barton G, Buisson S, et al. Gene expression profiling in male genital lichen sclerosus. *Int J Exp Pathol*. Oct 2011;92(5):320-5. doi:10.1111/j.1365-2613.2011.00779.x
32. Gambichler T, Skrygan M, Czempiel V, et al. Differential expression of connective tissue growth factor and extracellular matrix proteins in lichen sclerosus. *J Eur Acad Dermatol Venereol*. Feb 2012;26(2):207-12. doi:10.1111/j.1468-3083.2011.04037.x
33. Gambichler T, Terras S, Kreuter A, Skrygan M. Altered global methylation and hydroxymethylation status in vulvar lichen sclerosus: further support for epigenetic mechanisms. *Br J Dermatol*. Mar 2014;170(3):687-93. doi:10.1111/bjd.12702
34. Rotondo JC, Borghi A, Selvatici R, et al. Hypermethylation-Induced Inactivation of the IRF6 Gene as a Possible Early Event in Progression of Vulvar Squamous Cell Carcinoma Associated With Lichen Sclerosus. *JAMA Dermatol*. Aug 1 2016;152(8):928-33. doi:10.1001/jamadermatol.2016.1336
35. Rotondo JC, Borghi A, Selvatici R, et al. Association of Retinoic Acid Receptor  $\beta$  Gene With Onset and Progression of Lichen Sclerosus-Associated Vulvar Squamous Cell Carcinoma. *JAMA Dermatol*. Jul 1 2018;154(7):819-823. doi:10.1001/jamadermatol.2018.1373
36. Terlou A, Santegoets LA, van der Meijden WI, et al. An autoimmune phenotype in vulvar lichen sclerosus and lichen planus: a Th1 response and high levels of microRNA-155. *J Invest Dermatol*. Mar 2012;132(3 Pt 1):658-66. doi:10.1038/jid.2011.369
37. Pilatz A, Altinkilic B, Schormann E, et al. Congenital phimosis in patients with and without lichen sclerosus: distinct expression patterns of tissue remodeling associated genes. *J Urol*. Jan 2013;189(1):268-74. doi:10.1016/j.juro.2012.09.010
38. Kaya G, Rodriguez I, Jorcano JL, Vassalli P, Stamenkovic I. Selective suppression of CD44 in keratinocytes of mice bearing an antisense CD44 transgene driven by a tissue-specific promoter disrupts hyaluronate metabolism in the skin and impairs keratinocyte proliferation. *Genes Dev*. Apr 15 1997;11(8):996-1007. doi:10.1101/gad.11.8.996

39. Kaya G, Augsburger E, Stamenkovic I, Saurat JH. Decrease in epidermal CD44 expression as a potential mechanism for abnormal hyaluronate accumulation in superficial dermis in lichen sclerosus et atrophicus. *J Invest Dermatol*. Dec 2000;115(6):1054-8. doi:10.1046/j.1523-1747.2000.00194.x
40. Farrell AM, Marren P, Dean D, Wojnarowska F. Lichen sclerosus: evidence that immunological changes occur at all levels of the skin. *Br J Dermatol*. Jun 1999;140(6):1087-92.
41. Tchórzewski H, Rotsztejn H, Banasik M, Lewkowicz P, Głowacka E. The involvement of immunoregulatory T cells in the pathogenesis of lichen sclerosus. *Med Sci Monit*. Jan 2005;11(1):Cr39-43.
42. Corazza M, Oton-Gonzalez L, Scuderi V, et al. Tissue cytokine/chemokine profile in vulvar lichen sclerosus: An observational study on keratinocyte and fibroblast cultures. *J Dermatol Sci*. Dec 2020;100(3):223-226. doi:10.1016/j.jdermsci.2020.09.006
43. Zhao Y, Zhao S, Li H, Qin X, Wu X. Expression of galectin-7 in vulvar lichen sclerosus and its effect on dermal fibroblasts. *Oncol Lett*. Aug 2018;16(2):2559-2564. doi:10.3892/ol.2018.8897
44. Oyama N, Chan I, Neill SM, et al. Autoantibodies to extracellular matrix protein 1 in lichen sclerosus. *Lancet*. Jul 12 2003;362(9378):118-23. doi:10.1016/s0140-6736(03)13863-9
45. Edmonds EV, Oyama N, Chan I, Francis N, McGrath JA, Bunker CB. Extracellular matrix protein 1 autoantibodies in male genital lichen sclerosus. *Br J Dermatol*. Jul 2011;165(1):218-9. doi:10.1111/j.1365-2133.2011.10326.x
46. Howard A, Dean D, Cooper S, Kirtshig G, Wojnarowska F. Circulating basement membrane zone antibodies are found in lichen sclerosus of the vulva. *Australas J Dermatol*. Feb 2004;45(1):12-5. doi:10.1111/j.1440-0960.2004.00026.x
47. Baldo M, Bhogal B, Groves RW, Powell J, Wojnarowska F. Childhood vulval lichen sclerosus: autoimmunity to the basement membrane zone protein BP180 and its relationship to autoimmunity. *Clin Exp Dermatol*. Jul 2010;35(5):543-5. doi:10.1111/j.1365-2230.2010.03827.x
48. Baldo M, Bailey A, Bhogal B, Groves RW, Ogg G, Wojnarowska F. T cells reactive with the NC16A domain of BP180 are present in vulval lichen sclerosus and lichen planus. *J Eur Acad Dermatol Venereol*. Feb 2010;24(2):186-90. doi:10.1111/j.1468-3083.2009.03375.x
49. Patsatsi A, Kyriakou A, Mantas A, Vavilis D, Patsialas C, Sotiriadis D. Circulating anti-BP180 NC16a and anti-BP230 autoantibodies in patients with genital lichen sclerosus do not correlate with disease activity and pruritus. *Acta Derm Venereol*. Nov 2014;94(6):711-2. doi:10.2340/00015555-1851
50. Sander CS, Ali I, Dean D, Thiele JJ, Wojnarowska F. Oxidative stress is implicated in the pathogenesis of lichen sclerosus. *Br J Dermatol*. Sep 2004;151(3):627-35. doi:10.1111/j.1365-2133.2004.06142.x
51. Grassi S, Tadiotto Cicogna G, Magri F, et al. Frontal fibrosing alopecia and genital Lichen sclerosus: Single-center experience. *J Cosmet Dermatol*. Feb 2021;20(2):615-620. doi:10.1111/jocd.13573
52. Harrington CI, Dunsmore IR. An investigation into the incidence of auto-immune disorders in patients with lichen sclerosus and atrophicus. *Br J Dermatol*. May 1981;104(5):563-6. doi:10.1111/j.1365-2133.1981.tb08172.x
53. Meyrick Thomas RH, Ridley CM, McGibbon DH, Black MM. Lichen sclerosus et atrophicus and autoimmunity--a study of 350 women. *Br J Dermatol*. Jan 1988;118(1):41-6. doi:10.1111/j.1365-2133.1988.tb01748.x
54. McGrath EJ, Davies MG. Lichen sclerosus arising from a chronic wound and coexistent with multiple sclerosis. *J Eur Acad Dermatol Venereol*. Jan 2005;19(1):139-41. doi:10.1111/j.1468-3083.2004.01082.x
55. Cooper SM, Ali I, Baldo M, Wojnarowska F. The association of lichen sclerosus and erosive lichen planus of the vulva with autoimmune disease: a case-control study. *Arch Dermatol*. Nov 2008;144(11):1432-5. doi:10.1001/archderm.144.11.1432
56. Bjekić M, Šipetić S, Marinković J. Risk factors for genital lichen sclerosus in men. *Br J Dermatol*. Feb 2011;164(2):325-9. doi:10.1111/j.1365-2133.2010.10091.x
57. Kreuter A, Wischnewski J, Terras S, Altmeyer P, Stücker M, Gambichler T. Coexistence of lichen sclerosus and morphea: a retrospective analysis of 472 patients with localized scleroderma from a German tertiary referral center. *J Am Acad Dermatol*. Dec 2012;67(6):1157-62. doi:10.1016/j.jaad.2012.04.003

58. Kreuter A, Kryvosheyeva Y, Terras S, et al. Association of autoimmune diseases with lichen sclerosus in 532 male and female patients. *Acta Derm Venereol*. Mar 27 2013;93(2):238-41. doi:10.2340/00015555-1512
59. Lee A, Bradford J, Fischer G. Long-term Management of Adult Vulvar Lichen Sclerosus: A Prospective Cohort Study of 507 Women. *JAMA Dermatol*. Oct 2015;151(10):1061-7. doi:10.1001/jamadermatol.2015.0643
60. Hu J, Hesson A, Haefner HK, Rominski S. The prevalence of self-reported medical comorbidities in patients with vulvar lichen sclerosus: A single-center retrospective study. *Int J Gynaecol Obstet*. May 2021;153(2):340-343. doi:10.1002/ijgo.13480
61. Kette B, Ringel N, Bradley S, Buck E, Tefera E, Iglesia C. PREVALENCE OF LICHEN SCLEROSUS IN PATIENTS WITH AUTOIMMUNE CONNECTIVE TISSUE DISORDERS AND PELVIC FLOOR DISORDERS: A RETROSPECTIVE COHORT STUDY. SPRINGER LONDON LTD 236 GRAYS INN RD, 6TH FLOOR, LONDON WC1X 8HL, ENGLAND; 2019:S307-S308.
62. Guarneri F, Giuffrida R, Di Bari F, Cannavò SP, Benvenga S. Thyroid Autoimmunity and Lichen. *Front Endocrinol (Lausanne)*. 2017;8:146. doi:10.3389/fendo.2017.00146
63. Simpkin S, Oakley A. Clinical review of 202 patients with vulval lichen sclerosus: A possible association with psoriasis. *Australas J Dermatol*. Feb 2007;48(1):28-31. doi:10.1111/j.1440-0960.2007.00322.x
64. Eberz B, Berghold A, Regauer S. High prevalence of concomitant anogenital lichen sclerosus and extragenital psoriasis in adult women. *Obstet Gynecol*. May 2008;111(5):1143-7. doi:10.1097/AOG.0b013e31816fdcdf
65. Becker K, Meissner V, Farwick W, Bauer R, Gaiser MR. Lichen sclerosus and atopy in boys: coincidence or correlation? *Br J Dermatol*. Feb 2013;168(2):362-6. doi:10.1111/j.1365-2133.2012.11201.x
66. Elakis JA, Hall AP. Skin disease of penis and male genitalia is linked to atopy and circumcision: caseload in a male genital dermatology clinic. *Australas J Dermatol*. Aug 2017;58(3):e68-e72. doi:10.1111/ajd.12485
67. Kirk PS, Yi Y, Hadj-Moussa M, Malaeb BS. Diversity of patient profile, urethral stricture, and other disease manifestations in a cohort of adult men with lichen sclerosus. *Investig Clin Urol*. May 2016;57(3):202-7. doi:10.4111/icu.2016.57.3.202
68. Hofer MD, Meeks JJ, Mehdiratta N, Granieri MA, Cashy J, Gonzalez CM. Lichen sclerosus in men is associated with elevated body mass index, diabetes mellitus, coronary artery disease and smoking. *World J Urol*. Feb 2014;32(1):105-8. doi:10.1007/s00345-013-1090-7
69. Kalra S, Chawla A. Diabetes and balanoposthitis. *J Pak Med Assoc*. Aug 2016;66(8):1039-41.
70. Fan R, Leasure AC, Maisha FI, Cohen JM, Little AJ. Thyroid disorders associated with lichen sclerosus: a case-control study in the All of Us Research Program. *Br J Dermatol*. Nov 2022;187(5):797-799. doi:10.1111/bjd.21702
71. Berger MB, Damico NJ, Menees SB, Fenner DE, Haefner HK. Rates of self-reported urinary, gastrointestinal, and pain comorbidities in women with vulvar lichen sclerosus. *J Low Genit Tract Dis*. Jul 2012;16(3):285-9. doi:10.1097/LGT.0b013e3182562f1e
72. Hieta N, Kurki S, Rintala M, Söderlund J, Hietanen S, Orte K. Association of Vulvar Melanoma with Lichen Sclerosus. *Acta Derm Venereol*. Mar 1 2019;99(3):339-340. doi:10.2340/00015555-3103
73. La Spina M, Meli MC, De Pasquale R, et al. Vulvar Melanoma Associated with Lichen Sclerosus in a Child: Case Report and Literature Review. *Pediatr Dermatol*. May 2016;33(3):e190-e194. doi:10.1111/pde.12838
74. Goldstein AT, Marinoff SC, Christopher K, Srodon M. Prevalence of vulvar lichen sclerosus in a general gynecology practice. *J Reprod Med*. Jul 2005;50(7):477-80.
75. Kirtschig G. Lichen Sclerosus-Presentation, Diagnosis and Management. *Dtsch Arztebl Int*. May 13 2016;113(19):337-43. doi:10.3238/arztebl.2016.0337
76. West DS, Papalas JA, Selim MA, Vollmer RT. Dermatopathology of the foreskin: an institutional experience of over 400 cases. *J Cutan Pathol*. Jan 2013;40(1):11-8. doi:10.1111/cup.12032
77. Tasker GL, Wojnarowska F. Lichen sclerosus. *Clin Exp Dermatol*. Mar 2003;28(2):128-33. doi:10.1046/j.1365-2230.2003.01211.x

78. Leibovitz A, Kaplun VV, Saposhnicov N, Habot B. Vulvovaginal examinations in elderly nursing home women residents. *Arch Gerontol Geriatr.* Aug 1 2000;31(1):1-4. doi:10.1016/s0167-4943(00)00059-5
79. Wallace HJ. Lichen sclerosus et atrophicus. *Trans St Johns Hosp Dermatol Soc.* 1971;57(1):9-30.
80. Clayton R, Stewart E, Wojnarowska F. Rising demand for the services of a dedicated dermatological vulval clinic without changes in disease profile. 2006:
81. Halonen P, Jakobsson M, Heikinheimo O, Gissler M, Pukkala E. Incidence of lichen sclerosus and subsequent causes of death: a nationwide Finnish register study. *Bjog.* Jun 2020;127(7):814-819. doi:10.1111/1471-0528.16175
82. Kizer WS, Prarie T, Morey AF. Balanitis xerotica obliterans: epidemiologic distribution in an equal access health care system. *South Med J.* Jan 2003;96(1):9-11. doi:10.1097/00007611-200301000-00004
83. Halonen P, Jakobsson M, Heikinheimo O, Riska A, Gissler M, Pukkala E. Lichen sclerosus and risk of cancer. *Int J Cancer.* May 1 2017;140(9):1998-2002. doi:10.1002/ijc.30621
84. McPherson T, Cooper S. Vulval lichen sclerosus and lichen planus. *Dermatol Ther.* Sep-Oct 2010;23(5):523-32. doi:10.1111/j.1529-8019.2010.01355.x
85. Edmonds EV, Hunt S, Hawkins D, Dinneen M, Francis N, Bunker CB. Clinical parameters in male genital lichen sclerosus: a case series of 329 patients. *J Eur Acad Dermatol Venereol.* Jun 2012;26(6):730-7. doi:10.1111/j.1468-3083.2011.04155.x
86. Meuli M, Briner J, Hanimann B, Sacher P. Lichen sclerosus et atrophicus causing phimosis in boys: a prospective study with 5-year followup after complete circumcision. *J Urol.* Sep 1994;152(3):987-9. doi:10.1016/s0022-5347(17)32638-1
87. Becker K. Lichen sclerosus in boys. *Dtsch Arztebl Int.* Jan 2011;108(4):53-8. doi:10.3238/arztebl.2011.053
88. Meffert JJ, Davis BM, Grimwood RE. Lichen sclerosus. *J Am Acad Dermatol.* Mar 1995;32(3):393-416; quiz 417-8. doi:10.1016/0190-9622(95)90060-8
89. Jensen LS, Bygum A. Childhood lichen sclerosus is a rare but important diagnosis. *Dan Med J.* May 2012;59(5):A4424.
90. Kyriakis KP, Emmanuelides S, Terzoudi S, Palamaras I, Damoulaki E, Evangelou G. Gender and age prevalence distributions of morphea en plaque and anogenital lichen sclerosus. *J Eur Acad Dermatol Venereol.* Jul 2007;21(6):825-6. doi:10.1111/j.1468-3083.2006.01954.x
91. García-Bravo B, Sánchez-Pedreño P, Rodríguez-Pichardo A, Camacho F. Lichen sclerosus et atrophicus. A study of 76 cases and their relation to diabetes. *J Am Acad Dermatol.* Sep 1988;19(3):482-5. doi:10.1016/s0190-9622(88)70201-7
92. Steigleder G, Schlüter M. *Lichen sclerosus et atrophicus.* In: Andrade R, Gumport SL, Popkin GL, Rees TD (eds.): *Cancer of the skin.* Philadelphia, London, Toronto: Saunders. 1976.
93. Krapf JM, Smith AB, Cigna ST, Goldstein AT. Presenting Symptoms and Diagnosis of Vulvar Lichen Sclerosus in Premenopausal Women: A Cross-Sectional Study. *J Low Genit Tract Dis.* Jul 1 2022;26(3):271-275. doi:10.1097/lgt.0000000000000679
94. Kirtschig G, Cooper S. *Gynecologic Dermatology: Symptoms, Signs and Clinical Management.* JP Medical Ltd; 2016.
95. Ledwig PA, Weigand DA. Late circumcision and lichen sclerosus et atrophicus of the penis. *J Am Acad Dermatol.* Feb 1989;20(2 Pt 1):211-4. doi:10.1016/s0190-9622(89)70024-4
96. Marren P, De Berker D, Millard P, Wojnarowska F. Bullous and haemorrhagic lichen sclerosus with scalp involvement. *Clin Exp Dermatol.* Sep 1992;17(5):354-6. doi:10.1111/j.1365-2230.1992.tb00231.x
97. Madan V, Cox NH. Extensive bullous lichen sclerosus with scarring alopecia. *Clin Exp Dermatol.* Apr 2009;34(3):360-2. doi:10.1111/j.1365-2230.2008.02919.x
98. Basak PY, Basak K. Lichen sclerosus et atrophicus of the scalp: satisfactory response to acitretin. *J Eur Acad Dermatol Venereol.* Mar 2002;16(2):183-5. doi:10.1046/j.1468-3083.2002.00392\_10.x



99. Schulten EA, Starink TM, van der Waal I. Lichen sclerosus et atrophicus involving the oral mucosa: report of two cases. *J Oral Pathol Med*. Sep 1993;22(8):374-7. doi:10.1111/j.1600-0714.1993.tb01092.x
100. Tremaine RD, Miller RA. Lichen sclerosus et atrophicus. *Int J Dermatol*. Jan-Feb 1989;28(1):10-6. doi:10.1111/j.1365-4362.1989.tb01300.x
101. Ramrakha-Jones VS, Paul M, McHenry P, Burden AD. Nail dystrophy due to lichen sclerosus? *Clin Exp Dermatol*. Sep 2001;26(6):507-9. doi:10.1046/j.1365-2230.2001.00878.x
102. Zendell K, Edwards L. Lichen sclerosus with vaginal involvement: report of 2 cases and review of the literature. *JAMA Dermatol*. Oct 2013;149(10):1199-202. doi:10.1001/jamadermatol.2013.4885
103. Bhargava K, Lewis FM. Lichen sclerosus occurring on vaginal mucosa secondary to uterine prolapse. *J Obstet Gynaecol*. Apr 2013;33(3):319-20. doi:10.3109/01443615.2012.738720
104. Shasi PB, Chapman HT, Evans DT, Jaleel H. Psychological and psychiatric morbidity in lichen sclerosus in a cohort recruited from a genitourinary medicine clinic. *Int J STD AIDS*. Jan 2010;21(1):17-8. doi:10.1258/ijsa.2009.009102
105. Смирнова ИО, Парыгина ОВ. Mental disorder in females with chronic vulvar dermatoses the structure and risk factors. 2019;
106. Baykal C, Kobaner GB, Copur S, Buyukbabani N. Lichen Sclerosus on the Sites of Striae Distensae and a Surgical Scar in a Patient with Coexistent Morphea. Case Reports. *Acta Dermatovenerol Croat*. Mar 2019;27(1):44-46.
107. Warrington SA, de San Lázaro C. Lichen sclerosus et atrophicus and sexual abuse. *Arch Dis Child*. Dec 1996;75(6):512-6.
108. Powell J, Wojnarowska F. Childhood vulval lichen sclerosus and sexual abuse are not mutually exclusive diagnoses. *Bmj*. Jan 29 2000;320(7230):311.
109. Sideri M, Parazzini F, Rognoni MT, et al. Risk factors for vulvar lichen sclerosus. *Am J Obstet Gynecol*. Jul 1989;161(1):38-42.
110. Tang GX, Wu X, Chen JP, Zhou BS. Study on the risk factors of 100 cases with vulvar dystrophy. [Chinese]. *Zhonghua liu xing bing xue za zhi = Zhonghua liuxingbingxue zazhi*. Oct 2003;24(10):932-934.
111. Sideri M, Parazzini F, Rognoni MT, et al. Risk factors for vulvar lichen sclerosus. *Am J Obstet Gynecol*. Jul 1989;161(1):38-42. doi:10.1016/0002-9378(89)90228-7
112. Edwards LR, Privette ED, Patterson JW, et al. Radiation-induced lichen sclerosus of the vulva : First report in the medical literature. *Wien Med Wochenschr*. Mar 2017;167(3-4):74-77. doi:10.1007/s10354-016-0525-3
113. Moftah N. Radiotherapy related dermatoses. Conference Abstract. *Journal of the Dermatology Nurses' Association Conference: 24th World Congress of Dermatology Milan Italy*. 2020;12(2)
114. Gupta S, Malhotra AK, Ajith C. Lichen sclerosus: role of occlusion of the genital skin in the pathogenesis. *Indian J Dermatol Venereol Leprol*. Jan-Feb 2010;76(1):56-8. doi:10.4103/0378-6323.58681
115. Owen CM, Yell JA. Genital lichen sclerosus associated with incontinence. *J Obstet Gynaecol*. Mar 2002;22(2):209-10. doi:10.1080/01443610120113454
116. Edmonds EV, Bunker CB. Nuclear magnetic resonance spectroscopy of urine in male genital lichen sclerosus. Letter. *British Journal of Dermatology*. Dec 2010;163(6):1355-6. doi:<https://dx.doi.org/10.1111/j.1365-2133.2010.09980.x>
117. Bunker CB. Occlusion, urine and genital lichen sclerosus. Letter  
Comment. *Indian Journal of Dermatology, Venereology & Leprology*. May-Jun 2012;78(3):367-8. doi:<https://dx.doi.org/10.4103/0378-6323.95461>
118. Bratila E, Cirstoiu M, Mehedintu C, et al. The effect of chronic vulvar dystrophy on urinary continence in patients at climacterium. Conference Abstract. *Maturitas*. June 2017;100:169. doi:<http://dx.doi.org/10.1016/j.maturitas.2017.03.171>

119. Kravvas G, Muneer A, Watchorn R, et al. Male genital lichen sclerosus, micro incontinence and occlusion: mapping the disease across the prepuce. *Clinical & Experimental Dermatology*. Feb 2022;12:12. doi:<https://dx.doi.org/10.1111/ced.15127>
120. Panou E, Panagou E, Foley C, et al. Male genital lichen sclerosus associated with urological interventions and microincontinence: a case series of 21 patients. *Clinical & Experimental Dermatology*. Jan 2022;47(1):107-109. doi:<https://dx.doi.org/10.1111/ced.14869>
121. Becker K. Atopy, the barrier, urine and genital lichen sclerosus: reply from the authors. Letter Comment. *British Journal of Dermatology*. Oct 2013;169(4):953-4. doi:<https://dx.doi.org/10.1111/bjd.12554>
122. Becker K, Meissner V, Farwick W, Bauer R, Gaiser MR. Lichen sclerosus and atopy in boys: coincidence or correlation? Randomized Controlled Trial. *British Journal of Dermatology*. Feb 2013;168(2):362-6. doi:<https://dx.doi.org/10.1111/j.1365-2133.2012.11201.x>
123. Eisendle K, Grabner T, Kutzner H, Zelger B. Possible role of *Borrelia burgdorferi* sensu lato infection in lichen sclerosus. *Archives of Dermatology*. May 2008;144(5):591-8. doi:<https://dx.doi.org/10.1001/archderm.144.5.591>
124. Aberer E, Surtov-Pudar M, Wilfinger D, Deutsch A, Leitinger G, Schaidler H. Co-culture of human fibroblasts and *Borrelia burgdorferi* enhances collagen and growth factor mRNA. *Arch Dermatol Res*. Mar 2018;310(2):117-126. doi:10.1007/s00403-017-1797-1
125. Vasudevan B, Sagar A, Bahal A, Mohanty AP. Extragenital lichen sclerosus with aetiological link to *Borrelia*. *Med J Armed Forces India*. Oct 2011;67(4):370-3. doi:10.1016/s0377-1237(11)60089-0
126. Shelley WB, Shelley ED, Amurao CV. Treatment of lichen sclerosus with antibiotics. *Int J Dermatol*. Sep 2006;45(9):1104-6. doi:10.1111/j.1365-4632.2006.02978.x
127. Zollinger T, Mertz KD, Schmid M, Schmitt A, Pfaltz M, Kempf W. *Borrelia* in granuloma annulare, morphea and lichen sclerosus: a PCR-based study and review of the literature. *Journal of Cutaneous Pathology*. May 2010;37(5):571-7. doi:<https://dx.doi.org/10.1111/j.1600-0560.2009.01493.x>
128. Ozkan S, Atabey N, Fetil E, Erkizan V, Gunes AT. Evidence for *Borrelia burgdorferi* in morphea and lichen sclerosus. *International Journal of Dermatology*. Apr 2000;39(4):278-83.
129. Fujiwara H, Fujiwara K, Hashimoto K, et al. Detection of *Borrelia burgdorferi* DNA (*B garinii* or *B afzelii*) in morphea and lichen sclerosus et atrophicus tissues of German and Japanese but not of US patients. *Arch Dermatol*. Jan 1997;133(1):41-4.
130. Afa G, Caprilli F, Crescimbeni E, Morrone A, Prignano G, Fazio M. [Anti-*Borrelia burgdorferi* antibodies in chronic erythema migrans, benign lymphadenitis, scleroderma and scleroatrophic lichen]. Review. *G Ital Dermatol Venereol*. Sep 1990;125(9):369-73. Anticorpi anti-*Borrelia burgdorferi* nell'eritema cronico migrante, nella lymphadenitis cutis benigna, nella sclerodermia e nel lichen scleroatrofico.
131. Alonso-Llamazares J, Persing DH, Anda P, Gibson LE, Rutledge BJ, Iglesias L. No evidence for *Borrelia burgdorferi* infection in lesions of morphea and lichen sclerosus et atrophicus in Spain. A prospective study and literature review. *Acta Dermato-Venereologica*. Jul 1997;77(4):299-304.
132. Schempp C, Bocklage H, Lange R, Kolmel HW, Orfanos CE, Gollnick H. Further evidence for *Borrelia burgdorferi* infection in morphea and lichen sclerosus et atrophicus confirmed by DNA amplification. *Journal of Investigative Dermatology*. May 1993;100(5):717-20.
133. Müller KE. Damage of collagen and elastic fibres by *borrelia burgdorferi* - known and new clinical and histopathological aspects. *Open Neurol J*. 2012;6:179-86. doi:10.2174/1874205x01206010179
134. De Vito JR, Merogi AJ, Vo T, et al. Role of *Borrelia burgdorferi* in the pathogenesis of morphea/scleroderma and lichen sclerosus et atrophicus: a PCR study of thirty-five cases. *J Cutan Pathol*. Aug 1996;23(4):350-8. doi:10.1111/j.1600-0560.1996.tb01309.x
135. Colomé-Grimmer MI, Payne DA, Tying SK, Sánchez RL. *Borrelia burgdorferi* DNA and *Borrelia hermsii* DNA are not associated with morphea or lichen sclerosus et atrophicus in the southwestern United States. *Arch Dermatol*. Sep 1997;133(9):1174.

136. Vasudevan B, Chatterjee M. Lyme borreliosis and skin. *Indian J Dermatol*. May 2013;58(3):167-74. doi:10.4103/0019-5154.110822
137. Aberer E, Schmidt BL, Breier F, Kinaciyan T, Luger A. Amplification of DNA of *Borrelia burgdorferi* in urine samples of patients with granuloma annulare and lichen sclerosus et atrophicus [3]. Letter. *Archives of Dermatology*. February 1999;135(2):210-212. doi:<http://dx.doi.org/10.1001/archderm.135.2.210>
138. Aberer E, Kollegger H, Kristoferitsch W, Stanek G. Neuroborreliosis in morphea and lichen sclerosus et atrophicus. *Journal of the American Academy of Dermatology*. Nov 1988;19(5 Pt 1):820-5.
139. Menni S, Pistritto G, Gianni E. [Infantile sclero-atrophic lichen and infection caused by *Borrelia burgdorferi*]. *G Ital Dermatol Venereol*. Jun 1989;124(6):267-9. Lichen sclero-atrofico infantile e infezione da *Borrelia burgdorferi*.
140. Svecova D, Buchvald J. [*Borrelia burgdorferi* antibodies in scleroderma circumscripta, lichen sclerosus et atrophicus, erythema nodosum, granuloma annulare, erythema annulare and chronic urticaria]. *Bratisl Lek Listy*. 2000;101(4):194-9. Prtilátky proti *Borrelia burgdorferi* pri sclerodermia circumscripta, lichen sclerosus et atrophicus, erythema nodosum, granuloma anulare, erythema anulare a urticaria chronica.
141. George AA, Hixson CD, Peckham SJ, Tyler D, Zelger B. A case of oral lichen sclerosus with gingival involvement and *Borrelia* identification. *Histopathology*. Jul 2014;65(1):146-8. doi:10.1111/his.12363
142. Fesler MC, Middelveen MJ, Burke JM, Stricker RB. Erosive Vulvovaginitis Associated With *Borrelia burgdorferi* Infection. Case Reports. *J*. Jan-Dec 2019;7:2324709619842901. doi:<https://dx.doi.org/10.1177/2324709619842901>
143. Vaccaro M, Guarneri F, Borgia F, Cannavò SP, Benvenga S. Association of lichen sclerosus and autoimmune thyroiditis: possible role of *Borrelia burgdorferi*? *Thyroid*. Dec 2002;12(12):1147-8. doi:10.1089/105072502321085261
144. Ross SA, Sanchez JL, Taboas JO. Spirochetal forms in the dermal lesions of morphea and lichen sclerosus et atrophicus. *Am J Dermatopathol*. Aug 1990;12(4):357-62.
145. Breier F, Khanakah G, Stanek G, et al. Isolation and polymerase chain reaction typing of *Borrelia afzelii* from a skin lesion in a seronegative patient with generalized ulcerating bullous lichen sclerosus et atrophicus. *Br J Dermatol*. Feb 2001;144(2):387-92. doi:10.1046/j.1365-2133.2001.04034.x
146. Edmonds E, Mavin S, Francis N, Ho-Yen D, Bunker C. *Borrelia burgdorferi* is not associated with genital lichen sclerosus in men. *Br J Dermatol*. Feb 2009;160(2):459-60. doi:10.1111/j.1365-2133.2008.08969.x
147. Aberer E, Stanek G. Histological evidence for spirochetal origin of morphea and lichen sclerosus et atrophicans. *Am J Dermatopathol*. Oct 1987;9(5):374-9. doi:10.1097/00000372-198710000-00002
148. Pinazo Canales I, Betlloch Mas I, Mestre Bauza F, Salva Armengod F, Parras Vázquez F, Alomar Cardell J. [Determination of antibodies against *Borrelia burgdorferi* in patients with morphea, lichen sclerosus et atrophicus and erythema chronicum migrans]. *Rev Clin Esp*. Apr 1990;186(7):320-3. Determinación de anticuerpos frente a *Borrelia burgdorferi* en pacientes con morfea, liquen escleroso y atrófico y eritema crónico migrans.
149. Dillon WI, Saed GM, Fivenson DP. *Borrelia burgdorferi* DNA is undetectable by polymerase chain reaction in skin lesions of morphea, scleroderma, or lichen sclerosus et atrophicus of patients from North America. Comparative Study
- Research Support, Non-U.S. Gov't. *Journal of the American Academy of Dermatology*. Oct 1995;33(4):617-20.
150. Tuffanelli D. Do some patients with morphea and lichen sclerosus et atrophicans have a *Borrelia* infection? *Am J Dermatopathol*. 1987;9(5):371-373. doi:<http://dx.doi.org/10.1097/00000372-198710000-00001>
151. Aberer E, Neumann R, Lubec G. Acrodermatitis chronica atrophicans in association with lichen sclerosus et atrophicans: tubulo-interstitial nephritis and urinary excretion of spirochete-like organisms. Case Reports. *Acta Dermato-Venereologica*. 1987;67(1):62-5.

152. Kaya G, Berset M, Prins C, Chavaz P, Saurat JH. Chronic borreliosis presenting with morphea- and lichen sclerosus et atrophicus-like cutaneous lesions. a case report. *Dermatology*. 2001;202(4):373-5. doi:10.1159/000051687
153. Buechner SA, Winkelmann RK, Lautenschlager S, Gilli L, Ruffli T. Localized scleroderma associated with *Borrelia burgdorferi* infection. Clinical, histologic, and immunohistochemical observations. Case Reports. *Journal of the American Academy of Dermatology*. Aug 1993;29(2 Pt 1):190-6.
154. Asbrink E. Erythema chronicum migrans Afzelius and acrodermatitis chronica atrophicans. Early and late manifestations of Ixodes ricinus-borne *Borrelia spirochetes*. Research Support, Non-U.S. Gov't Review. *Acta Derm Venereol Suppl (Stockh)*. 1985;118:1-63.
155. Katinka P, Dora P, Antal B, et al. In situ Mycoplasma infection as aetiological factor in genital lichen sclerosus. Conference Abstract. *Journal of Investigative Dermatology*. September 2010;2):S14. doi:<http://dx.doi.org/10.1038/jid.2010.238>
156. Ponyai K, Bognar P, Pinter D, et al. Mycoplasma infection - A possible etiological cofactor in morphea and lichen sclerosus et atrophicus. Conference Abstract. *Journal of Investigative Dermatology*. September 2009;2):S102. doi:<http://dx.doi.org/10.1038/jid.2009.232>
157. Nasca MR, Lacarrubba F, Micali G. Human papillomavirus infection and lichen sclerosus: coincidence or link? Letter Review. *International Journal of Dermatology*. 05 2018;57(5):617-618. doi:<https://dx.doi.org/10.1111/ijd.13933>
158. Shim TN, Harwood CA, Marsh SG, et al. Immunogenetics and human papillomavirus (HPV) in male genital lichen sclerosus (MGLSc). Research Support, Non-U.S. Gov't. *International Journal of STD & AIDS*. 12 2020;31(14):1334-1339. doi:<https://dx.doi.org/10.1177/0956462420949395>
159. Pilatz A, Altinkilic B, Ruzs A, et al. Role of human papillomaviruses in persistent and glucocorticoid-resistant juvenile phimosis. Research Support, Non-U.S. Gov't. *Journal of the European Academy of Dermatology & Venereology*. Jun 2013;27(6):716-21. doi:<https://dx.doi.org/10.1111/j.1468-3083.2012.04542.x>
160. Huang HJ, Murakami T, Yamabe T. [Papillomavirus infection of the vulva]. *Nippon Sanka Fujinka Gakkai Zasshi*. Jun 1987;39(6):959-64.
161. Aide S, Lattario FR, Almeida G, do Val IC, da Costa Carvalho M. Epstein-Barr virus and human papillomavirus infection in vulvar lichen sclerosus. Research Support, Non-U.S. Gov't. *Journal of Lower Genital Tract Disease*. Oct 2010;14(4):319-22. doi:<https://dx.doi.org/10.1097/LGT.0b013e3181d734f1>
162. Lacour J, Nicot T, Bedane C, Ortonne JP, Bonnetblanc JM. Bullous lichen sclerosus with chronic hepatitis C virus infection [7]. Letter. *British Journal of Dermatology*. 1997;137(3):474-476. doi:<http://dx.doi.org/10.1111/j.1365-2133.1997.tb03767.x>
163. Basile S, Pinelli S, Benedetti Panici P, et al. Association between *Helicobacter pylori* infection and vulvar lichen sclerosus: a clinical comparative study. Comparative Study. *Eur J Dermatol*. 04 01 2018;28(2):226-227. doi:<https://dx.doi.org/10.1684/ejd.2017.3207>
164. Brunner A, Medvecz M, Makra N, et al. Human beta defensin levels and vaginal microbiome composition in post-menopausal women diagnosed with lichen sclerosus. *Sci Rep*. Aug 6 2021;11(1):15999. doi:10.1038/s41598-021-94880-4
165. Cohen AJ, Gaither TW, Srirangapatanam S, et al. Synchronous genitourinary lichen sclerosus signals a distinct urinary microbiome profile in men with urethral stricture disease. *World Journal of Urology*. Feb 2021;39(2):605-611. doi:<https://dx.doi.org/10.1007/s00345-020-03198-9>
166. Watchorn RE, van den Munckhof EHA, Quint KD, et al. Balanopreputial sac and urine microbiota in patients with male genital lichen sclerosus. *International Journal of Dermatology*. Feb 2021;60(2):201-207. doi:<https://dx.doi.org/10.1111/ijd.15252>
167. Chattopadhyay M, Sterling J. Skin diseases affecting the vulva. *Obstetrics, Gynaecology and Reproductive Medicine*. June 2011;21(6):169-175. doi:<http://dx.doi.org/10.1016/j.ogrm.2011.03.004>



168. Liu X, Zhuo Y, Zhou Y, Hu J, Wen H, Xiao C. Analysis of the Vulvar Skin Microbiota in Asymptomatic Women and Patients With Vulvar Lichen Sclerosus Based on 16S rRNA Sequencing. *Front Cell Dev Biol.* 2022;10:842031. doi:10.3389/fcell.2022.842031
169. Vieira-Baptista P, Cavaco-Gomes J, Lima-Silva J, et al. What differentiates symptomatic from asymptomatic women with vulvar lichen sclerosus? Conference Abstract. *Journal of Lower Genital Tract Disease.* October 2013;2):S113. doi:<http://dx.doi.org/10.1097/LGT.0b013e3182a35c46>
170. Grasso F, Grasso V. Anxiety as risk factor for vulvar lichen sclerosus et atrophicus. *Gazzetta Medica Italiana Archivio per le Scienze Mediche.* May 2014;173(5):317-319.
171. Wong YW, Powell J, Oxon MA. Lichen sclerosus. A review. *Minerva Med.* Apr 2002;93(2):95-9.
172. Iannaccone AM, Verrusio G, Iurassich S. Female lichen sclerosus genitalis: discomfort and adaptation. *Clin Ter.* Jul-Aug 2016;167(4):113-20. doi:10.7417/ct.2016.1940
173. Gunthert AR, Faber M, Knappe G, Hellriegel S, Emons G. Early onset vulvar Lichen Sclerosus in premenopausal women and oral contraceptives. *Eur J Obstet Gynecol Reprod Biol.* Mar 2008;137(1):56-60.
174. Amri M, Zili J, Belhadjmohamed W, et al. Lichen sclerosus - Monomelic scleroderma association in a diabetic patient. [French]. Association lichen sclereux-sclerodermie monomelique chez une diabetique. *Nouvelles Dermatologiques.* 2001;20(6):375-378.
175. Virgili A, Borghi A, Cazzaniga S, et al. New insights into potential risk factors and associations in genital lichen sclerosus: Data from a multicentre Italian study on 729 consecutive cases. Multicenter Study. *Journal of the European Academy of Dermatology & Venereology.* Apr 2017;31(4):699-704. doi:<https://dx.doi.org/10.1111/jdv.13867>
176. Mirastschijski U, Schwenke C, Melchior S, Cedidi C. [Buried Penis: A Comprehensive Review on Aetiology, Classification and Plastic-Surgical Reconstruction]. Review. *Handchir Mikrochir Plast Chir.* Apr 2017;49(2):78-84. Buried Penis": Aktuelle Übersicht über Aetiologie, Klassifikation und plastisch-chirurgische Rekonstruktion. doi:<https://dx.doi.org/10.1055/s-0042-122420>
177. Doiron PR, Bunker CB. Obesity-related male genital lichen sclerosus. *Journal of the European Academy of Dermatology & Venereology.* May 2017;31(5):876-879. doi:<https://dx.doi.org/10.1111/jdv.14035>
178. Anandan L, Mohammed A. Surgical management of buried penis in adults. Review. *Central European Journal of Urology.* 2018;71(3):346-352. doi:<http://dx.doi.org/10.5173/cej.2018.1676>
179. Cocci A, Cito G, Falcone M, et al. Subjective and objective results in surgical correction of adult acquired buried penis: A single-centre observational study. *Arch Ital Urol Androl.* Mar 29 2019;91(1):25-29. doi:<https://dx.doi.org/10.4081/aiua.2019.1.25>
180. Falcone M, Capogrosso P, Sokolakis I, et al. What are the benefits and harms of the surgical management options for adult buried penis? A systematic review. Conference Abstract. *European Urology.* February 2022;81(Supplement 1):S1569. doi:<https://dx.doi.org/10.1016/S0302-2838%2822%2901132-0>
181. Alharbi A, Khobrani A, Noor A, et al. Risk of Lichen Sclerosus and Lichen Planus in Patients Receiving Immune Checkpoint Inhibitors. *Int J Environ Res Public Health.* Dec 29 2022;20(1)doi:10.3390/ijerph20010580
182. Fahy CMR, Torgerson RR, Davis MDP. Final Diagnosis of 112 Girls Presenting With Genital Mucocutaneous Symptoms and Signs: The Mayo Clinic Experience. *Pediatr Dermatol.* Sep 2017;34(5):e279-e280. doi:10.1111/pde.13247
183. Thomas RM, Ridley C, McGibbon D, Black M. Lichen sclerosus et atrophicus and autoimmunity—a study of 350 women. *British Journal of Dermatology.* 1988;118(1):41-46.
184. Raj G, Bell HK. A multi-centre audit on genital lichen sclerosus in the North West of England. *J Eur Acad Dermatol Venereol.* Jul 2014;28(7):963-6. doi:10.1111/jdv.12173
185. van der Meijden WI, Boffa MJ, Ter Harmsel B, et al. 2021 European guideline for the management of vulval conditions. *J Eur Acad Dermatol Venereol.* Apr 12 2022;doi:10.1111/jdv.18102
186. Fesler MC, Middelveen MJ, Burke JM, Stricker RB. Erosive Vulvovaginitis Associated With *Borrelia burgdorferi* Infection. *J Investig Med High Impact Case Rep.* Jan-Dec 2019;7:2324709619842901. doi:10.1177/2324709619842901

187. Retracted: Characterization of partially purified alkaloids from Cucurbita maxima seed and evaluation of their antioxidant activity in human erythrocytes and leukocytes. *J Food Biochem*. Jul 1 2021:e13839. doi:10.1111/jfbc.13839
188. Simpson RC, Thomas KS, Murphy R. Outcome measures for vulval skin conditions: a systematic review of randomized controlled trials. *Br J Dermatol*. Sep 2013;169(3):494-501. doi:10.1111/bjd.12391
189. Core Outcomes for Research in Lichen Sclerosus (CORALS). <https://www.nottingham.ac.uk/research/groups/cebd/projects/5rareandother/corals.aspx>
190. Erni B, Navarini AA, Huang D, Schoetzau A, Kind A, Mueller SM. Proposition of a severity scale for lichen sclerosus: The "Clinical Lichen Sclerosus Score". *Dermatol Ther*. Mar 2021;34(2):e14773. doi:10.1111/dth.14773
191. van der Meijden WI, Boffa MJ, Ter Harmsel B, et al. 2021 European guideline for the management of vulval conditions. *J Eur Acad Dermatol Venereol*. Jul 2022;36(7):952-972. doi:10.1111/jdv.18102
192. Kirby L, Gran S, Orekoya F, Owen C, Simpson R. Is urinary incontinence associated with vulval lichen sclerosus in women? A cross-sectional study. *Br J Dermatol*. Nov 2021;185(5):1063-1065. doi:10.1111/bjd.20583
193. Woodruff CM, Trivedi MK, Botto N, Kornik R. Allergic Contact Dermatitis of the Vulva. *Dermatitis*. Sep/Oct 2018;29(5):233-243. doi:10.1097/der.0000000000000339
194. D'Antuono A, Bellavista S, Negosanti F, Zauli S, Baldi E, Patrizi A. Dermasilk briefs in vulvar lichen sclerosus: an adjuvant tool. *J Low Genit Tract Dis*. Oct 2011;15(4):287-91. doi:10.1097/LGT.0b013e31821380a0
195. Corazza M, Schettini N, Zedde P, Borghi A. Vulvar Lichen Sclerosus from Pathophysiology to Therapeutic Approaches: Evidence and Prospects. *Biomedicines*. Aug 3 2021;9(8)doi:10.3390/biomedicines9080950
196. Todd P, Halpern S, Kirby J, Pembroke A. Lichen sclerosus and the Köbner phenomenon. *Clin Exp Dermatol*. May 1994;19(3):262-3. doi:10.1111/j.1365-2230.1994.tb01183.x
197. Gupta V, Gupta S. Genital lichen sclerosus developing around 'ectopic' urethral orifices supports the role of occlusion and urine in its pathogenesis. *Int J STD AIDS*. Aug 2017;28(9):940-942. doi:10.1177/0956462416688159
198. Ismail D, Owen CM. Paediatric vulval lichen sclerosus: a retrospective study. *Clin Exp Dermatol*. Oct 2019;44(7):753-758. doi:10.1111/ced.13894
199. Al-Niaimi F, Lyon C. Peristomal lichen sclerosus: the role of occlusion and urine exposure? *Br J Dermatol*. Mar 2013;168(3):643-6. doi:10.1111/bjd.12014
200. Panou E, Panagou E, Foley C, et al. Male genital lichen sclerosus associated with urological interventions and microincontinence: a case series of 21 patients. *Clin Exp Dermatol*. Jan 2022;47(1):107-109. doi:10.1111/ced.14869
201. Shim TN, Andrich DE, Mundy AR, Bunker CB. Lichen sclerosus associated with perineal urethrostomy. *Br J Dermatol*. Jan 2014;170(1):222-3. doi:10.1111/bjd.12617
202. Eisendle K, Grabner T, Kutzner H, Zelger B. Possible role of *Borrelia burgdorferi* sensu lato infection in lichen sclerosus. *Arch Dermatol*. May 2008;144(5):591-8. doi:10.1001/archderm.144.5.591
203. Aidé S, Lattario FR, Almeida G, do Val IC, da Costa Carvalho M. Epstein-Barr virus and human papillomavirus infection in vulvar lichen sclerosus. *J Low Genit Tract Dis*. Oct 2010;14(4):319-22. doi:10.1097/LGT.0b013e3181d734f1
204. Günthert AR, Faber M, Knappe G, Hellriegel S, Emons G. Early onset vulvar Lichen Sclerosus in premenopausal women and oral contraceptives. *Eur J Obstet Gynecol Reprod Biol*. Mar 2008;137(1):56-60. doi:10.1016/j.ejogrb.2007.10.005
205. Lewis FM, Shah M, Gawkrödger DJ. Contact sensitivity in pruritus vulvae: patch test results and clinical outcome. *Am J Contact Dermat*. Sep 1997;8(3):137-40.
206. Marren P, Wojnarowska F, Powell S. Allergic contact dermatitis and vulvar dermatoses. *Br J Dermatol*. Jan 1992;126(1):52-6. doi:10.1111/j.1365-2133.1992.tb08403.x

207. Cheng HS, Fernández-Peñas P. Allergic Contact Dermatitis of the Anogenital Region in Men and Women. *J Low Genit Tract Dis*. Apr 2020;24(2):221-224. doi:10.1097/lgt.0000000000000516
208. Corazza M, Virgili A, Toni G, Minghetti S, Tiengo S, Borghi A. Level of use and safety of botanical products for itching vulvar dermatoses. Are patch tests useful? *Contact Dermatitis*. May 2016;74(5):289-94. doi:10.1111/cod.12559
209. Carlson JA, Lamb P, Malfetano J, Ambros RA, Mihm MC, Jr. Clinicopathologic comparison of vulvar and extragenital lichen sclerosus: histologic variants, evolving lesions, and etiology of 141 cases. *Mod Pathol*. Sep 1998;11(9):844-54.
210. Keith PJ, Wolz MM, Peters MS. Eosinophils in lichen sclerosus et atrophicus. *J Cutan Pathol*. Oct 2015;42(10):693-8. doi:10.1111/cup.12556
211. Virgili A, Borghi A, Cazzaniga S, et al. Gender differences in genital lichen sclerosus: data from a multicenter Italian study on 729 consecutive cases. *G Ital Dermatol Venereol*. Apr 2020;155(2):155-160. doi:10.23736/s0392-0488.17.05819-9
212. Polat G, Erni B, Navarini A, Kind A, Mueller SM. Three patients with chronic vulvar pruritus successfully treated with cold atmospheric pressure plasma. *J Dtsch Dermatol Ges*. Sep 2021;19(9):1346-1349. doi:10.1111/ddg.14541
213. Borghi A, Corazza M, Minghetti S, Toni G, Virgili A. Avocado and soybean extracts as active principles in the treatment of mild-to-moderate vulvar lichen sclerosus: results of efficacy and tolerability. *J Eur Acad Dermatol Venereol*. Jun 2015;29(6):1225-30. doi:10.1111/jdv.12617
214. Simonart T, Lahaye M, Simonart JM. Vulvar lichen sclerosus: effect of maintenance treatment with a moisturizer on the course of the disease. *Menopause*. Jan-Feb 2008;15(1):74-7. doi:10.1097/gme.0b013e3180616689
215. Virgili A, Minghetti S, Borghi A, Corazza M. Long-term maintenance therapy for vulvar lichen sclerosus: the results of a randomized study comparing topical vitamin E with an emollient. *Eur J Dermatol*. Apr 1 2013;23(2):189-94. doi:10.1684/ejd.2013.1987
216. Connor CJ, Eppsteiner EE. Vulvar contact dermatitis. *Proceedings in Obstetrics and Gynecology*. 2014/10// 2014;4(2)
217. Schlosser BJ. Contact dermatitis of the vulva. *Dermatol Clin*. Oct 2010;28(4):697-706. doi:10.1016/j.det.2010.08.006
218. O'Gorman SM, Torgerson RR. Allergic contact dermatitis of the vulva. *Dermatitis*. Mar-Apr 2013;24(2):64-72. doi:10.1097/DER.0b013e318284da33
219. Virgili A, Borghi A, Toni G, Minghetti S, Corazza M. First randomized trial on clobetasol propionate and mometasone furoate in the treatment of vulvar lichen sclerosus: results of efficacy and tolerability. *Br J Dermatol*. Aug 2014;171(2):388-96. doi:10.1111/bjd.12910
220. Chi CC, Kirtschig G, Baldo M, Brackenbury F, Lewis F, Wojnarowska F. Topical interventions for genital lichen sclerosus. Meta-Analysis
- Review. *Cochrane database of systematic reviews*. 2011;(12):CD008240. doi:10.1002/14651858.CD008240.pub2
221. Dalziel KL, Millard PR, Wojnarowska F. The treatment of vulval lichen sclerosus with a very potent topical steroid (clobetasol propionate 0.05%) cream. *Br J Dermatol*. May 1991;124(5):461-4.
222. Lewis FM, Tatnall FM, Velangi SS, et al. British Association of Dermatologists guidelines for the management of lichen sclerosus, 2018. *Br J Dermatol*. Apr 2018;178(4):839-853. doi:10.1111/bjd.16241
223. Kirtschig G, Becker K, Günthert A, et al. Evidence-based (S3) Guideline on (anogenital) Lichen sclerosus. *J Eur Acad Dermatol Venereol*. Oct 2015;29(10):e1-43. doi:10.1111/jdv.13136
224. Singh N, Mishra N, Ghatage P. Treatment options in vulvar lichen sclerosus: a scoping review. *Cureus*. Feb 24 2021;13(2):e13527. doi:10.7759/cureus.13527

225. Virgili A, Borghi A, Minghetti S, Corazza M. Mometasone furoate 0.1% ointment in the treatment of vulvar lichen sclerosus: a study of efficacy and safety on a large cohort of patients. *J Eur Acad Dermatol Venereol*. Jul 2014;28(7):943-8. doi:10.1111/jdv.12219
226. LeFevre C, Hoffstetter S, Meyer S, Gavard J. Management of lichen sclerosus with triamcinolone ointment: effectiveness in reduction of patient symptom scores. *J Low Genit Tract Dis*. Jul 2011;15(3):205-9. doi:10.1097/LGT.0b013e31820a3b6f
227. López-Olmos J. Comparación de clobetasol frente a prednicartrato para el tratamiento del prurito vulvar con o sin distrofia. *Clínica e Investigación en Ginecología y Obstetricia*. 2003;30(4):104-117.
228. Casey GA, Cooper SM, Powell JJ. Treatment of vulvar lichen sclerosus with topical corticosteroids in children: a study of 72 children. *Clin Exp Dermatol*. Apr 2015;40(3):289-92. doi:10.1111/ced.12519
229. Fischer G, Rogers M. Treatment of childhood vulvar lichen sclerosus with potent topical corticosteroid. *Pediatr Dermatol*. May-Jun 1997;14(3):235-8. doi:10.1111/j.1525-1470.1997.tb00247.x
230. Powell J, Wojnarowska F. Childhood vulvar lichen sclerosus. The course after puberty. *J Reprod Med*. Sep 2002;47(9):706-9.
231. Kiss A, Csontai A, Pirót L, Nyirády P, Merksz M, Király L. The response of balanitis xerotica obliterans to local steroid application compared with placebo in children. *J Urol*. Jan 2001;165(1):219-20. doi:10.1097/00005392-200101000-00062
232. Vincent MV, Mackinnon E. The response of clinical balanitis xerotica obliterans to the application of topical steroid-based creams. *J Pediatr Surg*. Apr 2005;40(4):709-12. doi:10.1016/j.jpedsurg.2004.12.001
233. Dahlman-Ghozlan K, Hedblad MA, von Krogh G. Penile lichen sclerosus et atrophicus treated with clobetasol dipropionate 0.05% cream: a retrospective clinical and histopathological study. *J Am Acad Dermatol*. Mar 1999;40(3):451-7. doi:10.1016/s0190-9622(99)70496-2
234. Dalziel KL, Wojnarowska F. Long-term control of vulval lichen sclerosus after treatment with a potent topical steroid cream. *J Reprod Med*. Jan 1993;38(1):25-7.
235. Corazza M, Virgili A, Toni G, Borghi A. Mometasone furoate in the treatment of vulvar lichen sclerosus: could its formulation influence efficacy, tolerability and adherence to treatment? *J Dermatolog Treat*. May 2018;29(3):305-309. doi:10.1080/09546634.2017.1360990
236. Stücker M, Grape J, Bechara FG, Hoffmann K, Altmeyer P. The outcome after cryosurgery and intralesional steroid injection in vulvar lichen sclerosus corresponds to preoperative histopathological findings. *Dermatology*. 2005;210(3):218-22. doi:10.1159/000083513
237. Baggish MS, Ventolini G. Lichen sclerosus: Subdermal steroid injection therapy. A large, long-term follow-up study. *Journal of Gynecologic Surgery*. 2006;22(4):137-141.
238. Ventolini G, Swenson KM, Galloway ML. Lichen sclerosus: a 5-year follow-up after topical, subdermal, or combined therapy. *J Low Genit Tract Dis*. Jul 2012;16(3):271-4. doi:10.1097/LGT.0b013e31823da7e8
239. Luesley DM, Downey GP. Topical tacrolimus in the management of lichen sclerosus. *Bjog*. Jul 2006;113(7):832-4. doi:10.1111/j.1471-0528.2006.00977.x
240. Nissi R, Eriksen H, Risteli J, Niemimaa M. Pimecrolimus cream 1% in the treatment of lichen sclerosus. *Gynecol Obstet Invest*. 2007;63(3):151-4. doi:10.1159/000096736
241. Fistarol SK, Itin PH. Diagnosis and treatment of lichen sclerosus: an update. *Am J Clin Dermatol*. Feb 2013;14(1):27-47. doi:10.1007/s40257-012-0006-4
242. Guenther L, Lynde C, Poulin Y. Off-Label Use of Topical Calcineurin Inhibitors in Dermatologic Disorders. *J Cutan Med Surg*. Sep/Oct 2019;23(4\_suppl):27s-34s. doi:10.1177/1203475419857668
243. Wong E, Kurian A. Off-Label Uses of Topical Calcineurin Inhibitors. *Skin Therapy Lett*. Jan 2016;21(1):8-10.
244. Hengge UR, Krause W, Hofmann H, et al. Multicentre, phase II trial on the safety and efficacy of topical tacrolimus ointment for the treatment of lichen sclerosus. *Br J Dermatol*. Nov 2006;155(5):1021-8. doi:10.1111/j.1365-2133.2006.07446.x



245. Funaro D, Lovett A, Leroux N, Powell J. A double-blind, randomized prospective study evaluating topical clobetasol propionate 0.05% versus topical tacrolimus 0.1% in patients with vulvar lichen sclerosus. *J Am Acad Dermatol*. Jul 2014;71(1):84-91. doi:10.1016/j.jaad.2014.02.019
246. Mazzilli S, Diluvio L, Di Prete M, et al. Tacrolimus 0.03% ointment for treatment of paediatric lichen sclerosus: a case series and literature review. *J Int Med Res*. Sep 2018;46(9):3724-3728. doi:10.1177/0300060518778219
247. Virgili A, Lauriola MM, Mantovani L, Corazza M. Vulvar lichen sclerosus: 11 women treated with tacrolimus 0.1% ointment. *Acta Derm Venereol*. 2007;87(1):69-72. doi:10.2340/00015555-0171
248. Sotiriou E, Apalla Z, Patsatsi A, Panagiotidou D. Topical tacrolimus for recalcitrant vulvar lichen sclerosus. *Eur J Dermatol*. Sep-Oct 2009;19(5):515-6. doi:10.1684/ejd.2009.0733
249. Arican O, Ciralik H, Sasmaz S. Unsuccessful treatment of extragenital lichen sclerosus with topical 1% pimecrolimus cream. *J Dermatol*. Dec 2004;31(12):1014-7. doi:10.1111/j.1346-8138.2004.tb00646.x
250. Kim GW, Park HJ, Kim HS, et al. Topical tacrolimus ointment for the treatment of lichen sclerosus, comparing genital and extragenital involvement. *J Dermatol*. Feb 2012;39(2):145-50. doi:10.1111/j.1346-8138.2011.01384.x
251. Krueger GG, Eichenfield L, Goodman JJ, et al. Pharmacokinetics of tacrolimus following topical application of tacrolimus ointment in adult and pediatric patients with moderate to severe atopic dermatitis. *J Drugs Dermatol*. Feb 2007;6(2):185-93.
252. Hanna S, Zip C, Shear NH. What Is the Risk of Harm Associated With Topical Calcineurin Inhibitors? *J Cutan Med Surg*. Sep/Oct 2019;23(4\_suppl):19s-26s. doi:10.1177/1203475419857688
253. Devasenapathy N, Chu A, Wong M, et al. Cancer risk with topical calcineurin inhibitors, pimecrolimus and tacrolimus, for atopic dermatitis: a systematic review and meta-analysis. *Lancet Child Adolesc Health*. Jan 2023;7(1):13-25. doi:10.1016/s2352-4642(22)00283-8
254. Goldstein AT, Creasey A, Pfau R, Phillips D, Burrows LJ. A double-blind, randomized controlled trial of clobetasol versus pimecrolimus in patients with vulvar lichen sclerosus. *J Am Acad Dermatol*. Jun 2011;64(6):e99-104. doi:10.1016/j.jaad.2010.06.011
255. Burrows LJ, Creasey A, Goldstein AT. The treatment of vulvar lichen sclerosus and female sexual dysfunction. *J Sex Med*. Jan 2011;8(1):219-22. doi:10.1111/j.1743-6109.2010.02077.x
256. Nissi R, Kotila V, Knuuti E, Väre PO, Kauppila S. Altered p53 and Bcl-2 expression in keratinocytes of vulvar lichen sclerosus during pimecrolimus treatment. *Br J Dermatol*. Oct 2009;161(4):958-60. doi:10.1111/j.1365-2133.2009.09388.x
257. Oskay T, Sezer HK, Genç C, Kutluay L. Pimecrolimus 1% cream in the treatment of vulvar lichen sclerosus in postmenopausal women. *Int J Dermatol*. May 2007;46(5):527-32. doi:10.1111/j.1365-4632.2006.03185.x
258. Nissi R. P53 EXPRESSION IS DOWN-REGULATED IN LICHEN SCLEROSUS DURING PIMECROLIMUS (ELIDEL®) TREATMENT. *Maturitas*. 2009;(63):S112-S113.
259. Kyriakou A, Patsialas C, Patsatsi A, Sotiriadis D. Treatment of male genital lichen sclerosus with clobetasol propionate and maintenance with either methylprednisolone aceponate or tacrolimus: a retrospective study. *J Dermatolog Treat*. Dec 2013;24(6):431-4. doi:10.3109/09546634.2013.782385
260. Böhm M, Frieling U, Luger TA, Bonsmann G. Successful treatment of anogenital lichen sclerosus with topical tacrolimus. *Arch Dermatol*. Jul 2003;139(7):922-4. doi:10.1001/archderm.139.7.922
261. Matsumoto Y, Yamamoto T, Isobe T, Kusunoki T, Tsuboi R. Successful treatment of vulvar lichen sclerosus in a child with low-concentration topical tacrolimus ointment. *J Dermatol*. Feb 2007;34(2):114-6. doi:10.1111/j.1346-8138.2006.00228.x
262. Li Y, Xiao Y, Wang H, Li H, Luo X. Low-concentration topical tacrolimus for the treatment of anogenital lichen sclerosus in childhood: maintenance treatment to reduce recurrence. *J Pediatr Adolesc Gynecol*. Aug 2013;26(4):239-42. doi:10.1016/j.jpag.2012.11.010

263. Ebert AK, Rösch WH, Vogt T. Safety and tolerability of adjuvant topical tacrolimus treatment in boys with lichen sclerosus: a prospective phase 2 study. *Eur Urol*. Oct 2008;54(4):932-7. doi:10.1016/j.eururo.2008.03.013
264. Valdivielso-Ramos M, Bueno C, Hernanz JM. Significant improvement in extensive lichen sclerosus with tacrolimus ointment and PUVA. *Am J Clin Dermatol*. 2008;9(3):175-9. doi:10.2165/00128071-200809030-00006
265. Anderson K, Ascanio NM, Kinney MA, Krowchuk DP, Jorizzo JL. A retrospective analysis of pediatric patients with lichen sclerosus treated with a standard protocol of class I topical corticosteroid and topical calcineurin inhibitor. *J Dermatolog Treat*. 2016;27(1):64-6. doi:10.3109/09546634.2015.1054777
266. Feito-Rodríguez M, Noguera-Morel L, Casas-Rivero J, García-Rodríguez J, de Lucas-Laguna R. Bacterial vaginosis in the context of lichen sclerosus in a prepubertal girl. *Pediatr Dermatol*. Jan-Feb 2014;31(1):95-8. doi:10.1111/pde.12227
267. Davidovici BB, Tüzün Y, Wolf R. Retinoid receptors. *Dermatol Clin*. Oct 2007;25(4):525-30, viii. doi:10.1016/j.det.2007.06.016
268. Berger J, Telser A, Widschwendter M, et al. Expression of retinoic acid receptors in non-neoplastic epithelial disorders of the vulva and normal vulvar skin. *Int J Gynecol Pathol*. Apr 2000;19(2):95-102. doi:10.1097/00004347-200004000-00001
269. Virgili A, Corazza M, Bianchi A, Mollica G, Califano A. Open study of topical 0.025% tretinoin in the treatment of vulvar lichen sclerosus. One year of therapy. *J Reprod Med*. Sep 1995;40(9):614-8.
270. Filosa G, Bugatti L, Ciattaglia G. Vulvar lichen sclerosus associated with HCV-related chronic liver disease successfully treated with topical retinoic acid. *CHRONICA DERMATOLOGICA*. 1997;7:65-70.
271. Markowska J, Wiese E. Dystrophy of the vulva locally treated with 13-cis retinoic acid. *Neoplasma*. 1992;39(2):133-5.
272. Borghi A, Corazza M, Minghetti S, Virgili A. Topical tretinoin in the treatment of vulvar lichen sclerosus: an advisable option? *Eur J Dermatol*. Sep-Oct 2015;25(5):404-9. doi:10.1684/ejd.2015.2595
273. Borghi A, Minghetti S, Toni G, Virgili A, Corazza M. Combined therapy in vulvar lichen sclerosus: does topical tretinoin improve the efficacy of mometasone furoate? *J Dermatolog Treat*. Sep 2017;28(6):559-563. doi:10.1080/09546634.2016.1277178
274. Kaya G, Saurat JH. Restored epidermal CD44 expression in lichen sclerosus et atrophicus and clinical improvement with topical application of retinaldehyde. *British Journal of Dermatology*. 2005;152(3):570-572.
275. Harms M, Masgrau-Peya E, Lübke J. Treatment of vulval lichen sclerosus with topical mometasone furoate and retinaldehyde. A double blind study. Abstracts of the 9th Congress of the European Academy of Dermatology and Venereology. *J Eur Acad Dermatol Venereol*. 2000;14(Suppl. 1):225-6.
276. Friedrich EG, Jr., Kalra PS. Serum levels of sex hormones in vulvar lichen sclerosus, and the effect of topical testosterone. *N Engl J Med*. Feb 23 1984;310(8):488-91. doi:10.1056/nejm198402233100803
277. Bracco GL, Carli P, Sonni L, et al. Clinical and histologic effects of topical treatments of vulval lichen sclerosus. A critical evaluation. *J Reprod Med*. Jan 1993;38(1):37-40.
278. Kohlberger PD, Joura EA, Bancher D, Gitsch G, Breitenecker G, Kieback DG. Evidence of androgen receptor expression in lichen sclerosus: an immunohistochemical study. *J Soc Gynecol Investig*. Nov-Dec 1998;5(6):331-3. doi:10.1016/s1071-5576(98)00033-1
279. Clifton MM, Garner IB, Kohler S, Smoller BR. Immunohistochemical evaluation of androgen receptors in genital and extragenital lichen sclerosus: evidence for loss of androgen receptors in lesional epidermis. *J Am Acad Dermatol*. Jul 1999;41(1):43-6. doi:10.1016/s0190-9622(99)70404-4
280. Taylor AH, Guzail M, Al-Azzawi F. Differential expression of oestrogen receptor isoforms and androgen receptor in the normal vulva and vagina compared with vulval lichen sclerosus and chronic vaginitis. *Br J Dermatol*. Feb 2008;158(2):319-28. doi:10.1111/j.1365-2133.2007.08371.x
281. Kanda N, Watanabe S. Regulatory roles of sex hormones in cutaneous biology and immunology. *J Dermatol Sci*. Apr 2005;38(1):1-7. doi:10.1016/j.jdermsci.2004.10.011

282. Michalás S, Papandrikos A, Koutselini E, Tzingounis V. Local therapy of atrophic vaginal conditions with oestriol suppositories. *J Int Med Res.* 1980;8(5):358-60. doi:10.1177/030006058000800512
283. Singh P, Han HC. Labial adhesions in postmenopausal women: presentation and management. *Int Urogynecol J.* Sep 2019;30(9):1429-1432. doi:10.1007/s00192-018-3821-1
284. Kreklau A, Vâz I, Oehme F, et al. Measurements of a 'normal vulva' in women aged 15-84: a cross-sectional prospective single-centre study. *Bjog.* Dec 2018;125(13):1656-1661. doi:10.1111/1471-0528.15387
285. Hodgins MB, Spike RC, Mackie RM, MacLean AB. An immunohistochemical study of androgen, oestrogen and progesterone receptors in the vulva and vagina. *Br J Obstet Gynaecol.* Feb 1998;105(2):216-22. doi:10.1111/j.1471-0528.1998.tb10056.x
286. Sideri M, Origoni M, Spinaci L, Ferrari A. Topical testosterone in the treatment of vulvar lichen sclerosus. *Int J Gynaecol Obstet.* Jul 1994;46(1):53-6. doi:10.1016/0020-7292(94)90309-3
287. Paslin D. Treatment of lichen sclerosus with topical dihydrotestosterone. *Obstet Gynecol.* Dec 1991;78(6):1046-9.
288. Paslin D. Androgens in the topical treatment of lichen sclerosus. *Int J Dermatol.* Apr 1996;35(4):298-301. doi:10.1111/j.1365-4362.1996.tb03009.x
289. Cattaneo A, Carli P, De Marco A, et al. Testosterone maintenance therapy. Effects on vulvar lichen sclerosus treated with clobetasol propionate. *J Reprod Med.* Feb 1996;41(2):99-102.
290. Cattaneo A, De Marco A, Sonni L, Bracco GL, Carli P, Taddei GL. [Clobetasol vs. testosterone in the treatment of lichen sclerosus of the vulvar region]. *Minerva Ginecol.* Nov 1992;44(11):567-71. Clobetasolo vs testosterone nel trattamento del lichen scleroso della regione vulvare.
291. Jasionowski EA, Jasionowski P. Topical progesterone in treatment of vulvar dystrophy: preliminary report of five cases. *Am J Obstet Gynecol.* Mar 15 1977;127(6):667-70. doi:10.1016/0002-9378(77)90371-4
292. Jasionowski EA, Jasionowski PA. Further observations on the effect of topical progesterone on vulvar disease. *Am J Obstet Gynecol.* Jul 1 1979;134(5):565-7. doi:10.1016/0002-9378(79)90842-1
293. Leone M, Gerbaldo D, Caldana A, Leone M, Capitanio G. Progesterone topically administered influences epidermal growth factor immunoreactivity in vulvar tissue from patients with lichen sclerosus. *The Cervix.* 1993;11:25-7.
294. Parks G, Growdon WA, Mason GD, Goldman L, Lebherz TB. Childhood anogenital lichen sclerosus. A case report. *J Reprod Med.* Feb 1990;35(2):191-3.
295. Günthert AR, Limacher A, Beltraminelli H, et al. Efficacy of topical progesterone versus topical clobetasol propionate in patients with vulvar Lichen sclerosus - A double-blind randomized phase II pilot study. *Eur J Obstet Gynecol Reprod Biol.* May 2022;272:88-95. doi:10.1016/j.ejogrb.2022.03.020
296. Gupta S, Paliczak A, Delgado D. Evidence-based indications of platelet-rich plasma therapy. *Expert Rev Hematol.* Jan 2021;14(1):97-108. doi:10.1080/17474086.2021.1860002
297. Everts P, Onishi K, Jayaram P, Lana JF, Mautner K. Platelet-Rich Plasma: New Performance Understandings and Therapeutic Considerations in 2020. *Int J Mol Sci.* Oct 21 2020;21(20)doi:10.3390/ijms21207794
298. Maisel-Campbell AL, Ismail A, Reynolds KA, et al. A systematic review of the safety and effectiveness of platelet-rich plasma (PRP) for skin aging. *Arch Dermatol Res.* Jul 2020;312(5):301-315. doi:10.1007/s00403-019-01999-6
299. Wu PI, Diaz R, Borg-Stein J. Platelet-Rich Plasma. *Phys Med Rehabil Clin N Am.* Nov 2016;27(4):825-853. doi:10.1016/j.pmr.2016.06.002
300. Collins T, Alexander D, Barkatali B. Platelet-rich plasma: a narrative review. *EFORT Open Rev.* Apr 2021;6(4):225-235. doi:10.1302/2058-5241.6.200017
301. Marx RE. Platelet-Rich Plasma (PRP): What Is PRP and What Is Not PRP? *Implant Dentistry.* 2001;10(4):225-228.
302. Dhurat R, Sukesh M. Principles and Methods of Preparation of Platelet-Rich Plasma: A Review and Author's Perspective. *J Cutan Aesthet Surg.* Oct-Dec 2014;7(4):189-97. doi:10.4103/0974-2077.150734

303. Dohan Ehrenfest DM, Andia I, Zumstein MA, Zhang CQ, Pinto NR, Bielecki T. Classification of platelet concentrates (Platelet-Rich Plasma-PRP, Platelet-Rich Fibrin-PRF) for topical and infiltrative use in orthopedic and sports medicine: current consensus, clinical implications and perspectives. *Muscles Ligaments Tendons J*. Jan 2014;4(1):3-9.
304. Goldstein AT, Mitchell L, Govind V, Heller D. A randomized double-blind placebo-controlled trial of autologous platelet-rich plasma intradermal injections for the treatment of vulvar lichen sclerosus. *J Am Acad Dermatol*. Jun 2019;80(6):1788-1789. doi:10.1016/j.jaad.2018.12.060
305. Goldstein AT, King M, Runels C, Gloth M, Pfau R. Intradermal injection of autologous platelet-rich plasma for the treatment of vulvar lichen sclerosus. *J Am Acad Dermatol*. Jan 2017;76(1):158-160. doi:10.1016/j.jaad.2016.07.037
306. Behnia-Willison F, Pour NR, Mohamadi B, et al. Use of Platelet-rich Plasma for Vulvovaginal Autoimmune Conditions Like Lichen Sclerosus. *Plast Reconstr Surg Glob Open*. Nov 2016;4(11):e1124. doi:10.1097/gox.0000000000001124
307. Casabona F, Gambelli I, Casabona F, Santi P, Santori G, Baldelli I. Autologous platelet-rich plasma (PRP) in chronic penile lichen sclerosus: the impact on tissue repair and patient quality of life. *Int Urol Nephrol*. Apr 2017;49(4):573-580. doi:10.1007/s11255-017-1523-0
308. Tedesco M, Pranteda G, Chichierchia G, et al. The use of PRP (platelet-rich plasma) in patients affected by genital lichen sclerosus: clinical analysis and results. *J Eur Acad Dermatol Venereol*. Feb 2019;33(2):e58-e59. doi:10.1111/jdv.15190
309. Tedesco M, Garelli V, Bellei B, et al. Platelet-rich plasma for genital lichen sclerosus: analysis and results of 94 patients. Are there gender-related differences in symptoms and therapeutic response to PRP? *J Dermatolog Treat*. May 2022;33(3):1558-1562. doi:10.1080/09546634.2020.1854650
310. Tedesco M, Bellei B, Garelli V, et al. Adipose tissue stromal vascular fraction and adipose tissue stromal vascular fraction plus platelet-rich plasma grafting: New regenerative perspectives in genital lichen sclerosus. *Dermatol Ther*. Nov 2020;33(6):e14277. doi:10.1111/dth.14277
311. DeLong JM, Russell RP, Mazzocca AD. Platelet-rich plasma: the PAW classification system. *Arthroscopy*. Jul 2012;28(7):998-1009. doi:10.1016/j.arthro.2012.04.148
312. Abstracts. *Journal of Lower Genital Tract Disease*. 2019;23(4S):S37-S81. doi:10.1097/lgt.0000000000000491
313. Casabona F, Priano V, Vallerino V, Cogliandro A, Lavagnino G. New surgical approach to lichen sclerosus of the vulva: the role of adipose-derived mesenchymal cells and platelet-rich plasma in tissue regeneration. *Plast Reconstr Surg*. Oct 2010;126(4):210e-211e. doi:10.1097/PRS.0b013e3181ea9386
314. Prasad S, Coias J, Chen HW, Jacobe H. Utilizing UVA-1 Phototherapy. *Dermatol Clin*. Jan 2020;38(1):79-90. doi:10.1016/j.det.2019.08.011
315. Gambichler T, Schmitz L. Ultraviolet A1 Phototherapy for Fibrosing Conditions. *Front Med (Lausanne)*. 2018;5:237. doi:10.3389/fmed.2018.00237
316. Teske NM, Jacobe HT. Phototherapy for sclerosing skin conditions. *Clin Dermatol*. Sep-Oct 2016;34(5):614-22. doi:10.1016/j.clindermatol.2016.05.012
317. Kreuter A, Gambichler T. UV-A1 phototherapy for sclerotic skin diseases: implications for optimizing patient selection and management. *Arch Dermatol*. Jul 2008;144(7):912-6. doi:10.1001/archderm.144.7.912
318. Knobler R, Moinzadeh P, Hunzelmann N, et al. European Dermatology Forum S1-guideline on the diagnosis and treatment of sclerosing diseases of the skin, Part 1: localized scleroderma, systemic sclerosis and overlap syndromes. *J Eur Acad Dermatol Venereol*. Sep 2017;31(9):1401-1424. doi:10.1111/jdv.14458
319. Reichrath J, Reinhold U, Tilgen W. Treatment of genito-anal lesions in inflammatory skin diseases with PUVA cream photochemotherapy: an open pilot study in 12 patients. *Dermatology*. 2002;205(3):245-8. doi:10.1159/000065858
320. Beattie PE, Dawe RS, Ferguson J, Ibbotson SH. UVA1 phototherapy for genital lichen sclerosus. *Clin Exp Dermatol*. May 2006;31(3):343-7. doi:10.1111/j.1365-2230.2006.02082.x



321. Terras S, Gambichler T, Moritz RK, Stücker M, Kreuter A. UV-A1 phototherapy vs clobetasol propionate, 0.05%, in the treatment of vulvar lichen sclerosus: a randomized clinical trial. *JAMA Dermatol.* Jun 2014;150(6):621-7. doi:10.1001/jamadermatol.2013.7733
322. Colbert RL, Chiang MP, Carlin CS, Fleming M. Progressive extragenital lichen sclerosus successfully treated with narrowband UV-B phototherapy. *Arch Dermatol.* Jan 2007;143(1):19-20. doi:10.1001/archderm.143.1.19
323. Kreuter A, von Kobyletzki G, Happe M, et al. [Ultraviolet-A1 (UVA1) phototherapy in lichen sclerosus et atrophicus]. *Hautarzt.* Oct 2001;52(10):878-81. UVA1-Phototherapie bei Lichen sclerosus et atrophicus. doi:10.1007/s001050170051
324. Breuckmann F, Gambichler T, Altmeyer P, Kreuter A. UVA/UVA1 phototherapy and PUVA photochemotherapy in connective tissue diseases and related disorders: a research based review. *BMC Dermatol.* Sep 20 2004;4(1):11. doi:10.1186/1471-5945-4-11
325. Kreuter A, Gambichler T, Avermaete A, et al. Low-dose ultraviolet A1 phototherapy for extragenital lichen sclerosus: results of a preliminary study. *J Am Acad Dermatol.* Feb 2002;46(2):251-5. doi:10.1067/mjd.2002.118552
326. von Kobyletzki G, Freitag M, Hoffmann K, Altmeyer P, Kerscher M. [Balneophotochemotherapy with 8-methoxypsoralen in lichen sclerosis et atrophicus]. *Hautarzt.* Jul 1997;48(7):488-91. Balneophotochemotherapie mit 8-Methoxypsoralen bei Lichen sclerosus et atrophicus. doi:10.1007/s001050050615
327. Kreuter A, Gambichler T. Narrowband UV-B phototherapy for extragenital lichen sclerosus. *Arch Dermatol.* Sep 2007;143(9):1213. doi:10.1001/archderm.143.9.1213-a
328. Kreuter A, Hyun J, Stücker M, Sommer A, Altmeyer P, Gambichler T. A randomized controlled study of low-dose UVA1, medium-dose UVA1, and narrowband UVB phototherapy in the treatment of localized scleroderma. *J Am Acad Dermatol.* Mar 2006;54(3):440-7. doi:10.1016/j.jaad.2005.11.1063
329. Mann DJ, Vergilis-Kalner IJ, Wasserman JR, Petronic-Rosic V. Folliculocentric lichen sclerosus et atrophicus. *Skinmed.* Jul-Aug 2010;8(4):242-4.
330. Gerkowicz A, Szczepanik-Kuřak P, Krasowska D. Photodynamic Therapy in the Treatment of Vulvar Lichen Sclerosus: A Systematic Review of the Literature. *J Clin Med.* Nov 23 2021;10(23)doi:10.3390/jcm10235491
331. Olejek A, Gabriel I, Bilska-Janosiak A, Kozak-Darmas I, Kawczyk-Krupka A. ALA-Photodynamic treatment in Lichen sclerosus-clinical and immunological outcome focusing on the assesment of antinuclear antibodies. *Photodiagnosis Photodyn Ther.* Jun 2017;18:128-132. doi:10.1016/j.pdpdt.2017.02.006
332. Li Z, Wang Y, Wang J, et al. Evaluation of the efficacy of 5-aminolevulinic acid photodynamic therapy for the treatment of vulvar lichen sclerosus. *Photodiagnosis Photodyn Ther.* Mar 2020;29:101596. doi:10.1016/j.pdpdt.2019.101596
333. Sotiriou E, Panagiotidou D, Ioannidis D. An open trial of 5-aminolevulinic acid photodynamic therapy for vulvar lichen sclerosus. *Eur J Obstet Gynecol Reprod Biol.* Dec 2008;141(2):187-8. doi:10.1016/j.ejogrb.2008.07.027
334. Lan T, Zou Y, Hamblin MR, Yin R. 5-Aminolevulinic acid photodynamic therapy in refractory vulvar lichen sclerosus et atrophicus: Series of ten cases. *Photodiagnosis Photodyn Ther.* Mar 2018;21:234-238. doi:10.1016/j.pdpdt.2017.12.003
335. Windahl T. Is carbon dioxide laser treatment of lichen sclerosus effective in the long run? *Scand J Urol Nephrol.* 2006;40(3):208-11. doi:10.1080/00365590600589666
336. Kartamaa M, Reitamo S. Treatment of lichen sclerosus with carbon dioxide laser vaporization. *Br J Dermatol.* Mar 1997;136(3):356-9.
337. Pagano T, Conforti A, Buonfantino C, et al. Effect of rescue fractional microablative CO2 laser on symptoms and sexual dysfunction in women affected by vulvar lichen sclerosus resistant to long-term use of topic corticosteroid: a prospective longitudinal study. *Menopause.* Apr 2020;27(4):418-422. doi:10.1097/gme.0000000000001482

338. Gardner AN, Aschkenazi SO. The short-term efficacy and safety of fractional CO2 laser therapy for vulvovaginal symptoms in menopause, breast cancer, and lichen sclerosus. *Menopause*. Jan 4 2021;28(5):511-516. doi:10.1097/gme.0000000000001727
339. Balchander D, Nyirjesy P. Fractionated CO2 Laser as Therapy in Recalcitrant Lichen Sclerosus. *J Low Genit Tract Dis*. Apr 2020;24(2):225-228. doi:10.1097/lgt.0000000000000512
340. Burkett LS, Siddique M, Zeymo A, et al. Clobetasol Compared With Fractionated Carbon Dioxide Laser for Lichen Sclerosus: A Randomized Controlled Trial. *Obstet Gynecol*. Jun 1 2021;137(6):968-978. doi:10.1097/aog.0000000000004332
341. Bizjak Ogrinc U, Senčar S, Luzar B, Lukanović A. Efficacy of Non-ablative Laser Therapy for Lichen Sclerosus: A Randomized Controlled Trial. *J Obstet Gynaecol Can*. Dec 2019;41(12):1717-1725. doi:10.1016/j.jogc.2019.01.023
342. Gómez-Friero M, Laynez-Herrero E. Use of Er:YAG laser in the treatment of vulvar lichen sclerosus. *Int J Womens Dermatol*. Dec 2019;5(5):340-344. doi:10.1016/j.ijwd.2019.05.007
343. Zouboulis CC. [Cryosurgery in dermatology]. *Hautarzt*. Nov 2015;66(11):834-48. Kryochirurgie in der Dermatologie. doi:10.1007/s00105-015-3703-0
344. Clebak KT, Mendez-Miller M, Croad J. Cutaneous Cryosurgery for Common Skin Conditions. *Am Fam Physician*. Apr 1 2020;101(7):399-406.
345. Kastner U, Altmeyer P. [Cryosurgery--the last resort or a surgical alternative in the treatment of lichen sclerosus et atrophicus of the vulva (LSAV)?]. *J Dtsch Dermatol Ges*. Mar 2003;1(3):206-11. Kryochirurgie--ultima ratio oder chirurgische Alternative beim vulvären Lichen sclerosus et atrophicus (LSAV)? doi:10.1046/j.1610-0387.2003.03517.x
346. Mørk NJ, Jensen P, Hoel PS. Vulval lichen sclerosus et atrophicus treated with etretinate (Tigason). *Acta Derm Venereol*. 1986;66(4):363-5.
347. Romppanen U, Tuimala R, Ellmén J, Lauslahti K. [Oral treatment of vulvar dystrophy with an aromatic retinoid, etretinate]. *Geburtshilfe Frauenheilkd*. Apr 1986;46(4):242-7. Orale Behandlung der Dystrophie der Vulva mit einem aromatischen Retinoid, Etretinat. doi:10.1055/s-2008-1035907
348. Bousema MT, Romppanen U, Geiger JM, et al. Acitretin in the treatment of severe lichen sclerosus et atrophicus of the vulva: a double-blind, placebo-controlled study. *J Am Acad Dermatol*. Feb 1994;30(2 Pt 1):225-31. doi:10.1016/s0190-9622(94)70021-4
349. Ioannides D, Lazaridou E, Apalla Z, Sotiriou E, Gregoriou S, Rigopoulos D. Acitretin for severe lichen sclerosus of male genitalia: a randomized, placebo controlled study. *J Urol*. Apr 2010;183(4):1395-9. doi:10.1016/j.juro.2009.12.057
350. Cuellar-Barboza A, Bashyam AM, Ghamrawi RI, Aickara D, Feldman SR, Pichardo RO. Methotrexate for the treatment of recalcitrant genital and extragenital lichen sclerosus: A retrospective series. *Dermatol Ther*. Jul 2020;33(4):e13473. doi:10.1111/dth.13473
351. Kreuter A, Tigges C, Gaifullina R, Kirschke J, Altmeyer P, Gambichler T. Pulsed high-dose corticosteroids combined with low-dose methotrexate treatment in patients with refractory generalized extragenital lichen sclerosus. *Arch Dermatol*. Nov 2009;145(11):1303-8. doi:10.1001/archdermatol.2009.235
352. Nayeemuddin F, Yates VM. Lichen sclerosus et atrophicus responding to methotrexate. *Clin Exp Dermatol*. Aug 2008;33(5):651-2. doi:10.1111/j.1365-2230.2008.02721.x
353. Bhat T, Coughlin CC. Mood changes with methotrexate therapy for dermatologic disease. *Pediatr Dermatol*. Mar 2018;35(2):253-254. doi:10.1111/pde.13406
354. Buxton P, Priestley G. Para-aminobenzoate in lichen sclerosus et atrophicus. *Journal of Dermatological Treatment*. 1990;1(5):255-256.
355. Peterson DM, Damsky WE, Vesely MD. Treatment of lichen sclerosus and hypertrophic scars with dupilumab. *JAAD Case Rep*. May 2022;23:76-78. doi:10.1016/j.jdc.2022.03.002
356. Ye Q, Chen KJ, Jia M, Deng LJ, Fang S. Generalized lichen sclerosus et atrophicus combined with ankylosing spondylitis responding to secukinumab. *Scand J Rheumatol*. Sep 20 2022:1-2. doi:10.1080/03009742.2022.2112835

357. Lowenstein EB, Zeichner JA. Intralesional adalimumab for the treatment of refractory balanitis xerotica obliterans. *JAMA Dermatol.* Jan 2013;149(1):23-4. doi:10.1001/2013.jamadermatol.39
358. Feig JL, Gribetz ME, Lebwohl MG. Chronic lichen sclerosus successfully treated with intralesional adalimumab. *Br J Dermatol.* Mar 2016;174(3):687-9. doi:10.1111/bjd.14212
359. Seivright JR, Villa NM, De DR, Hsiao JL, Shi VY. Intralesional biologics for inflammatory dermatoses: A systematic review. *Dermatol Ther.* Feb 2022;35(2):e15234. doi:10.1111/dth.15234
360. Günthert AR, Duclos K, Jahns BG, et al. Clinical scoring system for vulvar lichen sclerosus. *J Sex Med.* Sep 2012;9(9):2342-50. doi:10.1111/j.1743-6109.2012.02814.x
361. Sheinis M, Selk A. Development of the Adult Vulvar Lichen Sclerosus Severity Scale-A Delphi Consensus Exercise for Item Generation. *J Low Genit Tract Dis.* Jan 2018;22(1):66-73. doi:10.1097/igt.0000000000000361
362. Morrel B, van Eersel R, Burger CW, et al. The long-term clinical consequences of juvenile vulvar lichen sclerosus: A systematic review. *J Am Acad Dermatol.* Feb 2020;82(2):469-477. doi:10.1016/j.jaad.2019.08.030
363. Hodges KR, Wiener CE, Vyas AS, Turrentine MA. The Female Genital Self-image Scale in Adult Women With Vulvar Lichen Sclerosus. *J Low Genit Tract Dis.* Jul 2019;23(3):210-213. doi:10.1097/igt.0000000000000481
364. Brauer M, van Lunsen R, Burger M, Laan E. Motives for Vulvar Surgery of Women with Lichen Sclerosus. *J Sex Med.* Dec 2015;12(12):2462-73. doi:10.1111/jsm.13052
365. Lauber F, Vaz I, Krebs J, Günthert AR. Outcome of perineoplasty and de-adhesion in patients with vulvar Lichen sclerosus and sexual disorders. *Eur J Obstet Gynecol Reprod Biol.* Mar 2021;258:38-42. doi:10.1016/j.ejogrb.2020.12.030
366. Rangatchew F, Knudsen J, Thomsen MV, Drzewiecki KT. Surgical treatment of disabling conditions caused by anogenital lichen sclerosus in women: An account of surgical procedures and results, including patient satisfaction, benefits, and improvements in health-related quality of life. *J Plast Reconstr Aesthet Surg.* Apr 2017;70(4):501-508. doi:10.1016/j.bjps.2016.12.008
367. Milian-Ciesielska K, Chmura L, Dyduch G, Jagers C, Radwanska E, Adamek D. Intraepidermal nerve fiber density in vulvar lichen sclerosus and normal vulvar tissues. *J Physiol Pharmacol.* Jun 2017;68(3):453-458.
368. Christmann-Schmid C, Hediger M, Gröger S, Krebs J, Günthert AR. Vulvar lichen sclerosus in women is associated with lower urinary tract symptoms. *Int Urogynecol J.* Feb 2018;29(2):217-221. doi:10.1007/s00192-017-3358-8
369. Rouzier R, Haddad B, Deyrolle C, Pelisse M, Moyal-Barracco M, Paniel BJ. Perineoplasty for the treatment of introital stenosis related to vulvar lichen sclerosus. *Am J Obstet Gynecol.* Jan 2002;186(1):49-52. doi:10.1067/mob.2002.119186
370. Goldstein A. Perineoplasty and vaginal advancement flap for vulvar granuloma fissuratum. *J Sex Med.* Nov 2011;8(11):2984-7. doi:10.1111/j.1743-6109.2011.02528.x
371. Gurumurthy M, Morah N, Gioffre G, Cruickshank ME. The surgical management of complications of vulval lichen sclerosus. *Eur J Obstet Gynecol Reprod Biol.* May 2012;162(1):79-82. doi:10.1016/j.ejogrb.2012.01.016
372. Flynn AN, King M, Rieff M, Krapf J, Goldstein AT. Patient Satisfaction of Surgical Treatment of Clitoral Phimosis and Labial Adhesions Caused by Lichen Sclerosus. *Sex Med.* Dec 2015;3(4):251-5. doi:10.1002/sm2.90
373. Burger MP, Obdeijn MC. Complications after surgery for the relief of dyspareunia in women with lichen sclerosus: a case series. *Acta Obstet Gynecol Scand.* Apr 2016;95(4):467-72. doi:10.1111/aogs.12852
374. Brauer M, van Lunsen RH, Laan ET, Burger MP. A Qualitative Study on Experiences After Vulvar Surgery in Women With Lichen Sclerosus and Sexual Pain. *J Sex Med.* Jul 2016;13(7):1080-90. doi:10.1016/j.jsxm.2016.04.072
375. Bradford J, Fischer G. Surgical division of labial adhesions in vulvar lichen sclerosus and lichen planus. *J Low Genit Tract Dis.* Jan 2013;17(1):48-50. doi:10.1097/LGT.0b013e31824f1427
376. Frappell J, Rider L, Riadin L, Ebeid E, Asmussen T, Morris R. Double Opposing Zplasty with VY Advancement of the perineum: Long-term results of a new technique as an alternative to Fenton's operation

- for narrowing and splitting of the skin at the posterior vaginal fourchette. *Eur J Obstet Gynecol Reprod Biol.* Apr 2018;223:46-49. doi:10.1016/j.ejogrb.2018.02.003
377. Stewart L, McCammon K, Metro M, Virasoro R. SIU/ICUD Consultation on Urethral Strictures: Anterior urethra-lichen sclerosus. *Urology.* Mar 2014;83(3 Suppl):S27-30. doi:10.1016/j.urology.2013.09.013
378. Barbagli G, Lazzeri M, Palminteri E, Turini D. Lichen sclerosus of male genitalia involving anterior urethra. *Lancet.* Jul 31 1999;354(9176):429. doi:10.1016/s0140-6736(05)75851-7
379. Barbagli G, Palminteri E, Lazzeri M, Turini D. Lichen sclerosus of the male genitalia. *Contemporary Urology.* 2001;13(3):47-47.
380. Peterson AC, Palminteri E, Lazzeri M, Guanzoni G, Barbagli G, Webster GD. Heroic measures may not always be justified in extensive urethral stricture due to lichen sclerosus (balanitis xerotica obliterans). *Urology.* Sep 2004;64(3):565-8. doi:10.1016/j.urology.2004.04.035
381. Barbagli G, Palminteri E, Balò S, et al. Lichen sclerosus of the male genitalia and urethral stricture diseases. *Urol Int.* 2004;73(1):1-5. doi:10.1159/000078794
382. Kurtzman JT, Blum R, Brandes SB. One-Stage Buccal Mucosal Graft Urethroplasty for Lichen Sclerosus-Related Urethral Stricture Disease: A Systematic Review and Pooled Proportional Meta-Analysis. *J Urol.* Oct 2021;206(4):840-853. doi:10.1097/ju.0000000000001870
383. Chodisetti S, Boddepalli Y, Kota M. Repair of panurethral stricture: Proximal ventral and distal dorsal onlay technique of buccal mucosal graft urethroplasty. *Arab J Urol.* Jun 2018;16(2):211-216. doi:10.1016/j.aju.2017.11.007
384. Barbagli G, Palminteri E, Mirri F, Guazzoni G, Turini D, Lazzeri M. Penile carcinoma in patients with genital lichen sclerosus: a multicenter survey. *J Urol.* Apr 2006;175(4):1359-63. doi:10.1016/s0022-5347(05)00735-4
385. Barbagli G, Mirri F, Gallucci M, Sansalone S, Romano G, Lazzeri M. Histological evidence of urethral involvement in male patients with genital lichen sclerosus: a preliminary report. *J Urol.* Jun 2011;185(6):2171-6. doi:10.1016/j.juro.2011.02.060
386. Levine LA, Strom KH, Lux MM. Buccal mucosa graft urethroplasty for anterior urethral stricture repair: evaluation of the impact of stricture location and lichen sclerosus on surgical outcome. *J Urol.* Nov 2007;178(5):2011-5. doi:10.1016/j.juro.2007.07.034
387. Folaranmi SE, Corbett HJ, Losty PD. Does application of topical steroids for lichen sclerosus (balanitis xerotica obliterans) affect the rate of circumcision? A systematic review. *J Pediatr Surg.* Nov 2018;53(11):2225-2227. doi:10.1016/j.jpedsurg.2017.12.021
388. Snodgrass W, Blanquel JS, Bush NC. Recurrence after management of meatal balanitis xerotica obliterans. *J Pediatr Urol.* Apr 2017;13(2):204.e1-204.e6. doi:10.1016/j.jpuro.2016.10.014
389. Kiss A, Király L, Kutasy B, Merksz M. High incidence of balanitis xerotica obliterans in boys with phimosis: prospective 10-year study. *Pediatr Dermatol.* Jul-Aug 2005;22(4):305-8. doi:10.1111/j.1525-1470.2005.22404.x
390. Kumar KS, Morrel B, van Hees CLM, van der Toorn F, van Dorp W, Mendels EJ. Comparison of lichen sclerosus in boys and girls: A systematic literature review of epidemiology, symptoms, genetic background, risk factors, treatment, and prognosis. *Pediatr Dermatol.* May 2022;39(3):400-408. doi:10.1111/pde.14967
391. Homer L, Buchanan KJ, Nasr B, Losty PD, Corbett HJ. Meatal stenosis in boys following circumcision for lichen sclerosus (balanitis xerotica obliterans). *J Urol.* Dec 2014;192(6):1784-8. doi:10.1016/j.juro.2014.06.077
392. Wilkinson DJ, Lansdale N, Everitt LH, et al. Foreskin preputioplasty and intralesional triamcinolone: a valid alternative to circumcision for balanitis xerotica obliterans. *J Pediatr Surg.* Apr 2012;47(4):756-9. doi:10.1016/j.jpedsurg.2011.10.059
393. Lansdale N, Arthur F, Corbett HJ. Circumcision versus preputioplasty for balanitis xerotica obliterans: a randomised controlled feasibility trial. *BJU Int.* Dec 2021;128(6):759-765. doi:10.1111/bju.15508
394. Depasquale I, Park AJ, Bracka A. The treatment of balanitis xerotica obliterans. *BJU Int.* Sep 2000;86(4):459-65. doi:10.1046/j.1464-410x.2000.00772.x



395. Gargollo PC, Kozakewich HP, Bauer SB, et al. Balanitis xerotica obliterans in boys. *J Urol*. Oct 2005;174(4 Pt 1):1409-12. doi:10.1097/01.ju.0000173126.63094.b3
396. Mirastschijski U, Schwenke C, Melchior S, Cedidi C. „Buried Penis“: Aktuelle Übersicht über Ätiologie, Klassifikation und plastisch-chirurgische Rekonstruktion. *Handchirurgie· Mikrochirurgie· Plastische Chirurgie*. 2017;49(02):78-84.
397. Monn MF, Chua M, Aubé M, et al. Surgical management and outcomes of adult acquired buried penis with and without lichen sclerosus: a comparative analysis. *International Urology and Nephrology*. 2020;52:1893-1898.
398. Barbagli G, Perovic S, Djinovic R, Sansalone S, Lazzeri M. Retrospective descriptive analysis of 1,176 patients with failed hypospadias repair. *J Urol*. Jan 2010;183(1):207-11. doi:10.1016/j.juro.2009.08.153
399. Arena S, Russo T, Impellizzeri P, Parisi S, Perrone P, Romeo C. Utility of uroflowmetry during the follow-up of children affected by balanitis xerotica obliterans (BXO). *Arch Ital Urol Androl*. Jun 30 2018;90(2):123-126. doi:10.4081/aiua.2018.2.123
400. Kulkarni S, Barbagli G, Kirpekar D, Mirri F, Lazzeri M. Lichen sclerosus of the male genitalia and urethra: surgical options and results in a multicenter international experience with 215 patients. *Eur Urol*. Apr 2009;55(4):945-54. doi:10.1016/j.eururo.2008.07.046
401. Garaffa G, Shabbir M, Christopher N, Minhas S, Ralph DJ. The surgical management of lichen sclerosus of the glans penis: our experience and review of the literature. *J Sex Med*. Apr 2011;8(4):1246-53. doi:10.1111/j.1743-6109.2010.02165.x
402. Morey AF. Re: Glans resurfacing for the treatment of carcinoma in situ of the penis: surgical technique and outcomes. *J Urol*. Nov 2011;186(5):1954. doi:10.1016/j.juro.2011.07.135
403. Parkash S, Gajendran V. Meatoplasty for gross urethral stenosis: a technique of repair and a review of 32 cases. *Br J Plast Surg*. Jan 1984;37(1):117-20. doi:10.1016/0007-1226(84)90054-7
404. Malone P. A new technique for meatal stenosis in patients with lichen sclerosus. *J Urol*. Sep 2004;172(3):949-52. doi:10.1097/01.ju.0000134781.43470.5f
405. Bhatt J, Malone P. Long term results of new technique of meatoplasty for meatal stenosis. WILEY-BLACKWELL PUBLISHING, INC COMMERCE PLACE, 350 MAIN ST, MALDEN 02148 ...; 2010:40-40.
406. Treiyer A, Anheuser P, Reisch B, Steffens J. [Treatment of urethral meatus stenosis due to Balanitis xerotica obliterans. Long term results using the meatoplasty of Malone]. *Actas Urol Esp*. Sep 2011;35(8):494-8. Tratamiento de la estrechez del meato uretral por balanitis xerótica obliterante: resultados a largo plazo empleando meatoplastia de Malone. doi:10.1016/j.acuro.2011.03.002
407. Barbagli G, Sansalone S, Djinovic R, Romano G, Lazzeri M. Current controversies in reconstructive surgery of the anterior urethra: a clinical overview. *Int Braz J Urol*. May-Jun 2012;38(3):307-16; discussion 316. doi:10.1590/s1677-55382012000300003
408. Singh BP, Pathak HR, Andankar MG. Dorsolateral onlay urethroplasty for anterior urethral strictures by a unilateral urethral mobilization approach. *Indian J Urol*. Apr 2009;25(2):211-4. doi:10.4103/0970-1591.52919
409. Meeks JJ, Barbagli G, Mehdiratta N, Granieri MA, Gonzalez CM. Distal urethroplasty for isolated fossa navicularis and meatal strictures. *BJU Int*. Feb 2012;109(4):616-9. doi:10.1111/j.1464-410X.2011.10248.x
410. Venn SN, Mundy AR. Urethroplasty for balanitis xerotica obliterans. *Br J Urol*. May 1998;81(5):735-7. doi:10.1046/j.1464-410x.1998.00634.x
411. Das S, Tunuguntla HS. Balanitis xerotica obliterans--a review. *World J Urol*. Dec 2000;18(6):382-7. doi:10.1007/pl00007083
412. Martínez-Piñeiro L. Editorial comment on: Lichen sclerosus of the male genitalia and urethra: surgical options and results in a multicenter international experience with 215 patients. *Eur Urol*. Apr 2009;55(4):954; discussion 955-6. doi:10.1016/j.eururo.2008.07.047
413. Dubey D, Sehgal A, Srivastava A, Mandhani A, Kapoor R, Kumar A. Buccal mucosal urethroplasty for balanitis xerotica obliterans related urethral strictures: the outcome of 1 and 2-stage techniques. *J Urol*. Feb 2005;173(2):463-6. doi:10.1097/01.ju.0000149740.02408.19

414. Kulkarni S, Kulkarni J, Kirpekar D. A new technique of urethroplasty for balanitis xerotica obliterans. *J Urol*. 2000;163(Suppl):352.
415. Trivedi S, Kumar A, Goyal NK, Dwivedi US, Singh PB. Urethral reconstruction in balanitis xerotica obliterans. *Urol Int*. 2008;81(3):285-9. doi:10.1159/000151405
416. Barbagli G, Palminteri E, Guazzoni G, Cavalcanti A. Bulbar urethroplasty using the dorsal approach: current techniques. *Int Braz J Urol*. Mar-Apr 2003;29(2):155-61. doi:10.1590/s1677-55382003000200012
417. Sauder MB, Linzon-Smith J, Beecker J. Extragenital bullous lichen sclerosus. *J Am Acad Dermatol*. Nov 2014;71(5):981-4. doi:10.1016/j.jaad.2014.06.037
418. Uitto J, Santa Cruz DJ, Bauer EA, Eisen AZ. Morphea and lichen sclerosus et atrophicus. Clinical and histopathologic studies in patients with combined features. *J Am Acad Dermatol*. Sep 1980;3(3):271-9. doi:10.1016/s0190-9622(80)80190-3
419. Shiver M, Papasakelariou C, Brown JA, Wirges M, Kincannon J. Extragenital bullous lichen sclerosus in a pediatric patient: a case report and literature review. *Pediatr Dermatol*. May-Jun 2014;31(3):383-5. doi:10.1111/pde.12025
420. Shah CT, Mandell JW, Kirzhner M. Lichen sclerosus of the eyelid. *Cutis*. Sep 2020;106(3):E16-e17. doi:10.12788/cutis.0097
421. Kawakami Y, Oyama N, Hanami Y, Kimura T, Kishimoto K, Yamamoto T. A case of lichen sclerosus of the scalp associated with autoantibodies to extracellular matrix protein 1. *Arch Dermatol*. Dec 2009;145(12):1458-60. doi:10.1001/archdermatol.2009.313
422. Mercieca L, Collier NJ, Motta L, Singh M. A linear hypopigmented lesion on the forehead. *Clin Exp Dermatol*. Aug 2019;44(6):664-666. doi:10.1111/ced.13826
423. Uthayakumar AK, Kravvas G, Bunker CB. Extragenital lichen sclerosus arising in tattooed skin. *BMJ Case Rep*. Jan 6 2022;15(1)doi:10.1136/bcr-2021-246216
424. Glaser KS, Glaser EN, Piliang M, Anthony J. Extragenital lichen sclerosus et atrophicus within a skin graft scar. *JAAD Case Rep*. Oct 2018;4(9):938-940. doi:10.1016/j.jdc.2018.09.007
425. Trokoudes D, Lewis FM. Lichen sclerosus - the course during pregnancy and effect on delivery. *J Eur Acad Dermatol Venereol*. Dec 2019;33(12):e466-e468. doi:10.1111/jdv.15788
426. Dalziel KL. Effect of lichen sclerosus on sexual function and parturition. *J Reprod Med*. May 1995;40(5):351-4.
427. Nguyen Y, Bradford J, Fischer G. Lichen sclerosus in pregnancy: A review of 33 cases. *Aust N Z J Obstet Gynaecol*. Dec 2018;58(6):686-689. doi:10.1111/ajo.12812
428. Kolitz E, Gammon L, Mauskar M. Vulvar lichen sclerosus in women of reproductive age. *Proc (Bayl Univ Med Cent)*. Feb 22 2021;34(3):349-351. doi:10.1080/08998280.2021.1885093
429. Helm KF, Gibson LE, Muller SA. Lichen sclerosus et atrophicus in children and young adults. *Pediatr Dermatol*. Jun 1991;8(2):97-101. doi:10.1111/j.1525-1470.1991.tb00294.x
430. Haefner HK, Pearlman MD, Barclay ML, Selvaggi SM. Lichen sclerosus in pregnancy: presentation of two cases. *J Low Genit Tract Dis*. Oct 1999;3(4):260-3. doi:10.1046/j.1526-0976.1999.34008.x
431. Mahé A, Perret JL, Ly F, Fall F, Rault JP, Dumont A. The cosmetic use of skin-lightening products during pregnancy in Dakar, Senegal: a common and potentially hazardous practice. *Trans R Soc Trop Med Hyg*. Feb 2007;101(2):183-7. doi:10.1016/j.trstmh.2006.06.007
432. Chi CC, Wang SH, Wojnarowska F, Kirtschig G, Davies E, Bennett C. Safety of topical corticosteroids in pregnancy. *Cochrane database of systematic reviews*. Oct 26 2015;2015(10):Cd007346. doi:10.1002/14651858.CD007346.pub3
433. Beckmann MM, Stock OM. Antenatal perineal massage for reducing perineal trauma. *Cochrane database of systematic reviews*. Apr 30 2013;4):Cd005123. doi:10.1002/14651858.CD005123.pub3
434. Schaefer C, Peters PW, Miller RK. *Drugs during pregnancy and lactation: treatment options and risk assessment*. Academic Press; 2014.
435. Smith AB, Muhammad NI, Cigna ST, Krapf JM. A systematic review of sexual health consequences among women with lichen sclerosus. *Sexual Medicine Reviews*. 2023;

436. Bohm-Starke N, Hilliges M, Falconer C, Rylander E. Increased intraepithelial innervation in women with vulvar vestibulitis syndrome. *Gynecol Obstet Invest.* 1998;46(4):256-60. doi:10.1159/000010045
437. Bergeron S, Reed BD, Wesselmann U, Bohm-Starke N. Vulvodynia. *Nat Rev Dis Primers.* Apr 30 2020;6(1):36. doi:10.1038/s41572-020-0164-2
438. Kennedy CM, Nygaard IE, Bradley CS, Galask RP. Bladder and bowel symptoms among women with vulvar disease: are they universal? *J Reprod Med.* Dec 2007;52(12):1073-8.
439. Okui N, Okui M, Gambacciani M. Is Erbium/Neodymium Laser Combination Therapy an Effective Treatment Option for Interstitial Cystitis/Bladder Pain Syndrome With Vulvodynia? *Cureus.* Nov 2022;14(11):e31228. doi:10.7759/cureus.31228
440. Bornstein J, Goldstein AT, Stockdale CK, et al. 2015 ISSVD, ISSWSH and IPPS Consensus Terminology and Classification of Persistent Vulvar Pain and Vulvodynia. *Obstet Gynecol.* Apr 2016;127(4):745-751. doi:10.1097/aog.0000000000001359
441. Shah M. Sexual function is adversely affected in the majority of men presenting with penile lichen sclerosus. *Clin Exp Dermatol.* Jun 2021;46(4):723-726. doi:10.1111/ced.14637
442. Rozanski AT, Zhang LT, Muise AC, et al. Conservative Management of Lichen Sclerosus Male Urethral Strictures: A Multi-Institutional Experience. *Urology.* Jun 2021;152:123-128. doi:10.1016/j.urology.2021.01.010
443. Kherlopian A, Fischer G. Does compliance to topical corticosteroid therapy reduce the risk of development of permanent vulvar structural abnormalities in pediatric vulvar lichen sclerosus? A retrospective cohort study. *Pediatr Dermatol.* Jan 2022;39(1):22-30. doi:10.1111/pde.14840
444. Kammire MS, Anderson K, Howell JO, McShane DB, Corley SB, Morrell DS. Pediatric Vulvar Lichen Sclerosus: A Survey of Disease Course. *J Pediatr Adolesc Gynecol.* Oct 2021;34(5):597-602. doi:10.1016/j.jpog.2021.04.010
445. Ellis E, Fischer G. Prepubertal-Onset Vulvar Lichen Sclerosus: The Importance of Maintenance Therapy in Long-Term Outcomes. *Pediatr Dermatol.* Jul-Aug 2015;32(4):461-7. doi:10.1111/pde.12597
446. Tausch TJ, Peterson AC. Early aggressive treatment of lichen sclerosus may prevent disease progression. *J Urol.* Jun 2012;187(6):2101-5. doi:10.1016/j.juro.2012.01.071
447. Orszulak D, Dulaska A, Niziński K, et al. Pediatric Vulvar Lichen Sclerosus-A Review of the Literature. *Int J Environ Res Public Health.* Jul 4 2021;18(13)doi:10.3390/ijerph18137153
448. van Cranenburgh OD, Nijland SBW, Lindeboom R, et al. Patients with lichen sclerosus experience moderate satisfaction with treatment and impairment of quality of life: results of a cross-sectional study. *Br J Dermatol.* Jun 2017;176(6):1508-1515. doi:10.1111/bjd.15125
449. Van De Nieuwenhof HP, Meeuwis KA, Nieboer TE, Vergeer MC, Massuger LF, De Hullu JA. The effect of vulvar lichen sclerosus on quality of life and sexual functioning. *Journal of Psychosomatic Obstetrics & Gynecology.* 2010;31(4):279-284.
450. Vittrup G, Mørup L, Heilesen T, Jensen D, Westmark S, Melgaard D. Quality of life and sexuality in women with lichen sclerosus: a cross-sectional study. *Clinical and Experimental Dermatology.* 2022;47(2):343-350.
451. Poindexter G, Morrell DS. Anogenital pruritus: lichen sclerosus in children. *Pediatr Ann.* Dec 2007;36(12):785-91. doi:10.3928/0090-4481-20071201-07
452. Schlosser BJ, Mirowski GW. Lichen sclerosus and lichen planus in women and girls. *Clin Obstet Gynecol.* Mar 2015;58(1):125-42. doi:10.1097/grf.000000000000090
453. van der Avoort IA, Tiemes DE, van Rossum MM, van der Vleuten CJ, Massuger LF, de Hullu JA. Lichen sclerosus: treatment and follow-up at the departments of gynaecology and dermatology. *J Low Genit Tract Dis.* Apr 2010;14(2):118-23. doi:10.1097/LGT.0b013e3181c4bfe6
454. Yesudian PD, Sugunendran H, Bates CM, O'Mahony C. Lichen sclerosus. *Int J STD AIDS.* Jul 2005;16(7):465-73, test 474. doi:10.1258/0956462054308440
455. Ventegodt S. The holistic vulva clinic: An integrative approach to the treatment of genital, sexual and non-sexual pain and the other health problems related to the female gender.

456. Simpson RC, Cooper SM, Kirtschig G, et al. Future research priorities for lichen sclerosus - results of a James Lind Alliance Priority Setting Partnership. *Br J Dermatol*. May 2019;180(5):1236-1237. doi:10.1111/bjd.17447
457. Tran DA, Tan X, Macri CJ, Goldstein AT, Fu SW. Lichen Sclerosus: An autoimmunopathogenic and genomic enigma with emerging genetic and immune targets. *Int J Biol Sci*. 2019;15(7):1429-1439. doi:10.7150/ijbs.34613
458. Bocheńska K, Smolińska E, Moskot M, Jakóbkiewicz-Banecka J, Gabig-Cimińska M. Models in the Research Process of Psoriasis. *Int J Mol Sci*. Nov 24 2017;18(12)doi:10.3390/ijms18122514
459. Kim D, Kobayashi T, Nagao K. Research Techniques Made Simple: Mouse Models of Atopic Dermatitis. *J Invest Dermatol*. May 2019;139(5):984-990.e1. doi:10.1016/j.jid.2019.02.014
460. Chattopadhyay S, Arnold JD, Malayil L, et al. Potential role of the skin and gut microbiota in premenarchal vulvar lichen sclerosus: A pilot case-control study. *PLoS One*. 2021;16(1):e0245243. doi:10.1371/journal.pone.0245243
461. Kumar KS, Morrel B, van Hees CLM, van der Toorn F, van Dorp W, Mendels EJ. Comparison of lichen sclerosus in boys and girls: A systematic literature review of epidemiology, symptoms, genetic background, risk factors, treatment, and prognosis. *Pediatr Dermatol*. Mar 1 2022;doi:10.1111/pde.14967
462. Carlson BC, Hofer MD, Ballek N, Yang XJ, Meeks JJ, Gonzalez CM. Protein markers of malignant potential in penile and vulvar lichen sclerosus. *J Urol*. Aug 2013;190(2):399-406. doi:10.1016/j.juro.2013.01.102
463. Paolino G, Panetta C, Cota C, Muscardin L, Donati P, Di Carlo A. Lichen sclerosus and the risk of malignant progression: a case series of 159 patients. *G Ital Dermatol Venereol*. Dec 2013;148(6):673-8.
464. Potapov AL, Sirotkina MA, Matveev LA, et al. Multiphoton microscopy assessment of the structure and variability changes of dermal connective tissue in vulvar lichen sclerosus: A pilot study. *J Biophotonics*. Sep 2022;15(9):e202200036. doi:10.1002/jbio.202200036
465. Zucchi A, Cai T, Cavallini G, et al. Genital Lichen Sclerosus in Male Patients: A New Treatment with Polydeoxyribonucleotide. *Urol Int*. 2016;97(1):98-103. doi:10.1159/000443184
466. Villalpando BK, Wyles SP, Schaefer LA, Bodiford KJ, Bruce AJ. Platelet-rich plasma for the treatment of lichen sclerosus. *Plast Aesthet Res*. 2021;8doi:10.20517/2347-9264.2021.86
467. Tedesco M, Garelli V, Elia F, et al. Efficacy of injecting hybrid cooperative complexes of hyaluronic acid for the treatment of vulvar lichen sclerosus: A preliminary study. *J Cosmet Dermatol*. Mar 3 2022;doi:10.1111/jocd.14896
468. Bernhardt T, Semmler ML, Schäfer M, Bekeschus S, Emmert S, Boeckmann L. Plasma Medicine: Applications of Cold Atmospheric Pressure Plasma in Dermatology. *Oxid Med Cell Longev*. 2019;2019:3873928. doi:10.1155/2019/3873928
469. Simpson RC, Kirtschig G, Selk A, et al. Core outcome domains for lichen sclerosus: a CORALS initiative consensus statement. *Br J Dermatol*. Jan 26 2023;doi:10.1093/bjd/ljac145